

PITFALLS OF TELE-ECG CONSULTATION IN A RURAL SERVICE

Vivek Chauhan FACEE

Dr. Rajendra Prasad Govt. Medical College, Kangra at Tanda, Himachal Pradesh, India

Abstract

Rural hospitals in India are manned by MBBS doctors who are trained to provide primary care and to run and monitor the National Programs mainly. These doctors are now witnessing increasing numbers of acute coronary syndrome (ACS) patients at primary level. They are not competent enough to diagnose ACS on their own even by looking at ECG. In an Indian council of medical research funded project, we provided the rural doctors with Tele-ECG facility. During the course of this project, we came across some pitfalls of Tele-ECG in rural setup. One such case was diagnosed with ST-elevated myocardial infarction, while it turned out to be a perforated duodenal ulcer. We have reported the case and briefly discussed the expected pitfalls for Tele-ECG in a rural setup.

Keywords: Telemedicine; telehealth; telediagnosis, cardiology; tele-ecg.

Introduction

We have been running a Tele-ECG based project in a rural area of the Sub-Himalayan region of India since February 2015. The project is funded by the Indian Council of Medical Research and has two main components. First is the enablement of rural doctors, unable to decide on their own, if a patient presenting to them in emergency has an acute coronary syndrome (ACS) or not. For this we have provided rural doctors with a service comprised of two components. First a 12 lead ECG machine, which they did not have available earlier. Second, a tele-diagnosis capability in which the rural doctors are now sharing the ECG images of suspected ACS patients using their own smartphones and Internet-based applications. The medicine consultants immediately respond and call them back to discuss the diagnosis and management

possibilities based on the ECG picture. More than 70 cases of acute myocardial infarction (AMI) have been diagnosed and managed over the first 3 months, and have included timely referral to physician-based centres for thrombolysis.

Case Report

Recently we came across a peculiar case which tells us of the pitfalls of tele-ECG. A 65 year old male presented to one of the peripheral centres with a history of severe chest pain of one hour's duration. The pain was severe in intensity on right side of chest and radiating to the right shoulder. It was accompanied by perspiration, ghabrahat (chest apprehension) and shortness of breath. The doctor in the peripheral centre suspected ACS and the ECG showed ST-elevation in leads V1 to V3. The ECG was transmitted to us. (Figure 1)

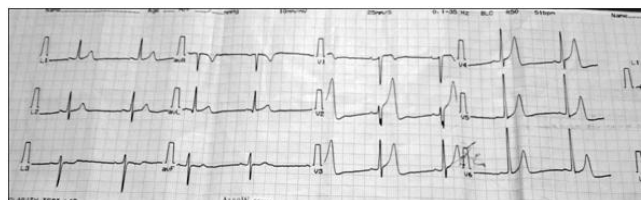


Figure 1. ECG showing ST-Elevation in Leads V1 to V4 with Tall T waves V2-V5.

We also suspected it to be ACS with likely ST-elevated anterior wall myocardial infarction. The peripheral centres do not have the facility to test for cardiac enzyme concentrations, so they are usually advised to give the loading dose of 300 mg of aspirin and 300 mg of clopidogrel, and 80 mg of atorvastatin to patients suspected of ACS, and to then refer them in an ambulance with oxygen support. The patient was referred similarly to our centre and reached us within an hour. The history was reviewed and the patient was

examined. The history was again suggestive of an ACS. The first ECG did not have ST-elevation of > 2 mm in two contiguous chest leads, so we withheld the decision to thrombolyse and ordered cardiac marker concentrations. His creatinine kinase (MB) concentration was 14 U/L which were much below the reference range for ACS, i.e., < 24 U/L. The repeat ECG, done in emergency at our Centre, did not show any progression of ST-elevation, but the chest pain was persistent. A routine chest x-ray, also done in emergency at our Centre, revealed something unexpected, i.e., gas under the diaphragm. (Figure 2)

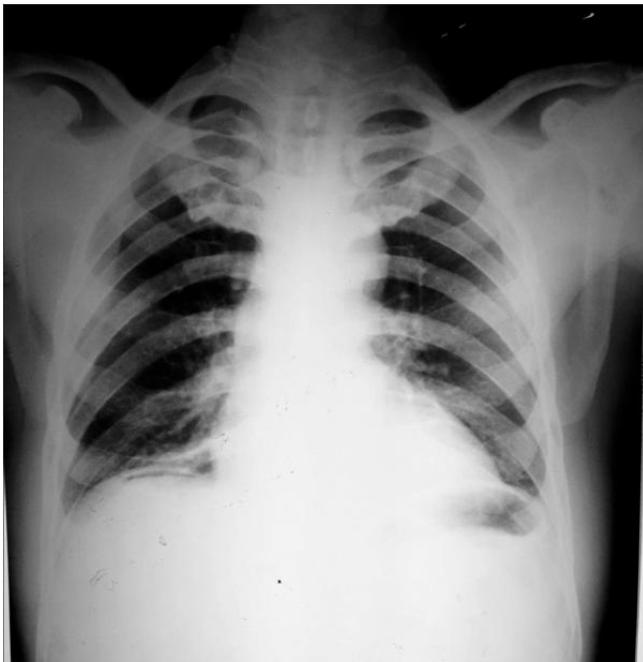

Figure 2. Chest x-ray PA view showing gas under right diaphragm.

We were surprised by this revelation. Surgeons immediately diagnosed the patient as having a possible ruptured duodenal ulcer (DU). The patient was taken for emergency surgery and a ruptured duodenal ulcer confirmed on surgery. The patient recovered well over next one week and was pain free. The ECG done after the surgery showed resolution of the ST-T wave changes found in earlier ECGs.

The first ECG in this case was suggestive of STEMI (ST segment elevation myocardial infarction) and the patient had a typical chest pain, but the en-

zyme levels were normal and it turned out to be perforated DU presenting as probable STEMI which was reported through tele-ECG.

Antiplatelets are contraindicated in perforated DU but since we accepted a diagnosis of ACS on tele-ECG, the patient was given loading doses of dual anti platelets, i.e., aspirin 300 mg and Clopidogrel 300 mg, which might have led to aggravation of the perforated DU.

It is well known that abdominal pathologies like cholecystitis, pancreatitis, and any acute abdomen can have ST-T wave changes. Similarly, central nervous system (CNS) pathologies - especially stroke - can have ST-T wave changes. So, while practising tele-ECG one must keep in mind the alternative possibilities and take steps to rule them out before starting the treatment for ACS.

In the absence of enzyme testing facilities in resource poor countries, simply saying that an ECG is suggestive of STEMI or non-STEMI is not enough and it may lead to a missed or wrong diagnosis.

We recommend that in such places, the peripheral doctors must rule out abdominal and CNS causes by looking for tenderness in the abdomen and for lateralizing neurological signs in all suspected ACS patients before putting them on anti-platelets, while consulting through Tele-ECG for ACS. Antiplatelets can be catastrophic in CNS bleeds and perforated ulcers.

.....
Corresponding author:

Dr Vivek Chauhan

Dr. Rajendra Prasad Govt. Medical College

Kangra at Tanda

Himachal Pradesh

India 176001

Email: drvivekshimla@yahoo.com

Tel: 9418341202