

## Original Article

# Influence of Implant Neck Design on Crestal Bone Loss: A Comparative Study

Yojana B. Patil<sup>1</sup>, Swati Joshi Asopa<sup>2</sup>, Deepa<sup>3</sup>, Aashana Goel<sup>4</sup>, Divya Jyoti<sup>5</sup>, Nagaveni S. Somayaji<sup>6</sup>, Robin Sabharwal<sup>7</sup>

<sup>1</sup>Department of Public Health Dentistry, Tatyasaheb Kore Dental College and Research Centre, Kolhapur, Maharashtra, India,

<sup>2</sup>Department of Prosthodontics, Rajasthan Dental College and Hospital, Jaipur, Rajasthan, India,

<sup>3</sup>Department of Oral and Maxillofacial Surgery, Sri Venkateshwara Dental College and Hospital, Bannerughatta, Anekal Road, Bengaluru, Karnataka, India,

<sup>4</sup>Department of Pedodontics and Preventive Dentistry, Adesh Institute of Research and Dental Sciences, Bathinda, Punjab, India,

<sup>5</sup>Department of Periodontology, Adesh Institute of Research and Dental Sciences, Bathinda, Punjab, India,

<sup>6</sup>Department of Prosthodontics, Crown and Bridge, Hi-Tech Dental College and Hospital, Bhubaneswar, Odisha, India,

<sup>7</sup>Department of Oral Pathology, Private Practitioner, Chandigarh, India

Received : 20-06-2019

Revision : 12-08-2019

Accepted : 16-09-2019

Published : 10-02-2020

### ABSTRACT

**Background:** The success rate of dental implants depends on the amount of crestal bone around the implants. Crestal module is the transosteal region of implant that is designed to receive the prosthetic component. The design of crestal module influences the crestal bone loss around implants. **Aim:** The purpose of this study was to evaluate and compare the crestal bone loss around implants with smooth collar and implants with micro threaded rough collar design.

**Materials and Methods:** A total of 150 individuals received 100 dental implants. Each individual received one implant with smooth collar design (Group-A) and one implant with microthreaded rough collar design (Group-B) in the posterior edentulous region. All the 100 implants were prosthetically loaded after a healing period of 3 months. Crestal bone loss was measured on mesial, distal, buccal, and lingual side of each implant using periapical radiographs before loading (baseline), immediately after loading, 6, and 12 months after loading. **Results:** The average crestal bone loss 12 months after loading the implants in Group A and Group B was 3.75 mm and 3.23 mm, respectively, the value being statistically significant ( $P < 0.05$ ). In both Group A and Group B, the average crestal bone loss was maximum on the lingual side followed by buccal, distal, and mesial sides.

**Conclusion:** Crestal bone loss around rough-surfaced microthreaded neck implants was significantly lower than smooth-surfaced neck implants.

**KEYWORDS:** Collar design, crestal bone loss, dental implants

## INTRODUCTION

Tooth loss can be caused by periodontal disease, abscess formation, trauma, or vertical tooth fracture. Common consequences of tooth loss include progressive resorption of the alveolar bone and decreased masticatory performance. Tooth replacement

with dental implants has led to an important revolution in modern clinical dentistry. Branemark first introduced

**Address for correspondence:** Dr Robin Sabharwal, Department of Oral Pathology, Private Practitioner, Chandigarh, India.  
E-mail: [robin.sabharwal@yahoo.co.in](mailto:robin.sabharwal@yahoo.co.in)

This is an open access journal, and articles are distributed under the terms of the Creative Commons Attribution-NonCommercial-ShareAlike 4.0 License, which allows others to remix, tweak, and build upon the work non-commercially, as long as appropriate credit is given and the new creations are licensed under the identical terms.

**For reprints contact:** [reprints@medknow.com](mailto:reprints@medknow.com)

**How to cite this article:** Patil YB, Asopa SJ, Deepa, Goel A, Jyoti D, Somayaji NS, et al. Influence of implant neck design on crestal bone loss: A comparative study. Niger J Surg 2020;26:22-7.

### Access this article online

#### Quick Response Code:



**Website:** [www.nigerianjsurg.com](http://www.nigerianjsurg.com)

**DOI:** 10.4103/njs.NJS\_28\_19

osseointegrated dental implants to allow firm anchorage of titanium implant screws into living bone, a process referred to as osseointegration.<sup>[1]</sup>

The long-term clinical success of dental implants depends mainly on the preservation of the bony support around the implant, which is usually evaluated with radiographic images.<sup>[2]</sup> Bone loss around the implant reduces its longevity. Bone loss begins from the crest/collar region of an osseointegrated implant and progresses apically. Possible causes of the crestal bone loss could be a local inflammation/infection and mechanical stresses acting on the crestal bone around the implant crest module/collar. Various dental implants with different surface designs are being used for dental rehabilitation of patients. Design of the implant crest module (or collar) can influence bone loss. Many of them are two-stage, submerged implants with a 2-mm smooth coronal collar/crest module design. Bone loss with smooth collar has been observed.<sup>[3-5]</sup>

Bone loss around both the collar design needs to be evaluated and compared as it has been observed that implants with smooth collar design show a greater bone loss as compared to rough collar design.<sup>[6,7]</sup>

Albrektsson *et al.*<sup>[8]</sup> proposed criteria for assessing and evaluating the success of implant survival; these criteria included marginal bone remodeling of <2.0 mm in the 1<sup>st</sup> year after implant placement and <0.2 mm each year thereafter. These changes are usually related to the use of implants with a conventional machined surface and a conventional neck design. Recently, several studies have shown that implants with a rough surface and a microthreaded-neck design may improve the preservation and stabilization of crestal bone.<sup>[9-12]</sup>

The purpose of this *in vivo* study was to evaluate and compare the crestal bone loss occurring around the implants with smooth coronal collar and implants with rough microthreaded collar design.

## MATERIALS AND METHODS

The research was a prospective clinical study conducted in BRS Dental College and Hospital, Haryana, from the year 2016 to 2018. The present study included 50 individuals in the age group of 25–60 years attending the outpatient Department and those requiring replacement of two missing teeth by implant-supported crowns in the posterior region of mandible. The inclusion criteria included patients who had good oral hygiene, nonsmokers or with smoking history of <3 cigarettes/day, with periodontal healthy teeth adjacent to implant site and without any periapical lesion. Patients with any local or systemic disease, smoking habit >3 cigarettes/day, betel nut or tobacco chewing, alcoholism, pregnancy or breastfeeding,

longterm oral medications, oral par function, nontreated periodontal disease, and with inadequate bone volume were excluded from the study.

Each patient received one implant with a 2-mm smooth polished crest module/collar design (Group-A implants, Nobel Biocare) and another implant with rough microthreaded crest module/collar design (Group-B implants, Alpha-Bio). Fullthickness mucoperiosteal flap was elevated by giving local anesthesia and a mid crestal incision in the edentulous area. Dental implants were placed and flaps were sutured. Patients received postoperative instructions and were advised to rinse with chlorhexidine 0.12% twice a day for 10 days, and sutures were removed 2 weeks after. All implants were inserted until the outer edge of the dental implant reached the marginal bone level, to allow for the apex of the cover screw to be at level with the bone crest during the healing period. Postoperatively, digital radiographs were taken using KaVo dental X-ray machine (Germany 2010) to measure the first crestal bone to implant contact level from the top of the implant along the collar/body surface of each implant on the mesial, distal, buccal, and lingual side. These measurements would become the baseline reference levels to measure future bone loss. After 3 months of implant insertion, a secondstage surgery was carried out, and the healing abutments were placed over the implants. Crestal bone levels were measured on the mesial, distal, buccal, and lingual side of each implant using periapical radiographs. Crestal bone loss was calculated by deducting the baseline reference bone levels from the present levels, which gave the value of bone loss, occurred after 3 months of placing the implants. Implant level impressions were taken 2 weeks postoperatively to the healing abutment surgery connection. The permanent metal-ceramic crown was delivered 2 weeks after impressions.

Digital periapical radiographs of the dental implants were recorded at different time points: before loading (baseline), immediately after loading, 6, and 12 months after loading.

Data were presented as means  $\pm$  standard error and were analyzed using the Statistical Package for Scientific Studies for Windows (SPSS 20, IBM, Armonk, NY, USA) at a statistical significance level of  $P \leq 0.05$ . Statistical analysis was carried out using “Paired *t*-test” to compare the bone loss along Group A and B types of implants.

## RESULTS

A total of 50 patients (25 men and 25 women) were included in the study group with an age range of 25–60 years. Majority of the patients that is 30 (60%) were

middle aged. No significant differences in demographic data were found between the groups ( $P > 0.05$ ).

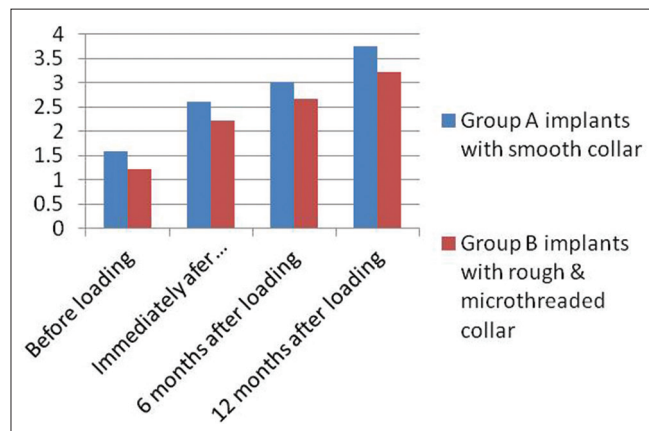
Tables 1 and 2 depict the mean values obtained for the crestal bone loss at specified time intervals around Group-A and Group-B implants. The average crestal bone loss around the perimeter of Group-A and Group-B implants before loading was 1.58 mm and 1.18 mm, immediately after loading was 2.61 mm and 2.23 mm, 6 months after loading was 3.01 mm and 2.68 mm and 12 months after loading was 3.75 mm and 3.23 mm, respectively [Figure 1]. After 12 months of loading the implants, there was a statistically significant difference in the crestal bone loss among Group-A and Group-B implants, the average bone loss being more around Group-A implants ( $P < 0.05$ ).

**Table 1: Bone loss (mean±standard deviation) around Group-A implants (smooth collar)**

Duration	Mesial	Distal	Buccal	Lingual
Baseline	1.49±0.32	1.50±0.33	1.66±0.34	1.67±0.33
Immediately after loading	2.4±0.33	2.6±0.38	2.71±0.37	2.72±0.36
6 months after loading	2.8±0.39	3.0±0.40	3.11±0.42	3.12±0.41
12 months after loading	3.51±0.41	3.71±0.43	3.89±0.45	3.90±0.44

**Table 2: Bone loss (mean±standard deviation) around Group-B implants (rough microthreaded collar)**

Duration	Mesial	Distal	Buccal	Lingual
Baseline	1.0±0.35	1.1±0.36	1.3±0.37	1.32±0.36
Immediately after loading	2.0±0.38	2.2±0.40	2.3±0.42	2.4±0.41
6 months after loading	2.4±0.42	2.7±0.43	2.80±0.45	2.81±0.44
12 months after loading	3.0±0.46	3.21±0.48	3.31±0.50	3.40±0.49



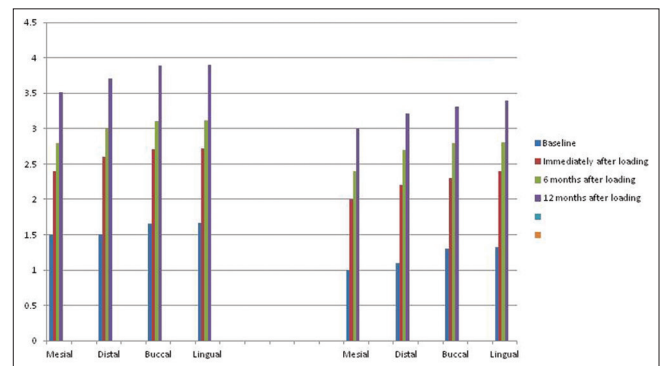
**Figure 1:** The average crestal bone loss around the perimeter of Group-A and Group-B implants

The mean crestal bone loss around Group-A implants before loading was (1.49 ± 0.32 mm on mesial side, 1.50 ± 0.33 mm on distal side, 1.66 ± 0.34 mm on the buccal side, and 1.67 ± 0.33 mm on the lingual side), immediately after loading (2.40 ± 0.3 mm on mesial side, 2.60 ± 0.35 mm on the distal side, 2.71 ± 0.37 mm on the buccal side, and 2.72 ± 0.36 mm on the lingual side), 6 months after loading (2.80 ± 0.39 mm on the mesial side, 3.0 ± 0.4 mm on the distal side, 3.11 ± 0.42 mm on the buccal side, and 3.12 ± 0.41 mm on the lingual side of dental implant), and 12 months after loading (3.51 ± 0.41 mm on the mesial side, 3.71 ± 0.43 mm on the distal side, 3.89 ± 0.42 mm on the buccal side, and 3.90 ± 0.44 on the lingual side of implants).

Statistical analysis showed a statistically significant difference ( $P < 0.05$ ) between the baseline and 6 months and between the baseline and 12 months in all the bone loss measurements around Group-A implants [Table 1 and Figure 2].

The mean crestal bone loss around Group-B implants before loading was (1.0 ± 0.35 mm on mesial side, 1.10 ± 0.36 mm on distal side, 1.30 ± 0.37 mm on the buccal side, and 1.32 ± 0.36 mm on the lingual side), immediately after loading (2.0 ± 0.38 mm on mesial side, 2.20 ± 0.40 mm on the distal side, 2.30 ± 0.42 mm on the buccal side and 2.40 ± 0.41 mm on the lingual side), 6 months after loading (2.40 ± 0.42 mm on the mesial side, 2.70 ± 0.43 mm on the distal side, 2.80 ± 0.45 mm on the buccal side and 2.81 ± 0.44 mm on the lingual side of dental implants), and 12 months after loading (3.0 ± 0.46 mm on the buccal side, 3.21 ± 0.48 mm on the distal side, 3.31 ± 0.50 mm on the buccal side, and 3.40 ± 0.49 on the lingual side of implants).

Statistical analysis showed a statistically significant difference ( $P < 0.05$ ) between the baseline and 6 months



**Figure 2:** Graphical comparison of mean crestal bone loss around Group-A and Group-B implants on mesial, distal, buccal, and lingual surfaces

and between the baseline and 12 months in all the bone loss measurements around Group-B implants [Table 2 and Figure 2].

## DISCUSSION

The success rate of dental implant mainly depends on its design and has long been established through various studies. Crest module is the transosteal portion of a two-piece metal dental implant that creates a transition zone to the load-bearing implant body and is designed to hold the prosthetic components in place.<sup>[13]</sup>

Collar is usually designed to minimize plaque accumulation; hence, many implants have a polished smooth collar of varying lengths. The tissue height above the implant is on an average 2.5 mm and usually, the toothbrush bristles cannot enter a sulcus more than 1 mm. Thus, on the contrary, this smooth collar may contribute to bone loss. Crestal bone is weakest against shear forces and strongest against compressive forces. A smooth parallel collar results in shear forces in the crestal bone region. Resulting bone loss may be due to the lack of mechanical stimulation in the crest region. An angled crest module of  $>20^\circ$  with a surface texture that increases bone contact might result in compressive and tensile components, thus reducing crestal bone loss. The modified rough collar design with microthreads results in decreased crestal bone loss.<sup>[12,14]</sup>

There is insufficient literature available to support the hypothesis that a rough-collared microthreaded implant results in lesser crestal bone loss as compared to an implant with smooth collar. This *in vivo* study was undertaken to compare the crestal bone loss occurring along the implants with smooth collar surface and with rough collar microthreaded design.

In this study, Group-A implants (Nobel Biocare) were machined, two stages, tapered implants. The 2-mm crest module/collar was smooth, machine polished. Group-B implants (Alpha-Bio) were also two stage, microthreaded implants with entire implant body and collar treated with Sandblast Large grit Acid etch (SLA). SLA implant surface is created through two processes: a sandblasting process for a macro surface of 20–40  $\mu$  and a double thermal acid-etching process to create micropitting between 1  $\mu$  and 5  $\mu$ . Acid-etching results in osteoblasts growth on SLA surfaces that further enhance the osseointegration by increasing cell adhesion and bone formation. These osteoblasts are highly differentiated bone cells, suggesting that this pitted surface enhances bone cell-implant integration.<sup>[15,16]</sup>

Both types of implants were placed in the same jaw of the subjects in similar regions, i.e., mandibular posterior

region, and hence that, their bone beds have similar bone qualities and they receive similar occlusal forces during function.

From the results, it can be observed that crestal bone loss around Groups A and B implants before loading was 1.58 mm and 1.18 mm, respectively, immediately after loading was 2.61 mm and 2.23 mm, respectively. The difference in bone loss with both types of implants at this stage was statistically not significant. Surgical trauma and lack of positive stimulation due to occlusal forces may have caused this observed bone loss and these observations are commensurate with other studies.<sup>[17]</sup>

In the present study, it was observed that 6 months after loading the overall average crestal bone loss around Group A and B implants was 3.01 mm and 2.68 mm, respectively. This difference in the bone loss was found to be statistically nonsignificant, though the average difference was 0.33.

After 12 months of loading the implants, there was a statistically significant difference in crestal bone loss among Group A and B implants 3.75 mm and 3.23 mm, respectively, the average bone loss being more around Group A implants ( $P < 0.05$ ). It could be because Group-A implants resulted in disuse atrophy of the adjacent alveolar bone due to their smooth and parallel collar design that failed to produce positive stimulation of the adjacent alveolar bone, apart from transmitting shear stresses to the crestal bone.<sup>[13]</sup>

On the other hand, Group B implants had a rough, parallel collar which could have converted part of the shear force component into compressive and tensile components due to its surface roughness and micropores. The adjacent crestal bone osseointegrates into the micropores, elevations, and depressions of the rough collar area. Micromovements of implant occurring under occlusal forces during function may further dissipate the forces into the adjacent osseointegrated crestal bone. These micromovements result in positive stimulation of the crestal bone and hence cause lesser bone loss around rough collar microthreaded implants.

Group-B implants with rough microthreaded collar showed lesser average crestal bone loss as compared to that of Group-A implants with the smooth collar. These results were in accordance with the studies conducted by Hånggi *et al.*<sup>[6]</sup> and Pilliar *et al.*<sup>[7]</sup>

Bratu *et al.*<sup>[18]</sup> compared the marginal bone loss in dental implants with SLA treatment, coronal microthreads, and polished neck design. The results showed statistically significant lower marginal bone loss in combined SLA/microthread implants.

The study conducted by Peñarrocha-Diago *et al.*<sup>[19]</sup> showed a greater bone loss in implants with a machined surface neck design without microthreads in the 1<sup>st</sup> year. Piao *et al.*<sup>[20,21]</sup> in a long-term study concluded that the implants with rough surface and microthreads at the coronal portion maintained the marginal bone level against functional loading better than implants without these two features after a follow-up of 1 year and further confirmed these results after a 3-year follow-up.

In addition, Shin *et al.*<sup>[22]</sup> have shown in their work that a rough surface and microthreads at the implant neck not only reduce crestal bone loss but also help with early biomechanical adaptation against loading in comparison to the machined neck design. They concluded that a rough surface with microthreads at the implant neck is the most effective design in maintaining the marginal bone level against functional loading.

Hermann *et al.*<sup>[23]</sup> conducted a study to examine crestal bone changes around machined versus SLA surfaced implant collars and later concluded that SLA-surfaced nonsubmerged implant can reduce the amount of peri-implant crestal bone loss compared to implants with a machined collar.

The 10-year retrospective study by Sánchez-Siles *et al.*<sup>[24]</sup> evaluated a total of 1244 implants with and without smooth neck and concluded that 2.5-mm smooth-necked implants suffered less bone loss and peri-implantitis at any follow-up time interval.

Limitations to this study include the evaluation of soft-tissue health during the entire period of follow-up. Good oral hygiene is an essential requirement for the successful osseointegration of dental implants and the maintenance of prosthesis. Further studies with a larger sample size and with longer follow-up are recommended to substantiate the data presented in this study.

Thus, implant collar design is an important criterion for the better success rate of dental implants.

## CONCLUSION

The results of the present study revealed that the implant collar design influences the crestal bone loss around the implants. The marginal bone loss around the rough-surfaced microthreaded neck implants was significantly lower than smooth-surfaced neck implants as the micro-movements of the rough-surfaced microthreaded implants dissipate the forces into the adjacent osseointegrated crestal bone, thus stimulating the crestal bone and reducing bone loss around rough-surfaced microthreaded implants. However,

considering the limitations of the current study, the results should be interpreted cautiously. Thus, this concept must be taken into consideration before selecting

## Financial support and sponsorship

Nil.

## Conflicts of interest

There are no conflicts of interest.

## REFERENCES

1. Pye AD, Lockhart DE, Dawson MP, Murray CA, Smith AJ. A review of dental implants and infection. *J Hosp Infect* 2009;72:104-10.
2. Verhoeven JW, Cune MS, de Putter C. Reliability of some clinical parameters of evaluation in implant dentistry. *J Oral Rehabil* 2000;27:211-6.
3. Jovanovic SA. Diagnosis and treatment of peri implant complications. In: Newman MG, Takei HH, Carranza FA. *Carranza's Clinical Periodontology*. 9<sup>th</sup> ed. Philadelphia: WB Saunders; 2003. p. 931-42.
4. Vaillancourt H, Pilliar RM, McCammond D. Factors affecting crestal bone loss with dental implants partially covered with a porous coating: A finite element analysis. *Int J Oral Maxillofac Implants* 1996;11:351-9.
5. Wiskott HW, Belser UC. Lack of integration of smooth titanium surfaces: A working hypothesis based on strains generated in the surrounding bone. *Clin Oral Implants Res* 1999;10:429-44.
6. Hänggi MP, Hänggi DC, Schoolfield JD, Meyer J, Cochran DL, Hermann JS, *et al.* Crestal bone changes around titanium implants. Part I: A retrospective radiographic evaluation in humans comparing two non-submerged implant designs with different machined collar lengths. *J Periodontol* 2005;76:791-802.
7. Pilliar RM, Deporter DA, Watson PA, Valiquette N. Dental implant design effect on bone remodeling. *J Biomed Mater Res* 1991;25:467-83.
8. Albrektsson T, Zarb G, Worthington P, Eriksson AR. The long-term efficacy of currently used dental implants: A review and proposed criteria of success. *Int J Oral Maxillofac Implants* 1986;1:11-25.
9. Rocci A, Martignoni M, Gottlow J. Immediate loading of brånemark system tiUnite and machined-surface implants in the posterior mandible: A randomized open-ended clinical trial. *Clin Implant Dent Relat Res* 2003;5 Suppl 1:57-63.
10. Friberg B, Jemt T. Rehabilitation of edentulous mandibles by means of five tiUnite implants after one-stage surgery: A 1-year retrospective study of 90 patients. *Clin Implant Dent Relat Res* 2008;10:47-54.
11. Al-Thobity AM, Kutkut A, Almas K. Microthreaded implants and crestal bone loss: A systematic review. *J Oral Implantol* 2017;43:157-66.
12. Goswami MM. Comparison of crestal bone loss along two implant crest module designs. *Med J Armed Forces India* 2009;65:319-22.
13. Aparna IN, Dhanasekar B, Lingeshwar D, Gupta L. Implant crest module: A review of biomechanical considerations. *Indian J Dent Res* 2012;23:257-63.
14. Misch CE, Bidez MW. A scientific rationale for dental implant design. In: Misch CE, editor. *Contemporary Implant Dentistry*. 2<sup>nd</sup> ed. St. Louis: Mosby; 1999. p. 329-43.

15. Jemat A, Ghazali MJ, Razali M, Otsuka Y. Surface modifications and their effects on titanium dental implants. *Biomed Res Int* 2015;2015:791725.
16. Kieswetter K, Schwartz Z, Hummert TW, Cochran DL, Simpson J, Dean DD, *et al.* Surface roughness modulates the local production of growth factors and cytokines by osteoblast-like MG-63 cells. *J Biomed Mater Res* 1996;32:55-63.
17. Singh P, Garge HG, Parmar VS, Viswambaran M, Goswami MM. Evaluation of implant stability and crestal bone loss around the implant prior to prosthetic loading: A six month study. *J Indian Prosthodont Soc* 2006;6:33-7.
18. Bratu EA, Tandlich M, Shapira L. A rough surface implant neck with microthreads reduces the amount of marginal bone loss: A prospective clinical study. *Clin Oral Implants Res* 2009;20:827-32.
19. Peñarrocha-Diago MA, Flichy-Fernández AJ, Alonso-González R, Peñarrocha-Oltra D, Balaguer-Martínez J, Peñarrocha-Diago M. Influence of implant neck design and implant-abutment connection type on peri-implant health. Radiological study. *Clin Oral Implants Res* 2013;24:1192-200.
20. Piao CM, Lee JE, Koak JY, Kim SK, Rhyu IC, Han CH, *et al.* Marginal bone loss around three different implant systems: Radiographic evaluation after 1 year. *J Oral Rehabil* 2009;36:748-54.
21. Lee SY, Piao CM, Koak JY, Kim SK, Kim YS, Ku Y, *et al.* A 3-year prospective radiographic evaluation of marginal bone level around different implant systems. *J Orthop Res* 2010;37:538-44.
22. Shin YK, Han CH, Heo SJ, Kim S, Chun HJ. Radiographic evaluation of marginal bone level around implants with different neck designs after 1 year. *Int J Oral Maxillofac Implants* 2006;21:789-94.
23. Hermann JS, Jones AA, Bakaeen LG, Buser D, Schoolfield JD, Cochran DL. Influence of a machined collar on crestal bone changes around titanium implants: A histometric study in the canine mandible. *J Periodontol* 2011;82:1329-38.
24. Sánchez-Siles M, Muñoz-Cámara D, Salazar-Sánchez N, Ballester-Ferrandis JF, Camacho-Alonso F. Incidence of peri-implantitis and oral quality of life in patients rehabilitated with implants with different neck designs: A 10-year retrospective study. *J Craniomaxillofac Surg* 2015;43:2168-74.