

Original Article

Endoscopic Management of Ureteric Stones: Our Initial Experience

Taiwo Opeyemi Alabi, Emmanuel Ajibola Jeje¹, Moses Adebisi Ogunjimi¹, Rufus Wale Ojewola¹

Robertson Medical Centre,
¹Department of Surgery,
College of Medicine
University of Lagos/Lagos
University Teaching Hospital,
Idi-Araba, Surulere, Lagos,
Nigeria

ABSTRACT

Aims: The aim of this study is to present our initial experience with intracorporeal pneumatic ureterolithotripsy highlighting the pattern of patients' clinical presentation, techniques, and limitation of the procedure. **Materials and Methods:** This is a retrospective study of cases of ureteric stones managed over a period of 18 months in a private hospital. Data obtained include patients' sociodemography, clinical presentation, stone burden, procedural technique, complication, and need for a secondary procedure. Data were analyzed using the Statistical Package for the Social Sciences version 21. **Results:** The total number of patients managed was 20 with an age range of 28–75 years and a mean of 48.2 ± 12.4 years. Majority of them, i.e., 11 (55%) were middle aged. Female gender was more predominant, 11 (55%). Flank pain was the most common mode of presentation. Right-sided stone occurred in 9 (45%), left sided in 7 (35%), and bilateral in 4 (20%). Stone location was in the upper ureter in 4 (16.7%), mid-ureter in 7 (29.2%), and lower ureter in 13 (54.2%). The stone size ranged from 6 to 18 mm with a mean of 9.7 ± 2.5 mm. Four patients (20%) required initial bilateral ureteric stenting before definitive procedure to allow for recovery from sepsis and/or nephropathy. All patients had double-J stenting and were discharged 2 days after the procedure. The procedure was successful in 19 (95%) with 100% stone clearance rate and complete resolution of symptom without any complication. One patient (5%) had a very hard upper ureteric stone which retropulsed into the renal pelvis requiring open nephrolithotomy. **Conclusion:** Endoscopic treatment of ureteric stone with intracorporeal pneumatic lithotripsy is a safe and effective treatment modality. It is, however, limited in the management of hard upper ureteric stone, especially those that are close to the pelviureteric junction due to the risk of retropulsion of the stone into the kidney.

KEYWORDS: Endoscopic, ureteric stone, ureterolithotripsy

INTRODUCTION

Ureteric stone is uncommon in our environment;^[1] hence, there appears to be little or no investment in minimal access stone management modality both in terms of gadgetry and human capacity. Options of the treatment of ureteric stone include extracorporeal shockwave lithotripsy (ESWL), ureteroscopy (URS), percutaneous nephrolithotomy, laparoscopy, robotically assisted stone removal, and open surgery.^[2] URS and ESWL are considered the first-line treatment options.^[3] The latter has the least morbidity and lowest complication rate, but its major drawback is in low stone-free rate.^[4] URS, on the other hand, has a greater stone-free rate (>90%),

making it the most preferred first-line option, especially for mid and distal ureteric stones.^[5] Fragmentation of stone with holmium-YAG laser energy appears to be the most preferred. However, laser is expensive, hence not available in most hospitals in Nigeria. It is available only in very few private hospitals where the cost cannot be afforded by an average Nigerian patient.

Address for correspondence: Dr. Rufus Wale Ojewola,
Department of Surgery, College of Medicine University of
Lagos/Lagos University Teaching Hospital, PMB 12003, Idi-Araba,
Surulere, Lagos, Nigeria.
E-mail: rwaleojewola@yahoo.com

This is an open access journal, and articles are distributed under the terms of the Creative Commons Attribution-NonCommercial-ShareAlike 4.0 License, which allows others to remix, tweak, and build upon the work non-commercially, as long as appropriate credit is given and the new creations are licensed under the identical terms.

For reprints contact: reprints@medknow.com

How to cite this article: Alabi TO, Jeje EA, Ogunjimi MA, Ojewola RW. Endoscopic management of ureteric stones: Our initial experience. *Niger J Surg* 2019;25:26-9.

Access this article online	
Quick Response Code: 	Website: www.nigerianjsurg.com
	DOI: 10.4103/njs.NJS_20_18

Open ureterolithotomy is usually not preferred in most well-equipped endourological practice.^[2] Lagos is a cosmopolitan megacity with a dynamic clientele; as such, we frequently encounter patients who are aware of the minimally invasive stone treatment options and often demand for it.

We present our initial experience with URS and stone fragmentation with our newly acquired pneumatic lithotripsy machine.

MATERIALS AND METHODS

This is a retrospective study of all cases of ureteric stones seen over 18 months from February 2016 to July 2017 who were offered minimal access treatment. All patients had initial computerized tomographic scan done to assess the stone burden. Stone location, size, and Hounsfield units were noted and documented. Culture-negative urine was ensured before all procedures. Initial cystoscopy was done, ureteric orifice was then identified, and 0.025 nitinol safety guidewire passed up the ureter into the kidney through a 6F ureteric catheter until resistance was felt and the guidewire then secured to the drape. URS was then done using 6/7.5 Fr semi-rigid URS (by Richard Wolf) until the stone was visualized. The ureteroscope was introduced either directly or through a 22 Fr cystoscope sheath which serves the dual purpose of protecting the urethra as well as draining the bladder. In situations where it is difficult to pass the guidewire across an impacted stone, URS was done first and guidewire passed by the side of the stone under direct vision. Patients who had tight ureteric orifices were offered balloon dilatation before URS. Stone fragmentation was done *in situ* with pneumatic lithotripsy machine (Lithomed). A 3 Fr tri-prong stone forceps was then used to retrieve stone fragments which were either dropped into the bladder or brought out through the cystoscope sheath. Care was taken not to bruise the wall of the ureter with the stone fragments during retrieval. Stone fragments were retrieved from the bladder using Elik evacuator. Ureteral stenting was then done over the safety guidewire without image guidance due to nonavailability of C-arm in our center. Urethral catheterization was then done to rest the bladder for 24 h. Tamsulosin (0.4 mg daily) and tolterodine (2 mg twice daily) were given for 2 weeks to all patients to alleviate stent discomfort. Duration of admission was 2–3 days. Epidural or general anesthesia was used. Ureteric stent removal was done 4 weeks postoperation. Plain abdominopelvic X-ray was done in all patients before stent removal.

Data obtained on patients' sociodemography, clinical presentation, stone burden, procedural technique,

complication, and need for a secondary procedure were imputed and analyzed using the Statistical Package for the Social Sciences SPSS Statistics for Windows, Version 21.0. (IBM Corp., Armonk, NY, USA).

RESULTS

A total number of 20 patients were managed over the study period with an age range of 28–75 years and a mean of 48.2 years \pm 12.4 standard deviation (SD). Majority of the patients, i.e., 11 (55%) were middle aged [Figure 1]. Male patients were 9 (45%) while female patients were 11 (55%).

The most common mode of presentation is flank pain, either alone 16 (80%) or in combination with hematuria 1 (5%) or sepsis 1 (5%). Nephropathy and sepsis occurred in 1 (5%) while nephropathy alone occurred in 1 (5%) [Table 1].

Stone location was in the upper ureter in 4 (16.7%), mid-ureter in 7 (29.2%), and lower ureter in 13 (54.2%). The stone size ranged from 6 to 18 mm with a mean of 9.7 \pm 2.5 (SD). The Hounsfield unit of the stones ranged from 483 to 1302 with a mean of 907 \pm 178.7 (SD) [Table 2].

Epidural anesthesia was used in 19 (95%) while general anesthesia was used in 1 (5%) of the cases. Ureteric balloon dilatation was required before URS in 3 (15%). Four patients (20%) required initial bilateral ureteric stenting before definitive procedure to allow for recovery

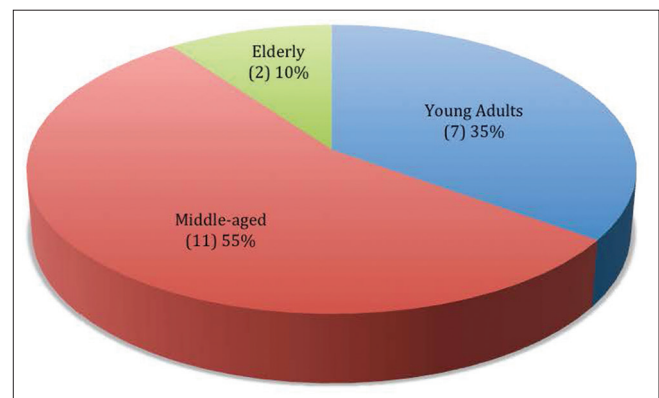


Figure 1: Age distribution of patients

Table 1: Pattern of clinical presentation

Clinical presentation	Frequency, n (%)
Flank pain	16 (80)
Flank pain and hematuria	1 (5)
Flank pain and sepsis	1 (5)
Sepsis and nephropathy	1 (5)
Nephropathy	1 (5)
Total	20 (100)

Table 2: Stone burden in patients

	Range	Mean
Stone size (mm)	6-18	9.7±2.5 (SD)
Hounsfield unit	483-1302	907±179.0 (SD)
Laterality	Side	Frequency (%)
	Right	9 (45.0)
	Left	7 (35.0)
	Bilateral	4 (20.0)
Stone location	Site	Frequency (%)
	Upper ureter	4 (16.7)
	Mid-ureter	7 (29.2)
	Lower ureter	13 (54.2)

SD: Standard deviation

from sepsis and/or nephropathy. All patients had “double J” stenting, tolterodine, and tamsulosin and were discharged 2 days after the procedure. The procedure was successful in 19 (95%) patients with 100% stone clearance rate and complete resolution of symptom without any complication. One patient (5%) had a very hard upper ureteric stone which retropulsed into the renal pelvis requiring open nephrolithotomy.

DISCUSSION

Our center receives referral from many hospitals across and sometimes outside Lagos; hence, twenty patients with ureteric stone seen over 18 months showed that there is a low volume of patients with ureteric stone in our environment compared to Europe and the United States of America where the lifetime risk of urolithiasis is estimated to be between 5% and 12%.^[3] The mean age in our study of 48.2 years ± 12.4 (SD) was similar to that reported by Aghamir *et al.*^[6] with majority of their patients in the middle-age group. There is a slight female preponderance in our study; this is similar to the finding by Mello *et al.*^[7] but at variance with most of the other previous studies which reported male preponderance.^[3,8] Estrogen has been shown to be protective for stone;^[9] the female preponderance in our study can be explained by the fact that majority of the patient were middle-age group during which many of the female were peri/postmenopausal.

Flank pain either alone or in combination with other symptoms was the most common mode of presentation, a finding similar to the report by McCarthy *et al.*^[10] Almost all our patients were referral cases who have had nonsteroidal anti-inflammatory drugs and failed medical expulsion therapy.

The analysis of stone laterality showed a slight right-sided preponderance and finding similar to that has been reported by previous studies.^[8] Our result showed that majority of the stones were lodged in the distal ureter (54.2%), a finding similar to other previous

studies;^[8,11,12] this might be because the intramural ureter terminating in ureteric orifice is the narrowest part of the ureter. Our experience showed that epidural anesthesia provided satisfactory anesthesia for all our cases, and only one patient who was obese with difficult epidural had general anesthesia. A similar finding was reported by Razzaghi *et al.*^[8] who had all their procedure done with spinal anesthesia.

The stone burden in our study (mean diameter of 9.7 mm ± 2.5 [SD]) is comparable to the study by Razzaghi *et al.*^[8] (10.0 mm ± 5.6 SD); nevertheless, we had a higher stone clearance rate of 100% compared to 82.1% in their study. This might be due to the stone fragments retrieval with forceps in our study rather than just fragmentation alone done in their study.

Stone retropulsion is a major limitation in the use of pneumatic lithotripsy; rates of up to 17.9% have been reported.^[8] We devised a technique of turning down the pressure of irrigation fluid as well as hitting the stone at the upper end and periphery rather than headlong, and this helped to reduce our overall rate of stone retropulsion to 5%. Hematuria, which subsided within an hour after surgery was noticed in most patients.

None of our patients experienced stent discomfort or flank pain postoperatively; this corroborates the efficacy of tamsulosin and tolterodine in alleviating stent discomfort which has been proven by previous studies.^[13]

A major limitation of this study is nonavailability of C-arm fluoroscopy to aid intraoperative insertion of endoscopic instrument and location of stone as well as accurate placement of ureteric stent postoperatively. This is the standard practice. We hope that availability of this facility in the near future will enhance our skills to treat ureteric stone better in term of duration of surgery and clearance rate in our center.

CONCLUSION

URS, stone fragmentation with pneumatic lithoclast, and stone fragment retrieval with stone forceps are a safe and effective treatment modality for ureteric stone, having excellent stone clearance rate. However, larger randomized studies are required to further prove these findings.

Financial support and sponsorship

Nil.

Conflicts of interest

There are no conflicts of interest.

REFERENCES

1. Mbonu O, Attah C, Ikeakor I. Urolithiasis in an African population. *Int Urol Nephrol* 1984;16:291-6.

2. Ather MH, Paryani J, Memon A, Sulaiman MN. A 10-year experience of managing ureteric calculi: Changing trends towards endourological intervention – Is there a role for open surgery? *BJU Int* 2001;88:173-7.
3. Preminger GM, Tiselius HG, Assimos DG, Alken P, Buck C, Gallucci M, *et al.* 2007 guideline for the management of ureteral calculi. *J Urol* 2007;178:2418-34.
4. Park H, Park M, Park T. Two-year experience with ureteral stones: Extracorporeal shockwave lithotripsy v ureteroscopy manipulation. *J Endourol* 1998;12:501-4.
5. Bader MJ, Eisner B, Porpiglia F, Preminger GM, Tiselius HG. Contemporary management of ureteral stones. *Eur Urol* 2012;61:764-72.
6. Aghamir SM, Hamidi M, Salavati A, Mohammadi A, Farahmand H, Meysamie AP, *et al.* Is antibiotic prophylaxis necessary in patients undergoing ureterolithotripsy? *Acta Med Iran* 2011;49:513-6.
7. Mello MF, Marchini GS, Câmara C, Danilovic A, Levy R, Eluf-Neto J, *et al.* A large 15 – Year database analysis on the influence of age, gender, race, obesity and income on hospitalization rates due to stone disease. *Int Braz J Urol* 2016;42:1150-9.
8. Razzaghi MR, Razi A, Mazloomfard MM, Golmohammadi Taklimi A, Valipour R, Razzaghi Z, *et al.* Safety and efficacy of pneumatic lithotripters versus holmium laser in management of ureteral calculi: A randomized clinical trial. *Urol J* 2013;10:762-6.
9. Heller HJ, Sakhaee K, Moe OW, Pak CY. Etiological role of estrogen status in renal stone formation. *J Urol* 2002;168:1923-7.
10. McCarthy JP, Skinner TA, Norman RW. Urolithiasis in elderly. *Can J Urol* 2011;18:5717-20.
11. Giulianelli R, Gentile BC, Vincenti G, Mavilla L, Albanesi L, Attisani F, *et al.* Low-cost semirigid ureteroscopy is effective for ureteral stones: Experience of a single high volume center. *Arch Ital Urol Androl* 2014;86:118-22.
12. Ahmed AF, Gabr AH, Emara AA, Ali M, Abdel-Aziz AS, Alshahrani S, *et al.* Factors predicting the spontaneous passage of a ureteric calculus of ≤ 10 mm. *Arab J Urol* 2015;13:84-90.
13. Tehranchi A, Rezaei Y, Khalkhali H, Rezaei M. Effects of terazosin and tolterodine on ureteral stent related symptoms: A double-blind placebo-controlled randomized clinical trial. *Int Braz J Urol* 2013;39:832-40.