

Images in clinical medicine

Knife ingestion in an eighteen months child

Leila Debono, Nour Mekaoui

Corresponding author: Leila Debono, Pediatric's Medical Emergencies, Children's Hospital of Rabat, Rabat, Maroc.
leila.debono@gmail.com

Received: 09 Aug 2020 - **Accepted:** 11 Aug 2020 - **Published:** 25 Aug 2020

Keywords: Knife, ingestion, child, emergencies

Copyright: Leila Debono et al. Pan African Medical Journal (ISSN: 1937-8688). This is an Open Access article distributed under the terms of the Creative Commons Attribution International 4.0 License (<https://creativecommons.org/licenses/by/4.0/>), which permits unrestricted use, distribution, and reproduction in any medium, provided the original work is properly cited.

Cite this article: Leila Debono et al. Knife ingestion in an eighteen months child. Pan African Medical Journal. 2020;36(336). 10.11604/pamj.2020.36.336.25465

Available online at: <https://www.panafrican-med-journal.com//content/article/36/336/full>

Knife ingestion in an eighteen months child

Leila Debono^{1,&}, Nour Mekaoui¹

¹Pediatric's Medical Emergencies, Children's Hospital of Rabat, Rabat, Maroc

&Corresponding author

Leila Debono, Pediatric's Medical Emergencies, Children's Hospital of Rabat, Rabat, Maroc

Images in clinical medicine

A Male child of eighteen months old was admitted in the pediatric medical emergency department for ingestion of foreign body while he was playing with his seven years old sister. He was not presenting any symptoms. The clinical examination was normal: he was conscious, calm, with no respiratory distress. The inspection of oropharynx did not find any abrasions or lacerations and the abdomen examination was normal. A thoraco abdominal X-ray showed an image of a knife measuring 12cm between the lower third of the esophagus and the stomach. A second X-ray with the undressed child confirmed the diagnosis (A). A second anamnesis made the sister confess that they were watching a television show of sword swallows when her

brother ingested the knife. The patient was admitted in the operating room to extract the sharp object. The surgical removal did not find any lesions of the gastrointestinal tract and was successful (B).

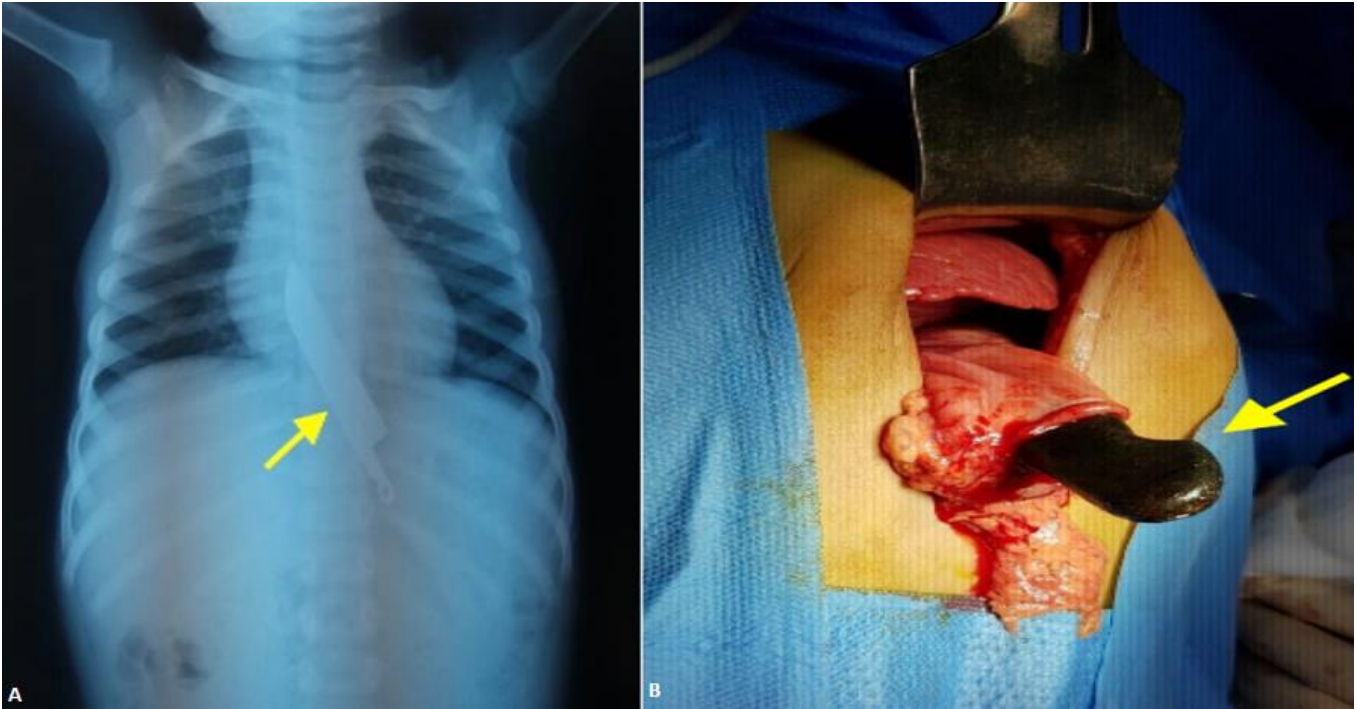


Figure 1: knife ingestion in an eighteen months child (A,B)