

UMass Chan Medical School

eScholarship@UMassChan

---

Open Access Publications by UMass Chan Authors

---

2021-03-06

## Echocardiographic pre-pause imaging and identifying the acoustic window during CPR reduces CPR pause time during ACLS - A prospective Cohort Study

Romolo Joseph Gaspari

*University of Massachusetts Medical School*

*Et al.*

Let us know how access to this document benefits you.

Follow this and additional works at: <https://escholarship.umassmed.edu/oapubs>



Part of the Analytical, Diagnostic and Therapeutic Techniques and Equipment Commons, Cardiovascular Diseases Commons, and the Emergency Medicine Commons

---

### Repository Citation

Gaspari RJ, Harvey J, DiCroce C, Nalbandian A, Hill M, Lindsay R, Nordberg A, Graham P, Kamilaris A, Gleeson TP. (2021). Echocardiographic pre-pause imaging and identifying the acoustic window during CPR reduces CPR pause time during ACLS - A prospective Cohort Study. Open Access Publications by UMass Chan Authors. <https://doi.org/10.1016/j.resplu.2021.100094>. Retrieved from <https://escholarship.umassmed.edu/oapubs/4816>

Creative Commons License



This work is licensed under a [Creative Commons Attribution-NonCommercial-No Derivative Works 4.0 License](https://creativecommons.org/licenses/by-nc-nd/4.0/). This material is brought to you by eScholarship@UMassChan. It has been accepted for inclusion in Open Access Publications by UMass Chan Authors by an authorized administrator of eScholarship@UMassChan. For more information, please contact [Lisa.Palmer@umassmed.edu](mailto:Lisa.Palmer@umassmed.edu).

Available online at [www.sciencedirect.com](http://www.sciencedirect.com)

# Resuscitation Plus

journal homepage: [www.journals.elsevier.com/resuscitation-plus](http://www.journals.elsevier.com/resuscitation-plus)

## Clinical paper

# Echocardiographic pre-pause imaging and identifying the acoustic window during CPR reduces CPR pause time during ACLS – A prospective Cohort Study

Romolo Gaspari<sup>a,\*</sup>, Justin Harvey<sup>b</sup>, Christopher DiCroce<sup>b</sup>, Ari Nalbandian<sup>b</sup>, Michael Hill<sup>b</sup>, Robert Lindsay<sup>a</sup>, Alexandra Nordberg<sup>a</sup>, Powell Graham<sup>b</sup>, Andrew Kamilaris<sup>b</sup>, Timothy Gleeson<sup>a</sup>

<sup>a</sup>UMASS Memorial Medical Center, United States

<sup>b</sup>Department of Emergency Medicine, UMASS Memorial Medical Center, United States

### Abstract

**Objectives:** Pre-pause imaging during cardiopulmonary resuscitation (CPR) involves the acquisition of poor-quality, brief images immediately prior to stopping CPR to allow shorter, better-quality images during the pause. We hypothesize that pre-pause imaging is associated with a decrease in CPR pause length and shorter image acquisition time.

**Methods:** Prospective, interventional cohort study enrolling out-of-hospital (OOH) cardiac arrest patients. Pre-pause imaging involves pre-localizing of the approximate sonographic window during CPR to support subsequent fine tuning when CPR pauses. Physicians were educated on pre-pause imaging and data was recorded prior- and post- introduction of pre-pause imaging into American cardiac life support (ACLS). Timing of CPR pauses and identification of interventions and events during pause were recorded (e.g., intubation, defibrillation, multiple cardiac ultrasounds). Ultrasound (US) images were reviewed for image quality using a 5-point scale. Primary outcome was length of CPR pause with and without pre-pause imaging. Secondary outcome included US length.

**Results:** One hundred and forty five subjects presenting after OOH cardiac arrest were enrolled over 13 months, 70 during the baseline period prior to pre-pause imaging and 75 after pre-pause imaging was integrated into ACLS. Pre-pause imaging decreased CPR pause length from 28.3 s (95%CI 25.1–31.5) to 12.8 s (95%CI 11.9–13.7). US image acquisition time decreased with pre-pause imaging from 20.4 (95%CI 18.0–22.7) to 11.0 s (95%CI 10.1–11.8). US image quality was unchanged despite the decrease in image acquisition time. (3.0 (95%CI 2.8–3.2) vs 2.7 (95%CI 2.5–2.9)). Multivariate modeling showed that ultrasound did not prolong CPR pause length.

**Conclusion:** Pre-pause imaging was associated with significant decrease in CPR pause length and US image acquisition time. Pre-pause imaging should be encouraged for any clinicians who use ultrasound during ACLS.

**Keywords:** Cardiac arrest, Echocardiography, Research methodology, Ultrasound image quality

*Abbreviations:* 95%CI, 95% confidence intervals; ACLS, Advanced Cardiac Life Support; CPR, cardiopulmonary resuscitation; Echo, echocardiography; ECG, electrocardiography; ED, emergency department; OHCA, out of hospital cardiac arrest.

\* Corresponding author at: UMASS Memorial Medical Center, 55 Lake Ave North, Worcester, MA 01655, United States.

E-mail addresses: [Romolo.Gaspari@umassmemorial.org](mailto:Romolo.Gaspari@umassmemorial.org) (R. Gaspari), [Justin.Harvey@umassmemorial.org](mailto:Justin.Harvey@umassmemorial.org) (J. Harvey), [Christopher.DiCroce@umassmemorial.org](mailto:Christopher.DiCroce@umassmemorial.org) (C. DiCroce), [Ari.Nalbandian@umassmemorial.org](mailto:Ari.Nalbandian@umassmemorial.org) (A. Nalbandian), [Michael.Hill@umassmemorial.org](mailto:Michael.Hill@umassmemorial.org) (M. Hill), [Robert.Lindsay@umassmemorial.org](mailto:Robert.Lindsay@umassmemorial.org) (R. Lindsay), [Alexandra.Nordberg@umassmemorial.org](mailto:Alexandra.Nordberg@umassmemorial.org) (A. Nordberg), [Powell.Graham@umassmemorial.org](mailto:Powell.Graham@umassmemorial.org) (P. Graham), [Andrew.Kamilaris@umassmemorial.org](mailto:Andrew.Kamilaris@umassmemorial.org) (A. Kamilaris), [Timothy.Gleeson@umassmemorial.org](mailto:Timothy.Gleeson@umassmemorial.org) (T. Gleeson).

<http://dx.doi.org/10.1016/j.resplu.2021.100094>

Received 2 December 2020; Received in revised form 25 January 2021; Accepted 9 February 2021

2666-5204/© 2021 The Authors. Published by Elsevier B.V. This is an open access article under the CC BY-NC-ND license (<http://creativecommons.org/licenses/by-nc-nd/4.0/>).

---

## Introduction

### Background

Survival following out-of-hospital (OOH) cardiac arrest has been slowly increasing over the last decade, but overall survival remains poor with survival rates of 7–11%.<sup>1–3</sup> Interventions for subjects presenting in cardiac arrest follow Advanced Cardiac Life Support (ACLS) protocols. Standard echocardiographic techniques have been abbreviated to facilitate imaging of the heart during cardiac arrest but recent publications suggest that use of echocardiography (echo) during ACLS contributes to longer pauses in cardiopulmonary resuscitation (CPR).<sup>4,5</sup> The “CAB protocol” combines echo and other ultrasound imaging to diagnose pathology related to cardiac arrest but does not address potential effects on CPR pauses.<sup>6</sup> The “CASA protocol” splits the imaging protocol in order to create multiple shorter pauses in CPR.<sup>7</sup>

Brief echo as performed during cardiac arrest ideally involves obtaining a view of the heart within the 10-s pause in CPR advocated by ACLS guidelines. We propose a novel technique using pre-pause imaging which involves obtaining low-quality, partial images of the heart during active compressions contiguous with and immediately prior to pausing CPR and obtaining higher quality echo images during the pause. This study represents the first exploration of a novel image acquisition technique on the length of image acquisition during ACLS.

### Goals of this investigation

In this manuscript we describe the effect of pre-pause imaging on CPR pause length in OOH cardiac arrest patients.

---

## Methods

### Study design and setting

This study is an interventional cohort study involving a baseline period and interventional period. The study was conducted at the Department of Emergency Medicine at UMASS Memorial Medical Center in Worcester, MA from November 2018 through November 2019. The hospital is a level 1 trauma center at an academic hospital in New England with an emergency medicine residency and emergency ultrasound fellowship and sees 75,000 patients per year.

We prospectively and consecutively enrolled OOH cardiac arrest patients who presented to the emergency department with ongoing CPR. Subjects were identified through video capture of the resuscitation bay where care for this patient population occurs. The first 6 months of the study represented the baseline period prior to introducing our intervention. The second 7-month period represents the interventional period. The hospital's institutional review board reviewed and approved this study without consent.

### Participants

All adult subjects presenting following an atraumatic OOH cardiac arrest with ongoing CPR were screened for inclusion. Cardiac arrest patients were imaged using one of two techniques, subxyphoid or parasternal approach. Subjects were excluded if resuscitation efforts were halted based on end-of-life care decisions, if the video recording

was lost and not reviewable, or if the clinician performing the echo was not credentialed. Credentialing for bedside cardiac echo at the hospital is achieved once the clinician performed 25 proctored cardiac echos that are recorded and reviewed for quality. Subjects imaged by non-credentialed resident physicians who performed the echo under the guidance of a supervising faculty member were excluded. Clinician echo experience is included in the supplemental materials.

### Intervention

At the 6-month point of the study, emergency physicians and residents at UMASS Memorial Medical Center underwent a standardized 30 min training session on ultrasound in cardiac arrest with an emphasis on using pre-pause imaging to decrease image acquisition time. Training consisted of a didactic session describing the technique of pre-pause imaging and importance of short CPR pauses. Physicians participating in the education were informed of the study hypothesis at this time. Prior to this study there was no specific protocol for cardiac arrest echo with regard to either technique or timing. Multiple training sessions were held to accommodate all individuals. A record was kept of sign-in sheets for all training to determine who completed the training.

Echocardiographic pre-pause imaging involves placing the ultrasound transducer on the subject's skin during CPR to identify the cardiac “window” or the place where the ultrasound beam penetrates the tissue and can visualize the heart. Poor quality images of the heart are visible to assure appropriate placement of the transducer once CPR is stopped. Image acquisition commences immediately after CPR is halted. This technique produces poor-quality cardiac images but enables identification of an optimal viewing window. Once CPR is stopped, the transducer remains already localized to more rapidly obtain high quality images. CPR is resumed after a pause as soon as indicated by the clinician obtaining the echo images. Resuscitation decisions, including when to stop the resuscitation, are directed by an attending physician who is different from the physician who obtained the echo images. Imaging protocol involves attention to keeping the pause under 10s.

### Measurements

Timing data were collected from review of motion-activated video recordings of the resuscitation room by individuals unblinded to the study hypothesis. Ultrasound equipment included 2 machines (Mindray, Mahwah NJ, and Phillips, Bothell WA) with cardiac transducers (2–4 MHz). Video recording occurred 24 h a day, 7 days a week. Timing of the total cardiac arrest as well as each pause was recorded on a pre-printed study sheet and recorded by a single provider unblinded to the study proposal. Resuscitation start and stop times were defined a priori as (1) the second the subject was transferred from the ambulance stretcher to the hospital stretcher and (2) the second the last round of CPR ceased. Echo image acquisition time was defined as starting with the application of the ultrasound transducer to the subject's skin and stopping when the sonographer took the transducer off of the subject's chest wall. Times were recorded in seconds. CPR pause duration was defined as when manual or mechanical compressions were ceased to when manual or mechanical compressions restarted. The final CPR pause was considered post-resuscitative and excluded from analysis if the pause was followed by cessation of resuscitation efforts.

Additional data was collected from the electronic medical record using a standardized data sheet and transcribed into an electronic

database by individuals unblinded to the study hypothesis. Data included resuscitation-related data points, patient data points, and echocardiographic data points. See supplemental material for full list of data points. Survival data was abstracted from the electronic medical record. There was no missing data in the database when prepared for statistical analysis.

Echo image quality and presence or absence of sonographic cardiac activity was recorded and stored in an electronic database. Cardiac activity was defined as “any visible movement of the myocardium excluding movement of blood within the cardiac chambers or isolated valve movement.”<sup>8</sup> Echo images were digitally recorded and reviewed in a blinded fashion by two physicians experienced in bedside cardiac echo and blinded to clinical characteristics or study period. Both reviewers had previously performed or interpreted over 1000 echos. Adjudication was performed if there was disagreement between the initial two reviews by having both physicians review the images together and decide on a single image rating. Images were analyzed for the presence or absence of cardiac activity, the presence or absence of organized cardiac activity, and image quality. Organized cardiac activity was defined as “movement of the myocardium with change in size of the ventricular cavity and synchronized movement of the ventricular wall.”<sup>9</sup>

### Image quality rating scale

The image quality rating scale was designed by two of the authors (RG, FT) to objectively rate image quality in echo during cardiac arrest. The image quality rating was performed using a 5-point image quality scale, designed using a modified Delphi technique through iterative improvements in the image-rating tool by experts in bedside echo. Image quality ratings from poor to excellent were 1 – unable to interpret, 2 – sufficient to detect only if the heart is beating, 3 – sufficient to determine the quality of cardiac activity (organized vs. disorganized), 4 – sufficient to visualize internal details of heart (inner myometrium, valves, pathological findings), 5 – sufficient for quantitative analysis.

### Outcomes

Primary outcome was change in length of CPR pause after integration of pre-pause imaging into ACLS. Secondary outcomes included comparison of CPR pauses with and without echo, length of echo during pauses in CPR before and after integration of pre-pause imaging into ACLS, and differences in image quality of echo images before and after integration of pre-pause imaging into ACLS. Additional secondary outcomes included differences in survival before and after pre-pause imaging was included into ACLS.

### Analysis

Planned analysis included comparisons between the two study periods, pre- and post- introduction of pre-pause imaging as our primary assessment. Final pauses in the resuscitation were excluded from the pause analysis, defined as those pauses where ROSC occurred, or resuscitation efforts were halted and the subject was declared deceased. This is consistent with prior research. Planned secondary analyses included (1) comparing CPR pause length with and without pre-pause imaging independent of study period (2) Comparing subxyphoid and parasternal long (3) comparing image

quality with and without pre-pause imaging and (4) Multivariate analyses of factors associated with CPR pause length.

Demographics and clinical data are presented as means with 95% confidence interval (95%CI) or proportions with 95%CI. We include descriptive statistics at both the subject level and individual pause level. Between-group comparisons was performed using a general linear mixed model with pause times allowed to vary randomly within each case, setting pre- or post- intervention as the fixed effect variable. Agreement was assessed using Cohen's Kappa with weighted averages.

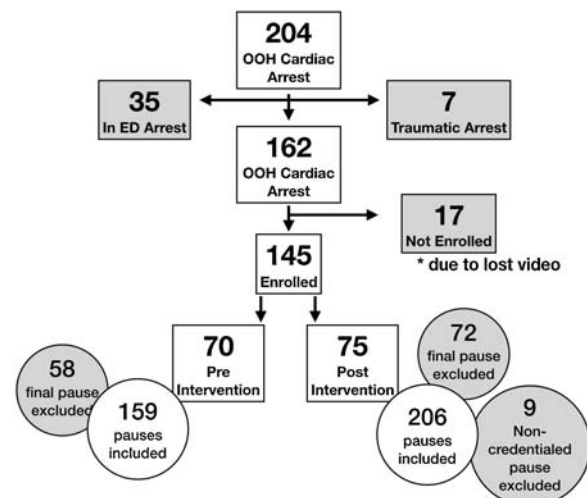
Sample size calculation was based on effect size seen in prior similar studies<sup>7</sup>. To detect a 15% difference in CPR pause duration between study groups would require 140 enrolled subjects in both study groups, assuming an alpha of 0.05 and a beta of 0.2. Calculations were performed using online sample size calculators at [SampleandPowerSize.com](http://SampleandPowerSize.com). Given our known annual volume of out-of-hospital cardiac arrest patients (180) we estimated that it would take 12 months of enrollment, or 6 months for the initial period and 6 months for the interventional period.

Multivariate modeling using standard least squares was used to analyze contributors to pause length, controlling for both subject and resuscitation variables determined by the authors to possibly contribute to CPR pause length. Variables included events during the CPR pause as well as cardiac rhythm. The analyses were performed using JMP Pro version 15 (SAS Institute Inc, Cary, NC).

## Results

### Characteristics and study subjects

One hundred and forty five of the of 162 subjects presenting with ongoing CPR after an atraumatic OOH cardiac arrest were enrolled in the study. 70 subjects were enrolled during the baseline period of the study and 75 during the interventional period of the study (after pre-pause imaging was incorporated into ACLS). See [Fig. 1](#). The basic characteristics of resuscitations for those included and excluded are in [Table 1](#). Agreement was substantial for presence or absence of “cardiac activity” and “organized cardiac activity” with a kappa of 0.78 and 0.76, respectively. Subjects had 159 pauses in CPR (2.3 pauses per resuscitation- 95%CI 1.9–2.7) during baseline period compared



**Fig. 1 – Study flow diagram.**

**Table 1 – Patient characteristics in those included and excluded from the study.**

|   | Included (n=145)        | Excluded (n=17)       |
|---|-------------------------|-----------------------|
| Gender, male – n (%)                              | 97 (67.4)               | 12 (52.2)             |
| Age – average, (95% CI)                           | 57.7 (56–60)            | 61.4 (52.5–70.2)      |
| Initial rhythm                                    |                         |                       |
| Asystole – n (%) – 95%CI                          | 68 (46.9) – 39.0 – 55.0 | 10 (58.8) – 36.0–78.4 |
| PEA – n (%) – 95%CI                               | 44 (30.1) – 23.4 – 38.3 | 5 (29.4) – 13.9–53.4  |
| Sinus – n (%) – 95%CI                             | 3 (2.0) – 0.4–6.2       | 1 (5.8) – 0.00–28.9   |
| Vfib – n (%) – 95%CI                              | 30 (21.0) – 14.9–28.0   | 4 (23.5) – 9.1–47.8   |
| Witnessed Arrest – n (%)                          | 74 (51.7) – 43.0–59.0   |                       |
| Bystander CPR – n (%)                             | 72 (50.4) – 41.6–57.7   |                       |
| ED presenting rhythm                              |                         |                       |
| Asystole – n (%) – 95%CI                          | 68 (47.1)               | 10 (58.8) – 36.0–78.4 |
| PEA – n (%) – 95%CI                               | 59 (41.0)               | 5 (29.4) – 13.9–53.4  |
| Sinus – n (%) – 95%CI                             | 4 (2.8)                 | 0 (0.0%) – 0.0–21.6   |
| Vfib – n (%) – 95%CI                              | 13 (9.0)                | 2 (11.8) – 2.0–35.6   |
| Mechanical Compression Pre-hospital n (%) – 95%CI | 106 (73.1)              |                       |
| ETT Pre-hospital n (%) – 95%CI                    | 112 (77.2)              | 13 (76.5) – 52.2–91.0 |
| Arrest Length in min – AVG, (95% CI)              | 15.6 (13.6–17.7)        | 16.39 (10.5–22.7)     |

CPR, cardiopulmonary resuscitation; ETT, endotracheal tube; ED, emergency department; Min, minutes; PEA, pulseless electrical activity; Vfib-ventricular fibrillation.

to 209 pauses during the interventional period (2.8 pauses per resuscitation–95%CI 2.3–3.4). Subjects were more commonly imaged using the subxyphoid (SX) technique during baseline and interventional periods of the study (68% and 58%). The majority of subjects (73%) had mechanically assisted compressions in the ED.

### Main results

The average CPR pause length for all pauses decreased from 28.3s (95%CI 25.1–31.5) to 12.8s (95%CI 11.9–13.7) after pre-pause imaging was incorporated into ACLS (Table 2). Echo acquisition times decreased from 20.4 (95%CI 18.0–22.7) to 11.0s (95%CI 10.1–11.8)

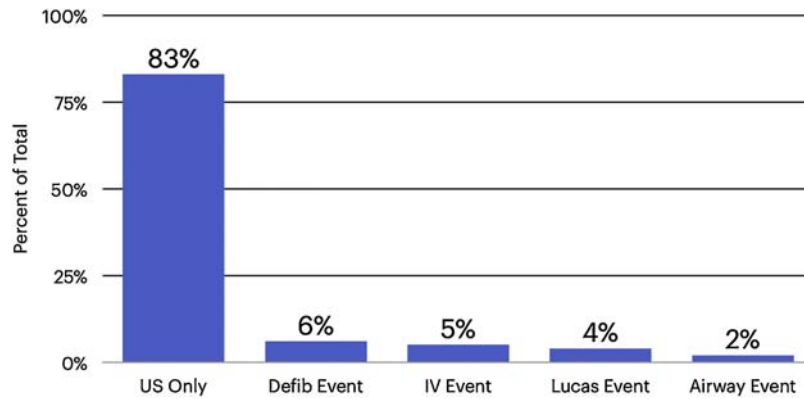
after pre-pause imaging was incorporated into ACLS. Seventy four percent (106 of 143) of echos performed during the interventional period used pre-pause imaging. During the interventional period echo acquisition time was faster when pre-pause imaging was used (5.5s faster, 11.8s (10.7–12.8) vs. 17.3s (15.2–19.4)). Image quality was not different when comparing the baseline and interventional periods (3.0 (95%CI 2.8–3.2) vs. 2.7 (95%CI 2.5–2.9)). The image quality agreement for all US was good with a weighted kappa of 0.68.

Subjects were imaged using the SX approach (64.7%), parasternal long (PSL) approach (35.3%), and multiple approaches (7.6%) during the study. The imaging approach was no different in either study periods. There were more cases with multiple echos performed

**Table 2 – CPR Pause Length.**

|  | Baseline period  | Interventional period |
|--|------------------|-----------------------|
| ALL pauses                                 |                  |                       |
| CPR Pause length (s)                       | 28.3 (25.1–31.5) | 12.8 (11.9–13.7)      |
| Pauses with US performed                   |                  |                       |
| CPR Pause length (s)                       | 29.7 (26.3–33.1) | 13.1 (12.1–14.2)      |
| US image acquisition length (s)            | 20.4 (18.0–22.7) | 11.0 (10.1–11.8)      |
| Non-US related CPR pause time (s)          | 9.3              | 2.1                   |
| Pauses with US – pre-pause imaging only    |                  |                       |
| CPR Pause length (s)                       |                  | 11.8 (10.7–12.8)      |
| US image acquisition length (s)            |                  | 9.9 (9.1–10.8)        |
| Non-US pause time (s)                      |                  | 1.9                   |
| Pauses with US – no pre-pause imaging only |                  |                       |
| CPR Pause length (s)                       |                  | 17.3 (15.2–19.4)      |
| US image acquisition length (s)            |                  | 13.8 (11.8–15.9)      |
| Non-US pause time (s)                      |                  | 3.5                   |

Data – Mean (95%CI).



**Fig. 2 – Events occurring during echocardiogram pauses in CPR.**

during a single pause in the baseline period compared to the interventional period. (1.4% (95%CI 0.06–5.2) vs. 10.5% (95%CI 6.1–17.2). There was no difference in image acquisition times when comparing SX and PSL long views (20.0 (95%CI 17.3–22.7) vs. 18.7 (95%CI 15.2–22.3),  $p=0.5808$ ), but CPR pauses were significantly longer when multiple cardiac echos were performed (45.0, 95%CI 31.9–63.7).

Echo image acquisition occurred simultaneous with other interventions or events in 17% of pauses (Fig. 2). The largest contributor to CPR pause length was the performance of multiple cardiac echos during the pause, followed by intravenous access during the pause and any non-echo event during the pause. See Table 3. Multivariate modeling of the pause controlling for events during the pause (defibrillation, intubation, intravenous catheter placement and mechanical compression events) and cardiac rhythm show CPR pauses were shorter with pre-pause imaging compared to without pre-pause imaging during the interventional phase (10.9s vs. 22.1s). CPR pauses with echo during the interventional phase were 35% longer when other interventions occurred during the same pause (11.4 vs. 14.4,  $p=0.0491$ ).

## Discussion

Cardiac echo with pre-pause imaging was associated with a significant decrease in CPR pause duration. The pre-pause imaging educational intervention may have improved CPR pause duration through decreased image acquisition time and a general stress on shortening CPR pauses. When looking at only cases after the educational intervention, CPR pauses with pre-pause imaging were significantly shorter than pauses with echo but no pre-pause imaging so the effect cannot be attributed only to a general attention to shortening the CPR pause. Both pre-pause imaging and a general focus on shortening CPR pause times likely contributed to our findings, but the effect of pre-pause imaging seems to be greater.

The pauses in CPR during the baseline period of the study were significantly longer than the recommended 10s but are comparable to prior publications on ultrasound and CPR. 4, 5 Although ACLS recommends 10s pauses, there is little real-world evidence or data to show that this is commonly achieved. Clattenberg showed that an ultrasound protocol (CASA protocol) could decrease CPR pause duration<sup>7</sup>, but the CASA protocol splits a single echo into multiple

**Table 3 – Factors in mean pause length Univariate.**

|   | Variable present (Yes) | Variable present (No) |
|---|------------------------|-----------------------|
| Gender, male                              | 18.4 (16.5–20.4)       | 21.9 (18.8–25.1)      |
| Age >50                                   | 18.8 (16.9–20.6)       | 21.0 (17.7–24.2)      |
| Mechanical compression pre-hospital       | 18.2 (16.6–19.8)       | 22.2 (18.2–26.1)      |
| Mechanical compression event during pause | 24.1 (14.4–33.7)       | 19.2 (17.5–20.9)      |
| ETT event during pause                    | 28.6 (16.3–40.9)       | 18.8 (17.3–20.3)      |
| IV event during pause                     | 30.3 (19.9–40.7)       | 18.9 (17.2–20.5)      |
| Defibrillation event during pause         | 15.1 (11.7–18.5)       | 20.0 (18.2–21.8)      |
| Any non-US event during pause             | 23.3 (18.9–27.7)       | 18.1 (16.5–19.7)      |
| Any US during pause                       | 20.3 (18.4–22.1)       | 17.7 (14.2–21.1)      |
| Multiple US during pause                  | 47.8 (31.9–63.7)       | 19.1 (17.3–21.0)      |
| Subxyphoid approach                       | 21.9 (19.2–24.6)       | 18.8 (15.7–21.9)      |
| Parasternal long approach                 | 21.8 (18.5–25.1)       | 20.1 (17.4–22.7)      |

Data is presented as mean pause length in seconds mean, (95% CI).

US, ultrasound; ETT, endotracheal tube; IV, intravenous; CPR, cardiopulmonary resuscitation.



shorter echos, each tasked at a single pathologic finding. It is notable that this resulted in a larger number of pauses in CPR and it is unclear if the aggregate time of paused CPR over multiple pauses was not actually greater.

Other studies have shown that echo can delay CPR if attention to timing and restarting CPR is not prioritized<sup>4, 5</sup> but the focus on the echo alone has ignored other activities that occur simultaneous with image acquisition. The longest delay in CPR in this study was associated with multiple cardiac echos during a single pause in CPR. Prior studies looking at delays in CPR related to ultrasound did not include multiple echo attempts in their modeling.<sup>5</sup> Our results do not support their conclusion that a single echo delays CPR. It is likely that any intervention during a pause in CPR could delay CPR, but our results show that attention to US technique may mitigate this effect.

Our findings, and the findings of others show that pauses in CPR are commonly longer than 10s<sup>4, 5</sup> unless there is an effort to reduce the pause length. Pre-pause imaging can reduce CPR pauses to under 10s, but additional work is needed to determine the best way to integrate ultrasound into ACLS.

### Limitations

This study was performed at a single site and the findings may not be applicable to other sites. In addition, the experience in echo for physicians at the site involved in the study may be greater than non-academic sites with less complexity in their ultrasound program. The images were reviewed by clinicians with extensive experience in echo and could have resulted in the interpretation of lower quality images that might have been uninterpretable to those with less experience. The baseline mean cardiac echo experience was 381 echos, which may be greater than the average emergency physician. The image quality rating scale used is novel and has not been validated in other studies. The investigators performing the timing assessments were not blinded to the study hypothesis, possibly introducing bias. This is less likely given the strict nature of the start and stop definitions but remains a limitation.

### Conclusion

Pre-pause imaging was associated with significant decrease in CPR pause length and US image acquisition time. Further research is needed to better define image acquisition techniques during cardiac arrest, but pre-pause imaging may help to better integrate ultrasound into ACLS.

### Funding sources

None declared.

### Credit author statement

RG conceived of the study and assumes responsibility for the study as a whole. All authors participated in study enrollment and database

entry. RG performed the statistical analysis. All authors edited the final manuscript and approved the submission.

### Ethical information

The study was performed with waiver of consent based on the review by the UMASS Institutional Review Board.

### Declaration of interest

None declared.

### Acknowledgements

The Imaging Rating Scale was produced by two authors (RG) and Felipe Teran, MD.

### Appendix A. Supplementary data

Supplementary data associated with this article can be found, in the online version, at <http://dx.doi.org/10.1016/j.resplu.2021.100094>.

### REFERENCES

1. Stiell IG, Wells GA, Field B, et al. Advanced cardiac life support in out-of-hospital cardiac arrest. *N Engl J Med* 2004;351(7):647–56.
2. Riva G, Ringh M, Jonsson M, et al. Survival in out-of-hospital cardiac arrest after standard cardiopulmonary resuscitation or chest compressions only before arrival of emergency medical services: nationwide study during three guideline periods. *Circulation* 2019.
3. Daya MR, Schmicker RH, Zive DM, et al. Out-of-hospital cardiac arrest survival improving over time: results from the Resuscitation Outcomes Consortium (ROC). *Resuscitation* 2015;91:108–15.
4. Clattenburg EJ, Wroe PC, Gardner K, et al. Point-of-care ultrasound use in patients with cardiac arrest is associated prolonged cardiopulmonary resuscitation pauses: a prospective cohort study. *Resuscitation* 2018;122:65–8.
5. Huis In't Veld MA, Allison MG, Bostick DS, et al. Ultrasound use during cardiopulmonary resuscitation is associated with delays in chest compressions. *Resuscitation* 2017;119:95–8.
6. Lien WC, Liu YP, Chong KM, et al. A novel US-CAB protocol for ultrasonographic evaluation during cardiopulmonary resuscitation. *Resuscitation* 2017;115:e1–2.
7. Clattenburg EJ, Wroe PC, Gardner K, et al. Implementation of the Cardiac Arrest Sonographic Assessment (CASA) protocol for patients with cardiac arrest is associated with shorter CPR pulse checks. *Resuscitation* 2018;131:69–73.
8. Gaspari R, Weekes A, Adhikari S, et al. Emergency department point-of-care ultrasound in out-of-hospital and in-ED cardiac arrest. *Resuscitation* 2016;109:33–9.
9. Gaspari R, Weekes A, Adhikari S, et al. A retrospective study of pulseless electrical activity, bedside ultrasound identifies interventions during resuscitation associated with improved survival to hospital admission. A REASON Study. *Resuscitation* 2017;120:103–7.