



Odontomas and imaging diagnosis: the concise systematic review

João Paulo Dessy Millan¹, Bárbara Castelli Gutinik¹, Lucas Louzada Mendes de Lima¹, Ana Katharina Gomes Teles¹, Tagnã Aparecido Martins¹, Leandro Moreira Tempest^{1,2*}

¹ University Center North Paulista (Unorp) - Sao Jose do Rio Preto, Sao Paulo, Brazil.

² Post graduate and continuing education (Unipos), Sao Jose do Rio Preto, Sao Paulo, Brazil.

*Corresponding author: Prof. Me. Leandro Moreira Tempest, Unorp/Unipos - Post graduate and continuing education, Sao Jose do Rio Preto, Sao Paulo, Brazil.

Email: leandrotempest@hotmail.com

DOI: <https://doi.org/10.54448/mdnt21504>

Received: 05-20-2021; Revised: 09-26-2021; Accepted: 09-28-2021; Published: 10-12-2021; MedNEXT-id: e21504

Abstract

Introduction: Odontomas are tumors of odontogenic origin. They represent on average 70% of all odontogenic tumors found. Early diagnosis and treatment prevent the loss of tissue element, tooth impaction, bone malformations, and displacement of bone structures, differentiating their types through panoramic radiographic images. **Objective:** To carry out a concise systematic review of the characteristics of odontomas, differentiating their types through panoramic radiographic images. **Methods:** The research was carried out from May 2021 to June 2021 and developed based on Scopus, PubMed, Science Direct, Scielo, and Google Scholar, following the Systematic Review-PRISMA rules. The quality of the studies was based on the GRADE instrument and the risk of bias was analyzed according to the Cochrane instrument. **Results:** A total of 84 articles were found. A total of 36 articles were evaluated in full and 17 were included and evaluated in the present study. A total of 3 Studies with a High Risk of Bias and 1 Study with Uncertain Risk. Radiographic examination is extremely important for the study and diagnosis of odontomas. Odontomas present a characteristic radiographic appearance. In complex odontomas, radiopacity is not specifically determined, showing itself as an irregular and disorganized mass surrounded by a narrow radiolucent zone. In the composite type, the radiographic image is pathognomonic. In the radiopaque image, dozens of denticles simulate small teeth surrounded by a thin radiolucent area. Composite odontoma, on the other hand, consists of the same calcified structures arranged in an orderly and related manner, similar to normal teeth contained in a fibrous

capsule. The differential diagnosis of complex odontoma includes osteomas and condensing osteitis. **Conclusion:** Radiographic and/or tomographic examination is the best way to obtain an accurate diagnosis, precisely delimiting the lesion and nearby and involved structures.

Keywords: Odontoma. Tumor. Bone malformation. Diagnosis. Image exams.

Introduction

Odontomas are tumors of odontogenic origin, also considered as developmental anomalies (hamartomas) of epithelial origin. They represent on average 70% of all odontogenic tumors found [1]. They preferentially affect individuals in the second and third decades of life, however, without finding prevalence in terms of gender [1]. The most frequent location of a compound odontoma is observed in the anterior region of the maxilla, and the complex odontoma occurs in the posterior region of both jaws [2].

Its etiology is still unknown, although traumas, infections, and genetic factors have been suggested [2,3]. These hamartomas are slow-growing and are formed by enamel, dentin, cementum, and pulp tissue. Odontomas are classified radiographically and histologically as complex and compound, some studies complement this classification by adding the mixed suffix, corresponding to the combination of the two types [4].

A compound odontoma is characterized by multiple calcified structures, similar to rudimentary teeth, and its incidence is greater in the anterior region of the maxilla. Complex odontomas are characterized by a mixture of disordered dentin tissue that morphologically does not resemble a tooth [5,6]. The so-called mixed, as the name

suggests, have clinical aspects that relate to the two types mentioned above. They are located preferentially in the posterior region of the jaws [6].

Also, odontomas are radiopaque and with their development, they can present a thin radiolucent halo surrounding their entire structure. Panoramic radiography is an exam that has the main advantage of showing all the tissues within the focal area, even with the patient's inability to open their mouth, thus facilitating the diagnosis of odontoma [7].

In this sense, treatment generally consists of surgical excision of the odontoma and sending it for histopathological research, discarding the existence of other pathologies. It is also noteworthy that imaging diagnosis and early treatment prevent the loss of tissue elements, tooth impaction, bone malformations, and displacement of bone structures [8].

Therefore, this work aimed to carry out a concise systematic review of the characteristics of odontomas, differentiating their types using panoramic radiographic images.

Methods

Study Design

The rules of the Systematic Review-PRISMA Platform (Transparent reporting of systematic reviews and meta-analysis-[HTTP://www.prisma-statement.org/](http://www.prisma-statement.org/)) were followed [9].

Data sources and research strategy

The search strategies for this systematic review were based on the keywords (MeSH Terms): "Odontoma. Tumor. Bone malformation. Diagnosis. Image exams". The research was carried out from May 2021 to June 2021 and developed based on Scopus, PubMed, Science Direct, Scielo, and Google Scholar. Also, a combination of the keywords with the booleans "OR", "AND", and the operator "NOT" were used to target the scientific articles of interest.

Study Quality and Bias Risk

The quality of the studies was based on the GRADE instrument [10] and the risk of bias was analyzed according to the Cochrane instrument [11]. Two independent reviewers carried out research and study selection. Data extraction was performed by reviewer 1 and fully reviewed by reviewer 2. A third investigator decided on some conflicting points and made the final decision to choose the articles.

Results and Discussion

A total of 84 articles were found on the odontomas and imaging diagnosis. Initially, duplication

of articles was excluded. After this process, the abstracts were evaluated and a new exclusion was performed, removing articles that did not include the theme of this article. A total of 36 articles were evaluated in full and 17 were included and evaluated in the present study (Figure 1).

Considering the Cochrane Tool for Risk of Bias, the Overall Assessment in 3 Studies with a High Risk of Bias and 1 Studies with Uncertain Risk. The domains that presented the highest risk of bias were related to the number of participants in each study addressed, and the uncertain risk was related to the safety and efficacy of the Odontomas. Also, there was an absence of the source of funding in 2 studies and 1 study did not disclose information about the conflict of interest statement.

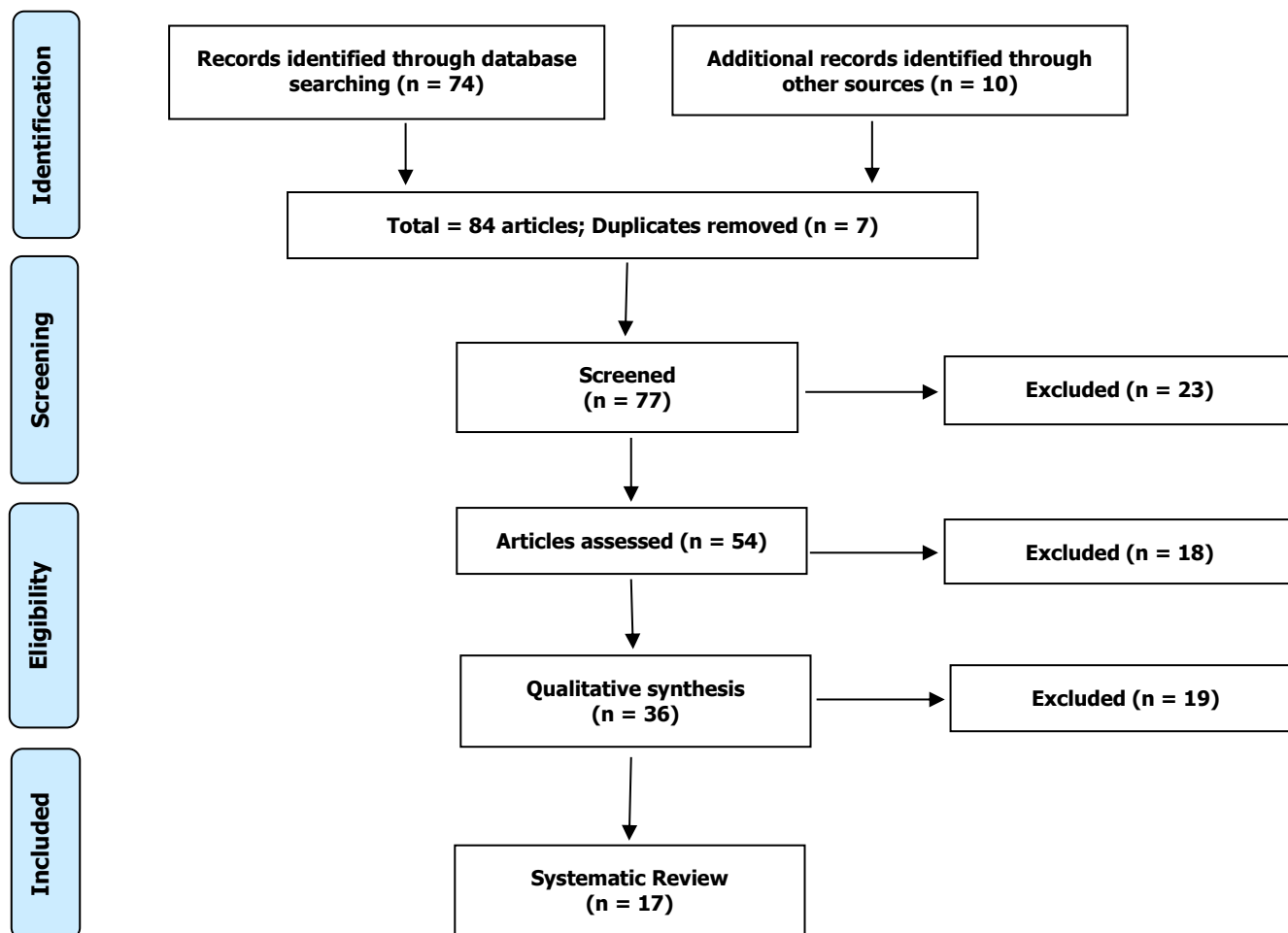
After a thorough analysis of these selected studies, it was found that according to the World Health Organization's International Classification of Tumors, odontomas are defined as malformations or hamartomas in which the epithelial and mesenchymal cells present complete differentiation with enamel formation and dentin [12].

The etiopathogenesis is a highly investigated aspect, although it is still undetermined. Factors such as genetic mutations or interference of a gene in controlling tooth development, trauma are suggested, or local infections, epithelial debris of Malassez, aberrant primitive germination of the dental lamina, abnormalities of the elements forming dental tissues, hyperactivity of the dental lamina, or maybe related to systemic diseases. Some investigators report that complex odontomas develop from the dental follicle, whereas compounds develop from an accessory proliferation of the epithelium odontogenic [12].

The World Health Organization in 1992 classified odontomas into compounds and complexes based on the degree of differentiation and tissue organization. Compound odontoma is a malformation in which all dental tissues are represented with an orderly distribution pattern, where the lesion consists of many structures similar to rudimentary teeth. The complex, on the other hand, is a malformation in which all dental tissues with a disordered distribution pattern are represented. Both the compound and the complex are surrounded by a fibrous capsule [13].

Sometimes odontomas may appear that represent a combination of both, compound or mixed odontoma. Clinically, they present as asymptomatic lesions, with slow growth and variable size. Odontomas can cause a series of disorders, highlighting the problems related to the interference in the tooth-eruption process, delaying or preventing ectopic eruption movements, and also possible sequelae such as displacement and malformation of

Figura 1. Eligibility.



neighboring teeth, a diastema, anodontia, and the pressure exerted by the odontoma can cause pain, devitalization, and tooth resorption. Radiographic examination is extremely important for the study and diagnosis of odontomas. Odontomas present a characteristic radiographic appearance [14].

In complex odontomas, radiopacity is not specifically determined, showing itself as an irregular and disorganized mass surrounded by a narrow radiolucent zone. In the composite type, the radiographic image is pathognomonic [1]. In the radiopaque image, dozens of denticles simulate small teeth surrounded by a thin radiolucent area. Under microscope examination, enamel or enamel matrix, dentin material, pulp tissue, and cementum may be seen with complete histodifferentiation, but arranged in a disorderly and unrelated manner, surrounded by a capsule of fibrous connective tissue in complex odontomas. Composite odontoma, on the other hand, consists of the same calcified structures arranged in an orderly manner and relation to each other, similar to normal teeth contained in a fibrous capsule [2].

Differential diagnosis of odontoma in the early and intermediate stages must be made with a series

of lesions, such as ossifying fibroma, periapical cemental dysplasia, adenomatoid odontogenic tumor, and calcifying epithelial odontogenic cyst. The differential diagnosis of complex odontoma includes osteomas and condensing osteitis. The treatment of odontoma is surgical, with simple removal. The possibility of recurrence is remote [8].

In this context, a retrospective study, demographic and clinical data of patients who presented odontomas in the period from 1995 to 2015 were obtained. A total of 45 patients, with a mean age of 14.2 years, with 29 complex odontomas and 16 composite odontomas were included. Thirty-two of 45 odontomas were close to at least 1 tooth. A total of 12 teeth were extracted and the rest were displaced and retained. Therefore, routine radiographic analysis is necessary [15].

Another study evaluated the presence of dentofacial asymmetry in patients with odontoma using panoramic radiography. Maxillary odontoma was detected in 27 patients, while mandibular odontoma was detected in 25 patients. In addition, 30 patients with similar characteristics of age and gender were selected as a control group. No

significant difference was found between the odontoma region and the symmetrical region of the maxilla and mandible. In the maxillary and mandibular odontoma groups, a significant difference was found in the angle between the mandibular canal and the chin, CH (mm), UR (mm), and CrH (mm) when comparing the odontoma and the control group [16].

Finally, a clinical case report showed a compound and asymptomatic odontoma on the left anterior aspect of the maxilla associated with a canine tooth in a 47-year-old woman. Cone-beam computed tomography was performed for the precise three-dimensional location of each structure and assessment of its spatial relationship with associated structures before surgery. The patient evolved uneventfully and proceeded with the prosthodontic treatment plan [17].

Conclusion

Radiographic and/or tomographic examination is the best way to obtain an accurate diagnosis, precisely delimiting the lesion and nearby and involved structures. Failure to remove the odontoma may cause complications, eruptive disorders, bone resorption, and displacement of dental elements. Its early removal facilitates the recovery of the tissues involved and should be surgical, through conservative techniques with total removal of the tumor, restoring health to the patient and preventing recurrences.

References

1. Zhang J, Troulis MJ, August M. Diagnosis and Treatment of Pediatric Primary Jaw Lesions at Massachusetts General Hospital. *J Oral Maxillofac Surg.* 2021 Mar;79(3):585-597. doi: 10.1016/j.joms.2020.09.012. Epub 2020 Sep 12. PMID: 33038300.
2. Maltagliati A, Ugolini A, Crippa R, Farronato M, Paglia M, Blasi S, Angiero F. Complex odontoma at the upper right maxilla: Surgical management and histomorphological profile. *Eur J Paediatr Dent.* 2020 Sep;21(3):199-202. doi: 10.23804/ejpd.2020.21.03.08. PMID: 32893652.
3. Marra PM, Lupo G, Itro A. Surgical management of compound odontomas: piezoelectric surgery or rotary instruments? A clinical study. *Minerva Stomatol.* 2020 Aug;69(4):203-206. doi: 10.23736/S0026-4970.19.04305-X. Epub 2020 Mar 16. PMID: 32181612.
4. Erden Sahin MB, Calis A, Koca H. An unusual case of 177 pieces of mandibular compound odontoma: 10-year follow-up. *J Stomatol Oral Maxillofac Surg.* 2020 Nov;121(5):585-588. doi: 10.1016/j.jormas.2020.03.013. Epub 2020 Mar 24. PMID: 32220610.
5. Kim KS, Lee HG, Hwang JH, Lee SY. Incidentally detected odontoma within a dentigerous cyst. *Arch Craniofac Surg.* 2019; 20(1): 62. PubMed PMID: 30840819.
6. Eswara UMA. Compound odontoma in anterior mandible - a case report. *Malays J Med Sci.* 2017; 24(3): 92. PubMed PMID: 28814937.
7. Kumar D, Singh G, Kapoor S, Sethi S, Bajaj P, Mittal S. Compound and complex odontoma associated with eruption disturbances and its management: report of two cases. *Dental J Advance Studies.* 2017; 5(1): 51-7.
8. Filipe Jaeger, Rodrigo López Alvarenga, Frederico Oliveira Lage, Igor Aguiar Reis, Rosana María Leal, Odontoma composto - relato de caso clínico, *Revista Portuguesa de Estomatologia, Medicina Dentária e Cirurgia Maxilofacial*, Volume 53, Issue 4, 2012, Pages 252-257, <https://doi.org/10.1016/j.rpemd.2012.06.002>
9. The PRISMA 2020 statement: an updated guideline for reporting systematic reviews. *BMJ* 2021; 372 doi: <https://doi.org/10.1136/bmj.n71>
10. H Balshem H, Grade guidelines: 3 rating the quality of evidence. *Journal of Clinical Epidemiology*, Maryland Heights, 64 (4) (2011) 401-406.
11. Higgins, S Green, *Cochrane Handbook for Systematic Reviews of Interventions*. Version 5.1.0 [updated March 2011]. The Cochrane Collaboration; 2011.
12. Preoteasa CT, Preoteasa E. Compound odontoma-morphology, clinical findings and treatment. Case report. *Rom J Morphol Embryol.* 2018; 59(3): 997-1000. PubMed PMID: 30534846.
13. Bhagwat A, Barpande S, Bhavthankar J, Mandale M, Humbe J, Singh P. Odontogenic tumors: Review of 127 cases in Marathwada region of Maharashtra. *J Oral Maxillofac Pathol.* 2017; 21(3): 457. PubMed PMID: 29391730.
14. Popović A. Odontomi [Odontomas]. *Stomatol Glas Srb.* 1974 May-Jul;21(3):189-91. Croatian. PMID: 4535184.
15. Isola G, Cicciù M, Fiorillo L, Matarese G.

Association Between Odontoma and Impacted Teeth. J Craniofac Surg. 2017 May;28(3):755-758. doi: 10.1097/SCS.0000000000003433.

16. Buyukcavus MH, Satir S, Ozel S. Evaluation of dentofacial asymmetry caused by odontomas using panoramic radiographs. Niger J Clin Pract. 2020 Mar;23(3):291-297. doi: 10.4103/njcp.njcp_251_19.

17. Elsayed LK, El Khateeb SM, Alzahrani SA, ALHarthi SS, Ba-Hattab R. Case Report: An association of the gubernacular canal, supernumerary tooth and odontoma with an impacted canine on cone-beam computed tomography. F1000Res. 2020 Oct 6;9:1204. doi: 10.12688/f1000research.26627.2.

Acknowledgement

Nil.

Funding

Not applicable.

Data sharing statement

No additional data are available.

Conflict of interest

The authors declare no conflict of interest.

About the License

© The authors (s) 2021. The text of this article is open access and licensed under a Creative Commons Attribution 4.0 International License.