

## 68. HYPERTENSION AS A RISK FACTOR FOR STROKE

Mihaluta Valentina, Soroceanu Ala, Lisnic Tatiana

Academic adviser: Grib Liviu, M.D., Ph.D., Professor, Cardiology Department, State University of Medicine and Pharmacy "Nicolae Testemitanu", Chisinau, Republic of Moldova

**Introduction:** Uncontrolled high blood pressure increases a person's stroke risk by four to six times. Over time, hypertension leads to atherosclerosis and hardening of the large arteries. The risk of stroke is directly related to how high the blood pressure is.

**Case presentation:** The patient X 63 years old, women hospitalized in Holy Trinity with Clinical *Diagnosis:* Left hemisphere stroke with mild right hemiparesis. Motor dysphasia. Arterial hypertension III degree, very high additional risk. Ischemic heart disease. Stable angina pectoris functional class II. Heart Failure II NYHA. Diabetes mellitus type II.

*Complaints at the admission:* Limitation of movements in the right hand and leg, speech disorders, memory disturbances, general weakness.

*History of current disease:* She is considered hypertensive for 10 years, she followed regular medical treatment. On March 7, morning when she woke up, she felt a general weakness, dizziness, lost of consciousness for a short period of time.

*Hereditary history:* aggravated (mother suffered from hypertension, died of ischemic stroke).

*Medical history:* hypertension for 10 years, diabetes mellitus type II-7years.

*Objective data:*

General condition of medium gravity;

Body mass index (BMI) = 36.98-obesity class 2(G = 90 kg, T = 156 cm).

Cardiovascular: auscultation of heart sounds rhythmic, attenuate, with noise II aorta.

Blood pressure – 180/80 mmHg on left hand, 175/80 mm Hg on right hand.

SCORE Index – risk of developing a cardiovascular event in the next 10 years is 6.5%.

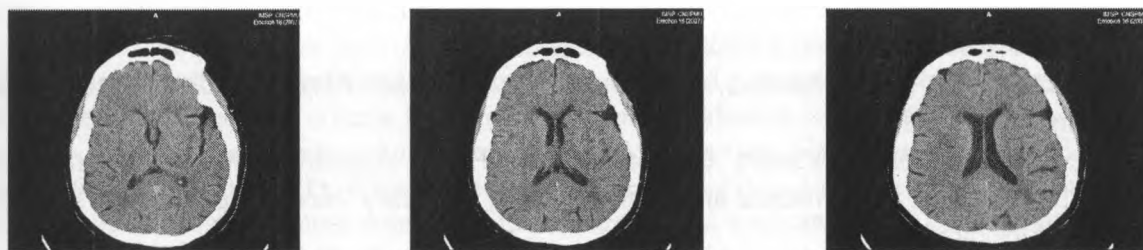
Mini Mental State Examination severe cognitive impairment (19 points).

*Neurological examination:*

- asymmetric face;
- swallowing preserved;
- deviated to the right tongue;
- right-mild hemiparesis, hypotonia;
- pathological reflexes: Babinski sign positive on right side.

*Investigations and laboratory results:*

- Biochemical analysis of blood – total cholesterol-7 mmol/l;
- ECG: sinus rhythm, heart rate=72, intermediate axis, left ventricular hypertrophy.
- Head Computed Tomography scan:



**CT conclusion:** stroke in the middle cerebral artery territory, extinguishing expansion in the periventricular white matter and semiovali centers.

**Discussion:** Major risk factor is the patient's uncontrolled hypertension values. Patient's other cardiovascular risk factors: diabetes mellitus type II, women age over 60, dyslipidemia, obesity, stress.

**Conclusion:** Stroke is a serious problem that has a multitude of causative global risk factors. A large percentage of strokes can be prevented if risk factors are known and closely monitored. Reducing the incidence of stroke requires prevention and management of changeable risk factors.

**Keywords:** Cognition, risk factor, stroke