

# We are IntechOpen, the world's leading publisher of Open Access books Built by scientists, for scientists

5,800

Open access books available

142,000

International authors and editors

180M

Downloads

Our authors are among the

154

Countries delivered to

TOP 1%

most cited scientists

12.2%

Contributors from top 500 universities



WEB OF SCIENCE™

Selection of our books indexed in the Book Citation Index  
in Web of Science™ Core Collection (BKCI)

Interested in publishing with us?  
Contact [book.department@intechopen.com](mailto:book.department@intechopen.com)

Numbers displayed above are based on latest data collected.  
For more information visit [www.intechopen.com](http://www.intechopen.com)



# Hydroa Vacciniforme-Like Cutaneous T-Cell Lymphoma

*Carmen Ximena Gallegos Riofrio  
and Juan Daniel Garzon Gallegos*

## Abstract

Hydroa vacciniforme (HV)-like cutaneous T-cell lymphoma (HVLL) is a controversial skin pathology because some cases appear as hydroa vacciniforme, whereas others progress to cutaneous T-cell lymphoma with or without angiocentricity. It is usually associated with infections of Epstein Barr viruses and NK-cell lymphomas and typically affects the pediatric population. Symptoms include facial edema, papules, vesicles, and blisters in the facial region, arms, legs, and areas exposed to sunlight that leave varioliform scars. There may be infiltration of the lips, eyelids, and nose, usually accompanied by comorbid infections and hypersensitivity to insect bites. Frequency is rare, but HVLL more commonly affects patients from South America and Asia. Its clinical management can be difficult and accompanied by a high index of malignancy, thus early diagnosis is essential for effective and timely management.

**Keywords:** hydroa vacciniforme, T-cell cutaneous lymphoma, angiocentric lymphoma, nasal-type NK lymphoma, varioliform scars

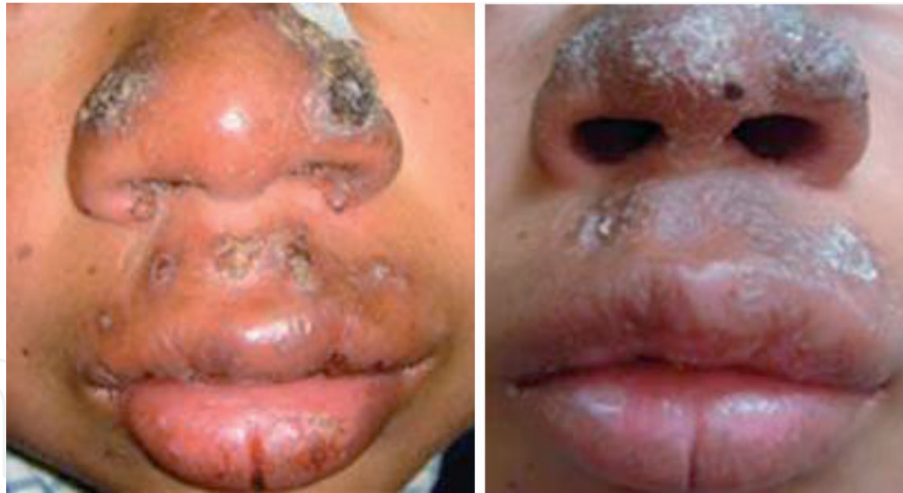## 1. Introduction

*Hydroa vacciniforme-like lymphoma* (HVLL) has an uncommon presentation that appears in young patients, especially those of Asiatic or indigenous race. It mimics the clinical profile of hydroa vacciniforme (HV) belonging to a special subtype of T-cell cutaneous lymphoma characterized by extreme photosensitivity with appearance of vesicles in the facial region that leave varioliform scars.

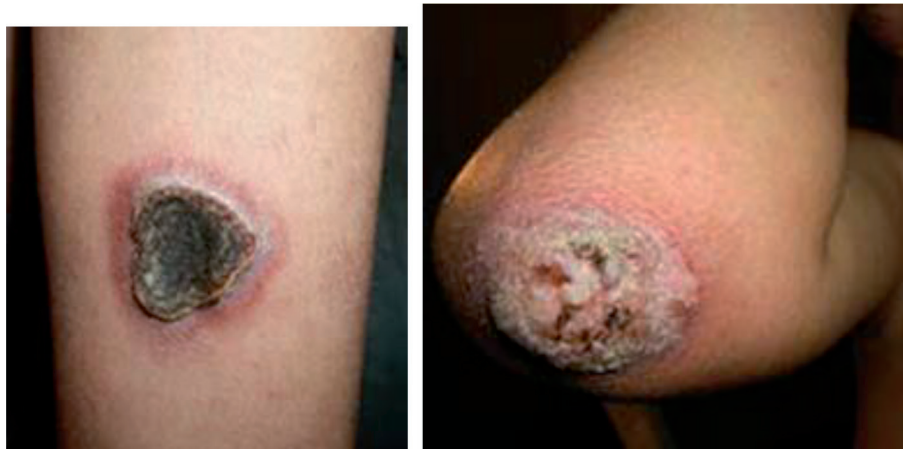Several authors have studied this pathology in depth and despite presenting a great diagnostic difficulty due to nonspecific clinical findings and histopathology, it has been concluded with the help of immunohistochemistry that HVLL corresponds to a true T-cell lymphoma with its own characteristics that is very difficult to recognize and requires effective treatment to avoid fatal results since it can demonstrate high lethality.

## 2. Discussion

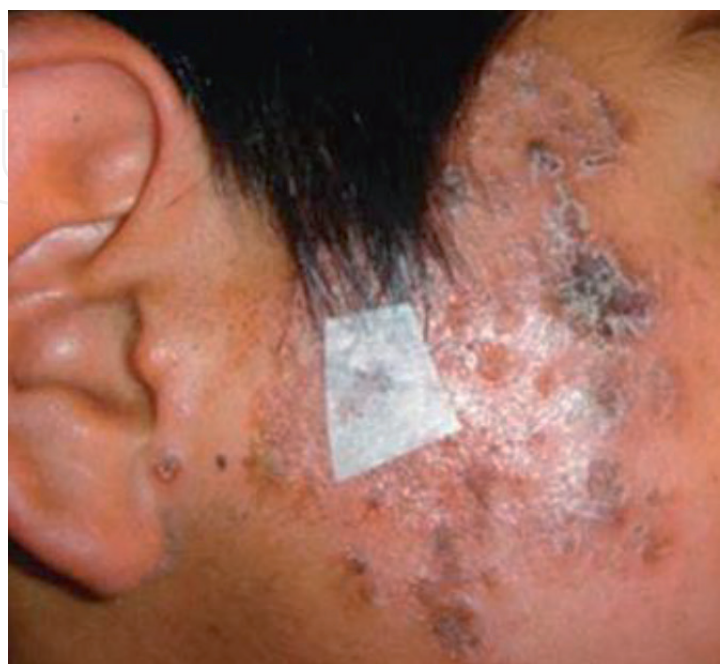In 1995, Ruiz Maldonado et al. described an entity called “edematous scarring vasculitic panniculitis” in pediatric patients. It resembled hydroa vacciniforme (HV) clinically, but the researchers considered it more of a malignant evolution [1].



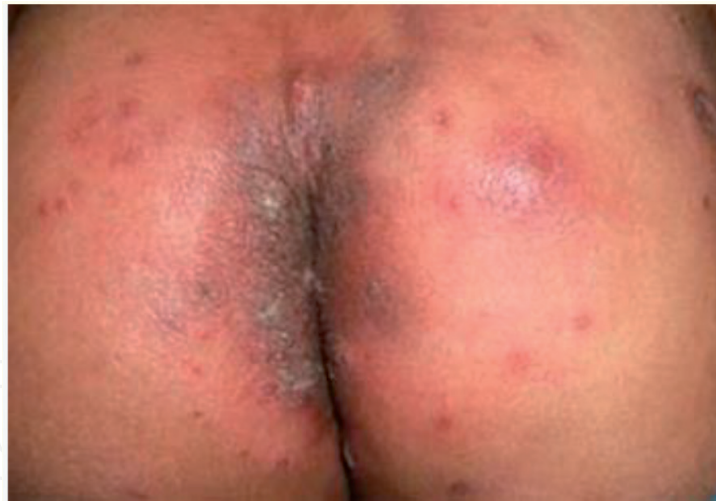**Figure 1.**  
*Edematous and infiltrating ulcerocrostrous lesions on the lip and nasal pyramid.*



**Figure 2.**  
*Ulcerative plate covered with necrotic crust and erythematous halo on the forearm and ulcerative keratotic plate on the elbow.*



**Figure 3.**  
*Eroded and crusty lesions on cheeks.*



**Figure 4.**  
*Ulcerated and suppurative nodules on the buttocks.*

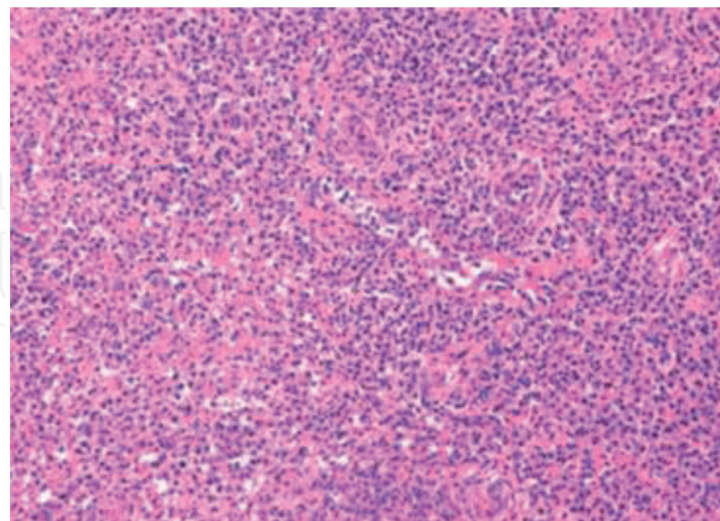
Those who suffer from this dermatosis manifest facial edema and recurrent outbreaks of papules, infiltrate and erythematous nodules, vesicles, blisters, ulcers, skin necrosis, and scabs that leave varioliform scars (**Figures 1–4**). These injuries occur on the face, back of the hands, arms, and legs, in areas both exposed and not exposed to sunlight. These injuries are accompanied by fever, asthenia, weight loss, hepatosplenomegaly, lymphadenopathy, and increased lactate dehydrogenase (LDH) level. High fever has been associated with hypersensitivity to insect bites [2–4]. At present, HVLL is considered within the spectrum of lymphoproliferative disorders (LPDs) of Epstein-Barr virus (EBV)-positive T cells in childhood [5]. Accumulating evidence indicates that these skin disorders could be of the T-cell/natural killer (NK)-type [2, 6, 7], are difficult to diagnose, and have a high rate of malignancy and resistance to chemotherapeutic agents (**Table 1**) [5, 8–12]. HVLL is a rare EBV+ NK variant/T-cell lymphoma, most seen in Central and South America. The illness shows a predilection for young adults and children. Often the disease runs a long course leading to an aggressive phase (concurrent infections and diseases). Histologically, an atypical small-to-medium-sized lymphocyte infiltrate with nuclei-dense chromatin and/or central necrosis is observed, especially of T cells throughout the skin. Exocytosis, necrotic epidermis (**Figures 5–7**), and lobular or septal panniculitis and vasculitis, usually with angiocentricity, are also present. On occasion, numerous reactive cells such as eosinophils, plasma cells, and histiocytes. It may be associated with pseudoepitheliomatous hyperplasia [13].

Although differential diagnosis may be difficult, cutaneous NK-cell lymphoma, mycosis fungoides (MF), subcutaneous panniculitis-like T-cell lymphoma, precursor T-cell lymphoblastic lymphoma, peripheral T-cell lymphoma, and cutaneous anaplastic lymphoma of large cells should be considered. HVLL can be confused with leishmaniasis, syphilis, tuberculosis, paracoccidioidomycosis, and other deep mycoses such as rhinosporidiosis or mucormycosis. It is important to differentiate it from hepatocutaneous porphyrias, erythropoietic protoporphyria, light polymorphic eruption, actinic prurigo, and lupus erythematosus (**Table 2**) [14].

The 2016 revision of the World Health Organization classification of lymphoid neoplasms is used to diagnose lymphomas (**Table 1**) [3, 15]. In lymphomas derived from T and NK cells, major modifications in classification continues to be a challenge. Anaplastic large cell lymphoma (ALCL) negative can already be reliably differentiated from other CD30-positive T lymphomas; genetic studies allow viewing of prognostic heterogeneity and category lymphoma—the TP63 mutation being notable for its bad outcome and rearrangement of 6p25 for its best forecast. Primary

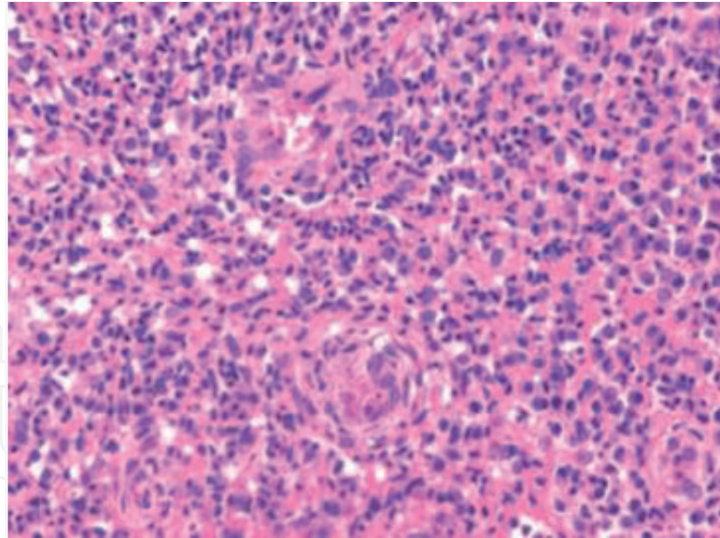
Classic presentations	Mycosis fungoides Sézary syndrome
Lymphoproliferative disorders	Childhood EBV1 T-cell systemic lymphoma Hydroa vacciniforme (HV) lymphoproliferative disorder
Rare and aggressive forms	Adult T-cell leukemia/lymphoma Nasal-type extranodal T/NK cell lymphoma
Lymphomas associated with gastrointestinal pathology	T-cell lymphoma-associated enteropathy Monomorphic intestinal epitheliotropic T-cell lymphoma Indolent T-cell lymphoproliferative disorders of the gastrointestinal tract Hepatosplenic T-cell lymphoma
Panniculitis	Subcutaneous T-cell lymphoma resembling panniculitis
Others	Primary cutaneous CD301 T-cell lymphoproliferative disorders Lymphomatoid papulosis Primary cutaneous anaplastic large cell lymphoma Primary cutaneous gd T-cell lymphoma Cutaneous epidermal primal cytoplasmic T lymphoma CD81 Primary cutaneous CD81 T-cell lymphoma Primary cutaneous lymphoproliferative disorder of CD41 T lymphocytes Peripheral T-cell lymphoma NOS Angioimmunoblastic T-cell lymphoma Follicular T-cell lymphoma Peripheral T-cell lymphoma with TFH phenotype Anaplastic large cell lymphoma, ALK1 Anaplastic large cell lymphoma, ALK2

**Table 1.**  
*Classification of mature, histiocytic, and dendritic lymphoid neoplasms (WHO, 2016 revision).*



**Figure 5.**  
*Atypical lymphoid infiltrate.*

cutaneous lymphomas correspond to a heterogeneous group of lymphocytic neoplasms with characteristic clinical, histological, immunophenotypic, and specific genetics [16]. Cutaneous T-cell lymphoma is recognized as a neoplastic process with clonal malignant T cells leading to regional and sometimes visceral lymph node metastasis [17, 18].



**Figure 6.**  
*Abundant infiltration of malignant atypical lymphocytes.*

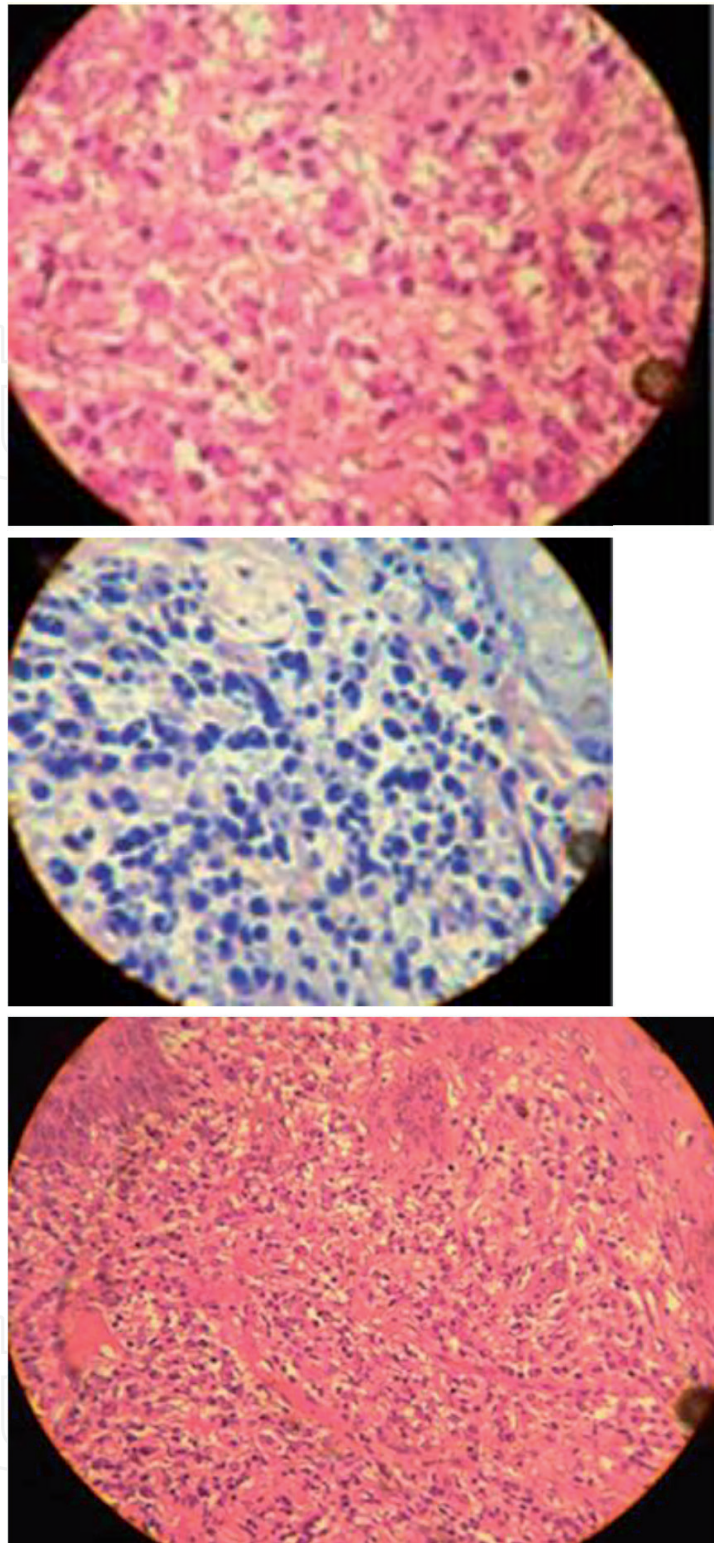
A often originate from CD4+ T cells, such as mycosis fungoides (MF), generally indolent in the behavior, [18, 19] and Sézary syndrome (SS), an aggressive variant; comprise about 53% of all cutaneous lymphomas. MF almost always affects older people, with a median age at diagnosis of 55–60 years old and a male-to-female ratio of 2:1. However, it can also be seen in populations of younger people, including children. Most patients (70%) are white, with Blacks, Hispanics, and Asians representing 14%, 9%, and 7% of MF cases in the United States, respectively [3].

Sometimes rarer forms of cutaneous lymphomas, such as HVLL, can disfigure anatomical structures and cause secondary infections if there are ulcers. The lesions have a complex immune environment; recent clinical data suggest that the presence of CD8+ T cells may be correlated with a better prognosis, whereas detection of macrophages is associated with a poor prognosis [20, 21].

Given advances in tumor biology, changes have been made to many of the lymphoma classification categories [3]. In the *International Classification of Diseases, 10th Revision* (ICD-10), codes C81–C96 categorize malignant neoplasms of lymphoid, hematopoietic and related tissue [22]. Nasal-type extranodal NK/T lymphomas are a rare aggressive form of primary cutaneous lymphoma that show strong expression of CD56 and cytotoxic proteins such as perforin, granzyme B, or TIA-1. The TCR/CD3 complex is not expressed on the surface. The episodic episomal presence of EBV is typically found. Angiocentric and angiodestructive growth is observed, resulting in necrosis and ulceration. Mitoses are common. In a Peruvian series of 16 patients, 10 died in an average of 11.6 months. There are few current reports on cutaneous EBV+ NK/lymphoid T-cell proliferations that are phenotypically different or clinically unusual, both in classic NK-/T-cell lymphoma as in the nasal type and in HVLL, suggesting that the spectrum of these conditions could be broader [13, 23].

Most cases have a CD81 T-cell lymphocyte phenotype; a small proportion of cases have an NK-cell phenotype. Only rare cases of CD41 T cells have been described. Lymphoid cells are positive for cytotoxic markers such as granzyme B and T-cell intracellular antigen 1 (TIA-1); CD30 expression is found in some reported cases [2, 24].

Since the incorporation of HVLL into the WHO's classification of lymphomas, some controversies have arisen that have yet to be clarified. It is not known whether HVLL represents a true lymphoma or a preneoplastic disorder with risk of



**Figure 7.**  
*Histopathological images with abundant lymphoplasmacytic infiltration.*

developing into systemic lymphoma. It is also uncertain whether HVLL is a de novo disease or develops with long-term HV disease [2, 24].

Studies in Asian populations showed that “classic” HV is also associated with EBV, thus it was proposed to include HV as part of the spectrum of chronic, active EBV infection. However, it is not clear whether what has been called “classic” HV in Asian populations corresponds to the same disease described in Western populations and Mexico where the disease is self-limited and no progression to HVLL has been observed. This discrepancy has contributed to

Age of onset		Evolution	Cells involved
Lymphoid pathologies			
Cutaneous NK cell lymphoma	Adult	Aggressive	CD2+, CD3+/-, CD56+, CD8+/-
Mycosis fungoides	Adult	Torpid	CD2+, CD3+, CD4+, CD8-
Cutaneous T-lymphoma resembling subcutaneous panniculitis	Adult	Aggressive	CD3+, CD4-, CD8+TIA1+
Precursor T-cell lymphoblastic lymphoma	Adult	Aggressive	CD3+/-, CD7+, CD4+/-, CD8+/-, TdT+
Peripheral T-cell lymphoma	Childhood	Aggressive	CD2+, CD3+, CD4+, CD8-
Cutaneous anaplastic large cell lymphoma	Adult	Torpid	CD3+, CD4+, CD30+, EMA-, ALK1-, TIA1+/-
Cutaneous hydroa vacciniform T-cell lymphoma	Childhood	Aggressive	CD2+, CD3+, CD56-, CD8+, TIA1+, CD30+/-
Nonlymphoid pathologies			
Infectious pathologies	Syphilis Tuberculosis Paracoccidioidomycosis Leishmaniasis Rhinosporidiosis Mucormycosis		
Cutaneous porphyrias	Erythropoietic protoporphyria Congenital erythropoietic porphyria Porphyria cutanea tarda Hepatoerythrocytic porphyria Hereditary coproporion Porphyria variegata		
Autoimmune pathologies	Lupus erythematosus		

**Table 2.**  
*Differential diagnoses of HVLL.*

uncertainty in differential diagnosis between classic HV and HVLL. It has been proposed that the most useful criterion for separating these two entities is the monoclonality of TCR.2 genes. Accumulating evidence indicates that these two cutaneous disorders could represent different manifestations within the spectrum of those encompassed under the setting of chronic, active infection by type-T EBV/NK [14, 15].

A study of severity in 20 Mexican children revealed that HV-type LPD of EBV1, regardless of the presence or absence of systemic symptoms of skin lesions, is a monoclonal T- and/or NK-cell disorder with a broad clinical spectrum, prolonged clinical course, and long-term risk of progressing to a systemic lymphoma. Later work showed that these lesions often have monoclonal rearrangements of TCR genes; thus the term "*hydroa vacciniforme-like lymphoma*" was proposed [2]. The relatively long clinical course before patients sought medical attention (range: 1–5 years) underlines the nature of this chronic disorder.



Apparently, monoclonality and clonal persistence are not predictive of aggressive disease or a progressive clinical course. Kimura et al. [4] reported four cases of "classic" HV, defined as patients with a characteristic dermatosis without systemic symptoms or cellular atypia, which were reclassified as having HVLL based on the monoclonality of the TCR-g genes. This suggests that EBV1 HV often is monoclonal, regardless of the presence or absence of systemic symptoms. Furthermore, no difference in the number of EBER1 infiltrators among these disorders has been found.

The Alpha and Beta or Gamma Cell Controversy and delta2 could be related to racial differences or reflect EBV-infected cells in peripheral blood and the skin. All HVLL cases revealed a phenotype of NK cells [4], indicating that one third of all HVLLs are from NK phenotype cells, which is more than has been observed before.

Morphologically, these lesions can mimic subcutaneous panniculitis-like T-cell lymphoma (SPTCL), primary cutaneous gamma and delta T-cell lymphoma, or skin involvement by extranodal NK/T lymphoma of nasal-type cells. Without clinical information, diagnosing the latter is almost impossible because the morphology and phenotype of the cells that infiltrate EBV1 are indistinguishable. Patients with the NK-cell phenotype rarely present with systemic symptoms despite alarming histology. Consequently, these patients show a relatively indolent clinical course compared to those with a T-cell phenotype [2, 3]. For any other authors, patients with an NK-cell phenotype appear have an increased risk of developing systemic lymphoma [13]. The severity of the clinical picture has been proposed to predict progression to systemic disease.

Some of those diagnosed with severe HV developed NK-/T-cell lymphoma 2–14 years after onset of the disease. It should be noted that all cases were associated with NK-cell lymphocytosis, HMB, and/or hemophagocytosis. "Subcutaneous lymphomas" without further specification raise the possibility that these injuries represent more manifestations of the disease and not a progression of the same. Although HVLL is characterized by a proliferation of monoclonal T cells or NK cells, treatment remains uncertain. Chemotherapy and/or radiation therapy are of little or no benefit. Their effects are usually transitory and do not induce sustained remission [13]. In addition, patients seem to have a worse prognosis and shorter survival due to sepsis and liver failure, with only slight improvement of skin lesions. In contrast, immunomodulatory therapies (prednisolone, cyclosporine, interferon A, chloroquine, and thalidomide) can sometimes improve symptoms temporarily.

### **3. Conclusions**

HVLL is considered an EBV1 cutaneous T-cell lymphoma. This is based only on the demonstration of a proliferation of monoclonal T cells. However, its clinical evolution and relatively good response to immunomodulatory therapy challenge the concept of a lymphoma full malignant startup.

Criteria such as the presence of systemic symptoms, T-cell clonality, number of EBV1 cells, and/or infiltrate density do not help predict who will progress to systemic disease. To avoid aggressive treatment and the stigma of a lymphoma diagnosis, the term HV-like EBV1 lymphoma, which encompasses the different manifestations and clinical signs of HV-like skin lesions with EBV, both from T cells and NK cells, is preferable for clinical use. The challenge remains to identify morphological or clinical markers to predict which patients are or are not at risk of progressing to a systemic lymphoma [25].

We believe the best term for this pathology is hydroa vacciniforme like type cutaneous T- cell lymphoma (LCCTHV). LCCTHV is a rare disease that is more prevalent in low-income pediatric populations. It is difficult to diagnose, and its

clinical evaluation is vitally important for timely treatment due to its malignant potential and lethal prognosis. LCCTHVL is a diagnostic challenge, especially if it is not an entity well known to specialists; hence the importance of emphasizing its existence in Latin American countries and Asia where it is more prevalent, especially among young adults and children [1, 2, 5, 8, 10–12, 14], and in tropical locations where it could easily be mistaken for a infectious disease such as leishmaniasis, tuberculosis, syphilis, paracoccidioidomycosis, or some other deep mycosis.

Although this malignant lymphoproliferative entity is highly aggressive and difficult to diagnose, it has been studied and described by multiple authors. Early diagnosis is essential for planning effective treatment (e.g., chemotherapy) to improve patient survival. However, it is important to note that comorbidities and the high degree of malignancy of this cutaneous variant of lymphoma can lead to a fatal outcome.

### **Conflict of interest**

“The authors declare no conflict of interest.”

IntechOpen

### **Author details**

Carmen Ximena Gallegos Riofrio\* and Juan Daniel Garzon Gallegos  
Hospital Metropolitano, Quito, Ecuador

\*Address all correspondence to: [cxgr2004@yahoo.es](mailto:cxgr2004@yahoo.es)

### **IntechOpen**

© 2021 The Author(s). Licensee IntechOpen. This chapter is distributed under the terms of the Creative Commons Attribution License (<http://creativecommons.org/licenses/by/3.0>), which permits unrestricted use, distribution, and reproduction in any medium, provided the original work is properly cited. 

## References

- [1] Ruiz-Maldonado R, Parrilla FM, Orozco-Covarrubias ML, Ridaura C, Tamayo-Sánchez L, Duran-McKinster C. Edematous, scarring vasculitic panniculitis: A new multisystemic disease with malignant potential. *Journal of the American Academy of Dermatology*. 1995;**32**(1): 37-44
- [2] Quintanilla-Martinez L, Ridaura C, Nagl F, Sáez-de-Ocariz M, Durán-McKinster C, Ruiz-Maldonado R, et al. Hydroa vacciniforme-like lymphoma: A chronic EBV+ lymphoproliferative disorder with risk to develop a systemic lymphoma. *Blood*. 2013;**122**(18): 3101-3110
- [3] Jawed SI, Myskowski PL, Horwitz S, Moskowitz A, Querfeld C. Primary cutaneous T-cell lymphoma (mycosis fungoides and Sézary syndrome): Part I. Diagnosis: Clinical and histopathologic features and new molecular and biologic markers. *Journal of the American Academy of Dermatology*. 2014;**70**(2): 205.e1-16; quiz 221-222
- [4] Kimura H, Hoshino Y, Kanegane H, Tsuge I, Okamura T, Kawa K, et al. Clinical and virologic characteristics of chronic active Epstein-Barr virus infection. *Blood*. 2001;**98**(2):280-286
- [5] Durán-McKinster C, Ruiz-Maldonado R. Hidroa vacciniformelike o enfermedad de Ruiz Maldonado. *Dermatologia Revista Mexicana*. 2013;**57**(6):464-467
- [6] Kanazawa T, Hiramatsu Y, Iwata S, Siddiquey M, Sato Y, Suzuki M, et al. Anti-CCR4 monoclonal antibody mogamulizumab for the treatment of EBV-associated T- and NK-cell lymphoproliferative diseases. *Clinical Cancer Research*. 2014;**20**(19): 5075-5084
- [7] Florencia-Fernández M, Bettina-Cervini A, Chantada G, Pierini AM. Linfoma cutáneo de células T hidroa vacciniforme-like. *Archivos Argentinos de Dermatología*. 2013;**63**(6):219-225
- [8] Ramos RC, Cortez F, Quijano E, Carayhua D, Jiménez H, Rivera A. Linfoma tipo hidroa: Presentación de un caso. *Rev Soc Peruana de Dermatología*. 2011;**21**(3):126-129
- [9] Lim MS, de Leval L, Quintanilla-Martinez L. Commentary on the 2008 WHO classification of mature T- and NK-cell neoplasms. *Journal of Hematopathology*. 2009;**2**(2):65-73
- [10] Beltrán BE, Maza I, Moisés-Alfaro CB, Vasquez L, Quiñones P, Morales D, et al. Thalidomide for the treatment of hydroa vacciniforme-like lymphoma: Report of four pediatric cases from Peru. *American Journal of Hematology*. 2014;**89**(12):1160-1161
- [11] Maldonado-García CA, Beirana-Palencia A. Hidroa vacciniforme, revisión del tema. *Revista del Centro Dermatológico Pascua*. 2006;**15**(3):198-202
- [12] Wang RC, Chang ST, Hsieh YC, Huang WT, Hsu JD, Tseng CE, et al. Spectrum of Epstein-Barr virus-associated T-cell lymphoproliferative disorder in adolescents and young adults in Taiwan. *International Journal of Clinical and Experimental Pathology*. 2014;**7**(5):2430-2437
- [13] Kempf W, Kazakov DV, Kerl K. Cutaneous lymphomas: An update. Part 1: T-cell and natural killer/t-cell lymphomas and related conditions. *The American Journal of Dermatopathology*. 2014;**36**(2):105-123
- [14] Di Martino-Ortiz B, Barboza G, Moreno T, Valiente C, Buongermini A, Boggino H. Linfoma cutáneo tipo hidroa

vacciniforme. Desorden linfoproliferativo asociado a infección por virus del Epstein-Barr en la infancia. *Piel*. 2015;**30**(7):420-423

[15] Sorigue M, Sancho JM. The 2016 revision of the WHO classification of lymphoid neoplasms: The clinician's view. *Medicina Clínica (Barcelona)*. 2018;**150**(2):64-66

[16] Kempf W, Mitteldorf C. Pathologic diagnosis of cutaneous lymphomas. *Dermatologic Clinics*. 2015;**33**(4): 655-681

[17] Sawada A, Inoue M, Koyama-Sato M, Kondo O, Yamada K, Shimizu M, et al. Umbilical cord blood as an alternative source of reduced-intensity hematopoietic stem cell transplantation for chronic Epstein-Barr virus-associated T or natural killer cell lymphoproliferative diseases. *Biology of Blood and Marrow Transplantation*. 2014;**20**(2):214-221

[18] Hwang ST, Janik JE, Jaffe ES, Wilson WH. Mycosis fungoides and Sézary syndrome. *Lancet*. 2008; **371**(9616):945-957

[19] Dummer R, Urosevic M, Kempf W, Kazakov D, Burg G. Imiquimod induces complete clearance of a PUVA-resistant plaque in mycosis fungoides. *Dermatology*. 2003;**207**(1):116-118

[20] Kim EJ, Hess S, Richardson SK, Newton S, Showe LC, Benoit BM, et al. Immunopathogenesis and therapy of cutaneous T cell lymphoma. *The Journal of Clinical Investigation*. 2005;**115**(4): 798-812

[21] Sugaya M, Miyagaki T, Ohmatsu H, Suga H, Kai H, Kamata M, et al. Association of the numbers of CD163(+) cells in lesional skin and serum levels of soluble CD163 with disease progression of cutaneous T cell lymphoma. *Journal of Dermatological Science*. 2012;**68**(1):45-51

[22] Fritz A, Percy C, Jack A, Shanmugaratnam K, Sobin L, Parkin DM, et al. *International Classification of Diseases for Oncology*. 3rd ed. Malta: WHO; 2013. Available from: [http://apps.who.int/iris/bitstream/10665/96612/1/9789241548496\\_eng.pdf?ua=1](http://apps.who.int/iris/bitstream/10665/96612/1/9789241548496_eng.pdf?ua=1)

[23] Barrionuevo C, Anderson VM, Zevallos-Giampietri E, Zaharia M, Misad O, Bravo F, et al. Hydroa-like cutaneous T-cell lymphoma: a clinicopathologic and molecular genetic study of 16 pediatric cases from Peru. *Applied Immunohistochemistry & Molecular Morphology*. 2002;**10**(1):7-14

[24] Swerdlow SH, Campo E, Pileri SA, Harris NL, Stein H, Siebert R, et al. The 2016 revision of the World Health Organization classification of lymphoid neoplasms. *Blood*. 2016;**127**(20): 2375-2390

[25] Fauci AS, Haynes BF, Katz P, Wolff SM. Wegener's granulomatosis: Prospective clinical and therapeutic experience with 85 patients for 21 years. *Annals of Internal Medicine*. 1983; **98**(1):76-85