

# We are IntechOpen, the world's leading publisher of Open Access books Built by scientists, for scientists

5,800

Open access books available

142,000

International authors and editors

180M

Downloads

Our authors are among the

154

Countries delivered to

TOP 1%

most cited scientists

12.2%

Contributors from top 500 universities



WEB OF SCIENCE™

Selection of our books indexed in the Book Citation Index  
in Web of Science™ Core Collection (BKCI)

Interested in publishing with us?  
Contact [book.department@intechopen.com](mailto:book.department@intechopen.com)

Numbers displayed above are based on latest data collected.  
For more information visit [www.intechopen.com](http://www.intechopen.com)



# Exhaustion of Vascular Accesses for Haemodialysis: Access by Thrombosed Vein

*Arturo Rafael Vizcarra*

## Abstract

I will describe, especially to professionals involved in vascular access, how recently occluded veins can be recanalized to implant a haemodialysis catheter. We recommend that it be a permanent one.

**Keywords:** exhaustion, vascular accesses, haemodialysis, access, thrombosed vein

## 1. Introduction

The depletion of vascular accesses for haemodialysis is seen in some patients who reach this situation due to multiple causes [1, 2] such as procoagulant factors, lack of good management of their accesses, lack of resources, etc.

In these cases, the skills of the surgical team to respond must be technically sharpened.

When a patient is without vascular access and cannot dialyze, it is an extreme situation.

It is understood that a patient does not have vascular access when not even a catheter can be implanted to be able to dialyze.

That is, there is occlusion or inability to progress a catheter through the following veins:

1. Internal jugulars
2. External jugulars
3. Subclavian
4. Femoral

### 1.1 Options for implanting a catheter in these conditions

Where do wrong decisions bring bad results? The following options are the most common ones for implanting a permanent catheter. In some cases, this catheter can be connected to a prosthesis to make a fistula.

There are not many options to do this; some of the possible options are listed below:

- a. Translumbarpuncture of the inferior vena cava [3, 4]

- b. Direct puncture of the superior vena cava [5]
- c. Transliver puncture [6],
- d. Sternotomy or thoracotomy for direct access to the right atrium.

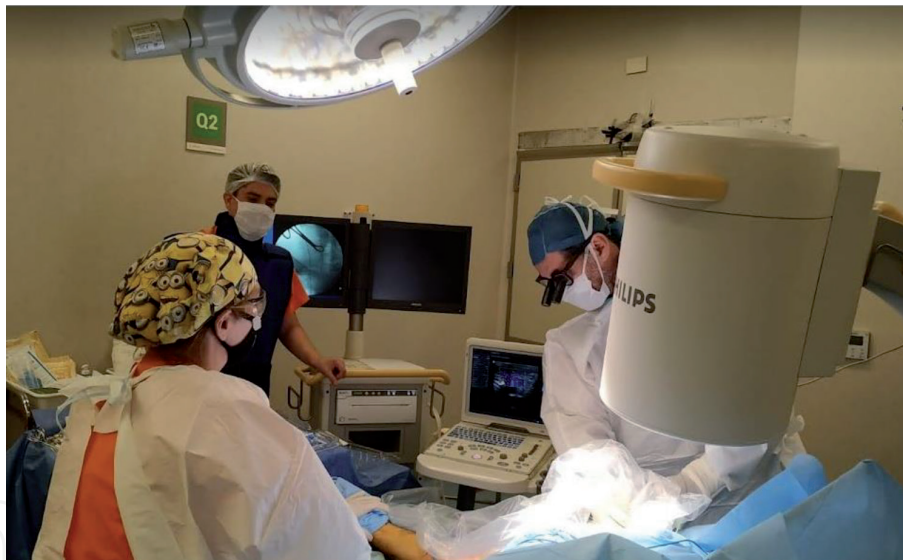All of these options are not the subject of this chapter.

## 2. Implant a catheter through a thrombosed vein

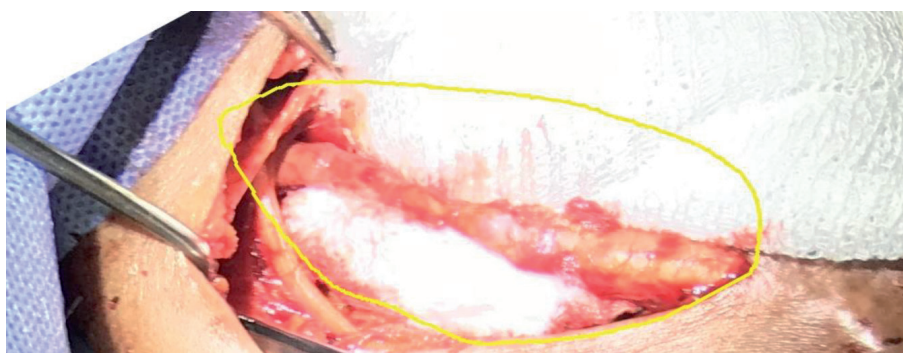
I recommend that these practices be done by a surgeon who often performs haemodialysis accesses, or by an operator in conjunction with a surgeon, so that if a complication occurs he/she can resolve it or use a different tactic.

There must be an operating room equipped with an echo doppler equipment, good quality fluoroscopy, specialised human resources, a variety of guide wires, catheters, dilators, and a complete set of cardiovascular surgery [7] (**Figure 1**).

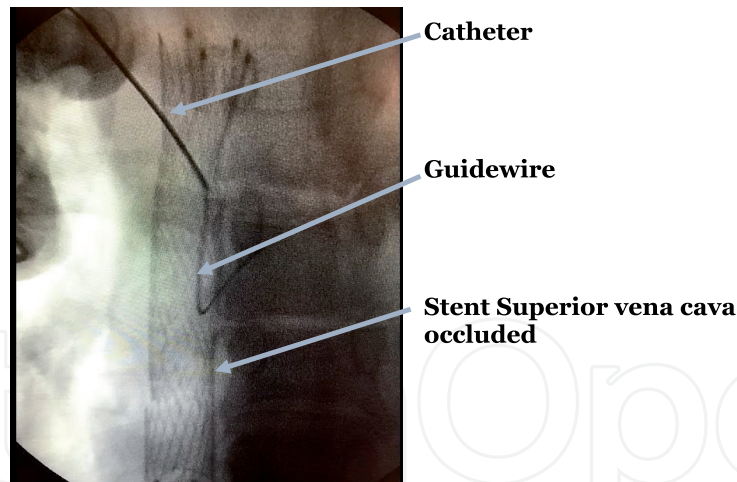
Given this situation and the fact that the patient is young, I implant catheters through any of the veins mentioned above, either because they have a central occlusion or because they are directly thrombosed throughout their entire course. Often I have been able to implant catheters in those with recent occlusion (**Figures 2–4**).



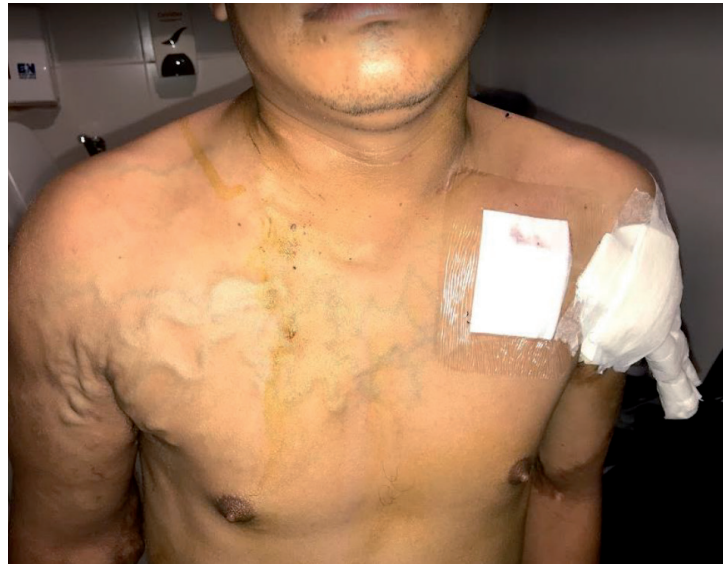**Figure 1.** Operating room, equipped with doppler echo, fluoroscopy, surgical fields, surgeon's assistants, complete surgical instruments.



**Figure 2.** Occluded vein, with long stenosis, dissected for the repair of an arteriovenous fistula for haemodialysis.



**Figure 3.**  
*Old occlusion of the superior vena cava with a stent also occluded, a guidewire, catheter and stent can be seen; it was not possible to pass; in this case, the femoral vein with recent occlusion is accessed.*



**Figure 4.**  
*This case of recent occlusion of the innominate vein and left subclavian could be passed. The right side shows abundant collateral venous circulation for a long-time occlusion.*

Occluded veins with a long time of evolution is usually fibrosed and it is difficult or impossible to cross with the guide wire.

### 2.1 I'm going to talk to you about this topic very specifically

These patients, usually in the superior veins, have had a stent placed, **Figure 3**, or an angioplasty done previously, which makes it even more difficult.

Less frequent in the lower limbs, which is reserved as a last option.

### 2.2 So what is the basis of puncturing thrombosed veins to be able to pass with a catheter?

The rationale is that veins, especially those recently occluded and therefore thrombosed, at some point have loose tissues, enough to pass with a wire guide, which can be helped with catheters or dilators.

The recent occlusion of the vein in arteriovenous fistulas in repair surgeries is shown. Through the small hole or loose tissue, seen in the images, the passage can

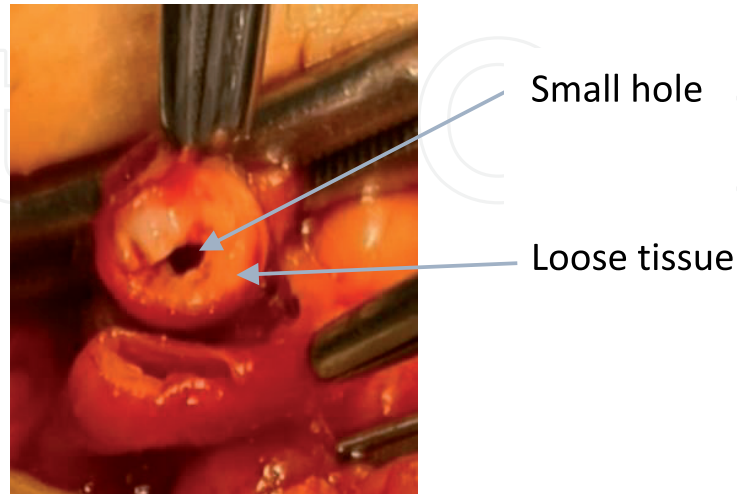


be opened to advance a guide wire and then a catheter when a thrombosed vein is punctured (**Figures 5–8**).

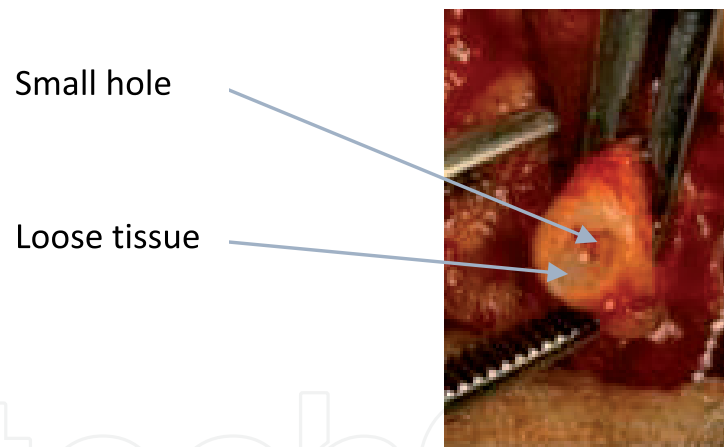
All manoeuvres must be done carefully.

In order to move forward, you have to take the time that is necessary.

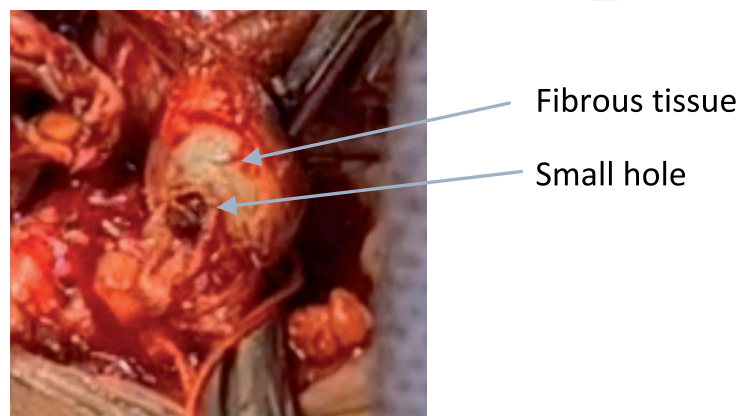
It is recommended that surgeons do this procedure, because if there is any complication at the moment that requires surgery, it can be solved by the operator himself.



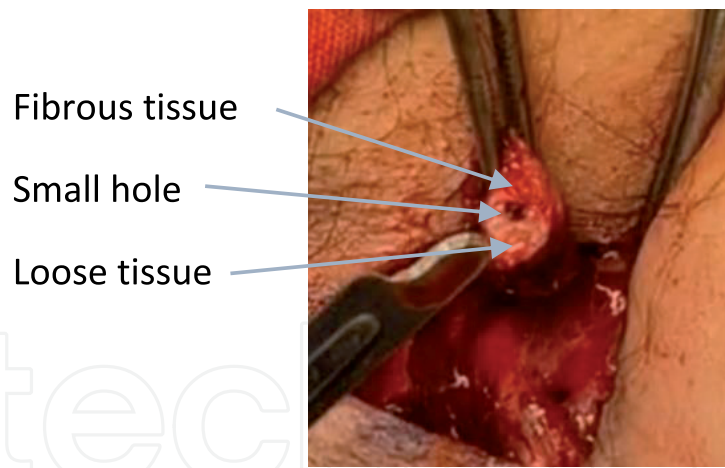
**Figure 5.**  
*Recently occluded basilica vein; in AVF repair; you can see that there is a small hole.*



**Figure 6.**  
*Recently occluded femoral vein; in AVF repair; you can see that there is a small hole.*



**Figure 7.**  
*Recently occluded axillary vein; in AVF repair; you can see that there is a small hole.*



**Figure 8.**  
*Recently occluded axillary vein; in AVF repair; you can see that there is a small hole.*

Or in case you need open surgery to pass the catheter, a surgeon's help is required.

### 3. Step-by-step explanation of the procedure

#### 3.1 First step

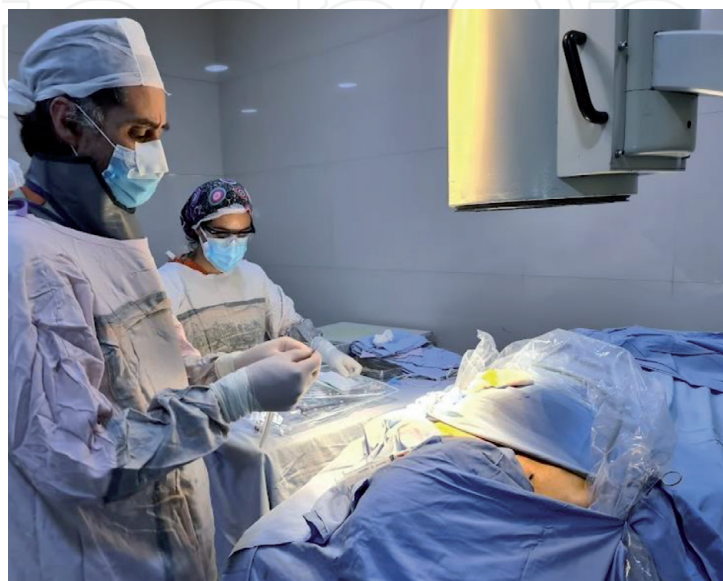Perform antisepsis, and surgical fields are placed as for any surgery in the areas that the surgeon considers (**Figure 9**).

#### 3.2 Second step

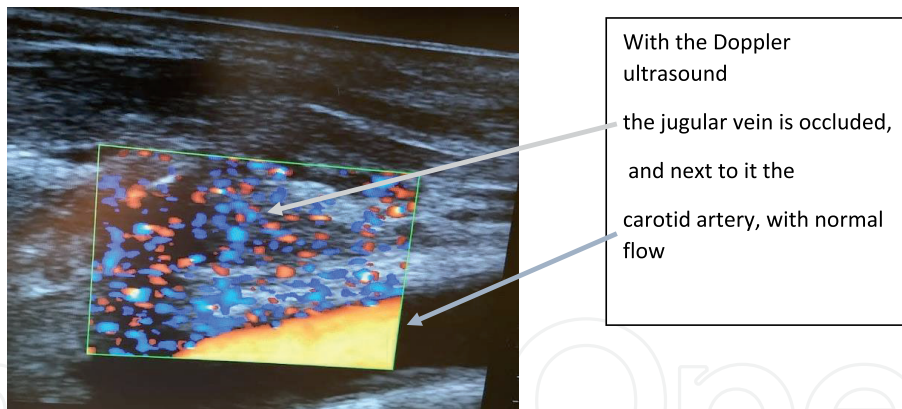
Puncture of the occluded vein guided by doppler ultrasound and positioning of the guide wire (**Figure 10**).

I prefer to puncture the vein in a place where it is as straight as possible to be able to pass the guide.

That is to say, I prefer to puncture the vein in the right internal jugular vein and both femoral veins, the left subclavian and jugular vein, we have the innominate



**Figure 9.**  
*All set to start, surgical drapes, fluoroscopy, and doppler ultrasound.*



**Figure 10.**  
*Doppler photo showing occlusion of the jugular above and orange carotid arterial flow below.*

vein curve, and for the right subclavia a curve of almost 90 degrees to enter the cava.

### 3.3 Third step

Introduce the needle guided by ultrasound, until it is certain that it is inside the vessel in the middle of the thrombosis. Then introduce a guide wire. Also this has to be verified by ultrasound (**Figure 11**).

### 3.4 Fourth step

Continue the progression of the guidewire under fluoroscopic control, testing the different types of guidewires, depending on the experience of the operator. In this step, it always helps to advance the guidewire with fine dilators.

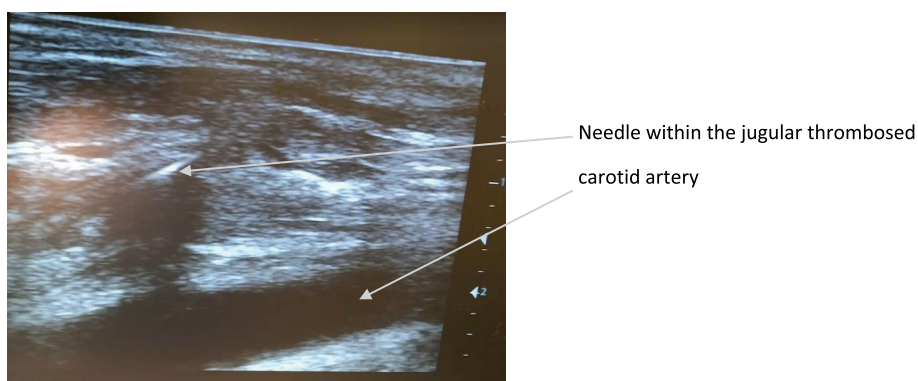
It also helped me by injecting contrast to see that anatomically we are in the correct direction inside the thrombosed vessel (**Figures 12–14**).

### 3.5 Fifth step

Once the guidewire is sent into the superior or inferior vena cava, and there are no more obstacles, gradually thicker dilators are advanced (**Figure 15**).

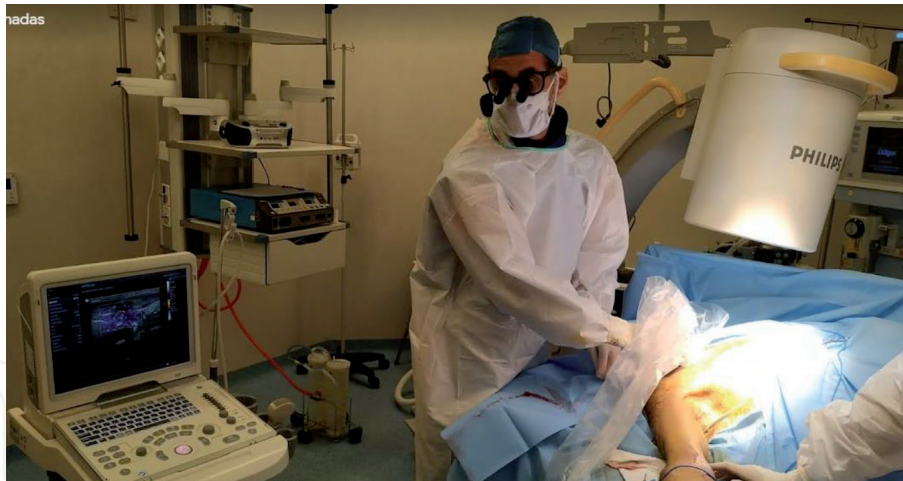### 3.6 Sixth step

The dilator is inserted with the sheath that corresponds to each catheter. Depending on the case, a double lumen catheter or two catheters are used.

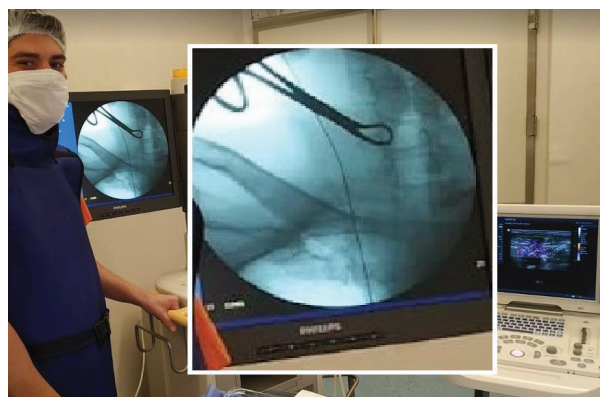

**Figure 11.**  
*Photo without doppler shows the needle inside the thrombosed jugular.*

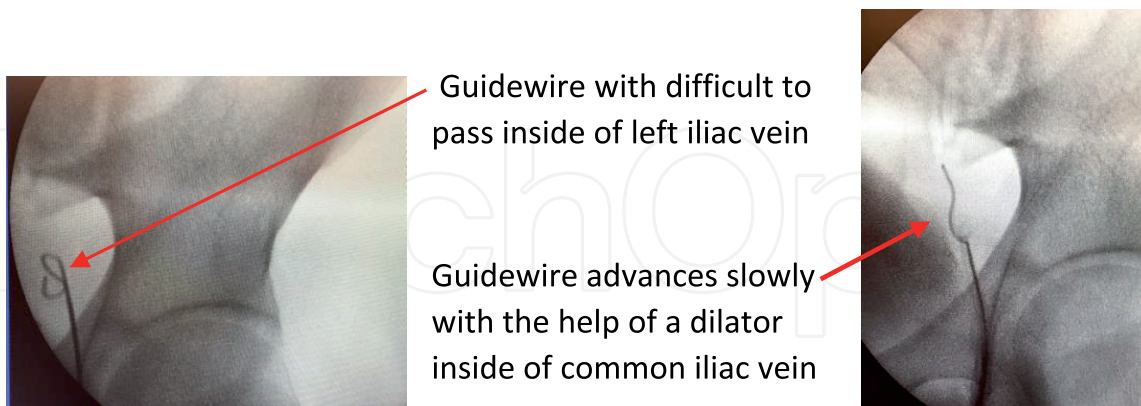




**Figure 12.**  
*Looking at the guidewire by doppler ultrasound and fluoroscopy at the same time.*



**Figure 13.**  
*The guidewire inside superior cava, arrows.*



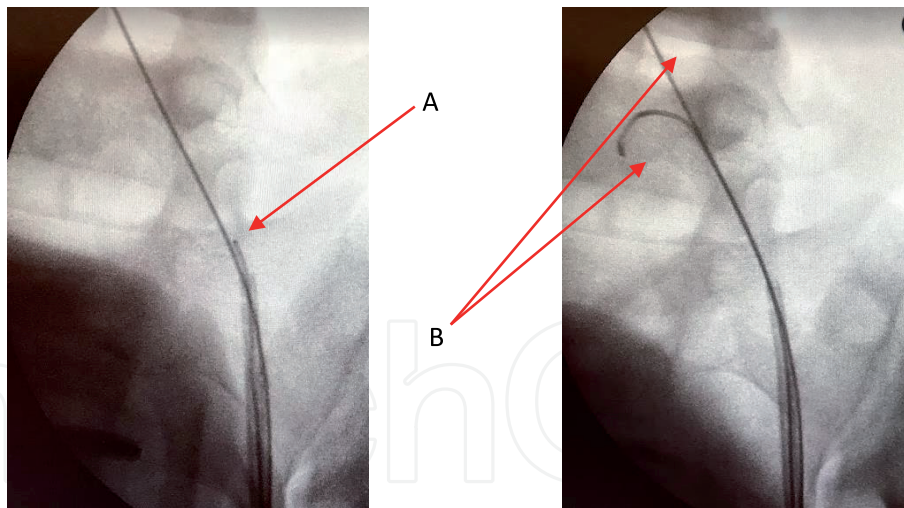
**Figure 14.**  
*Guidewire advances through the thrombosed iliac vein.*

It can happen that the catheters do not progress through the sheaths, because the strictures are very rigid.

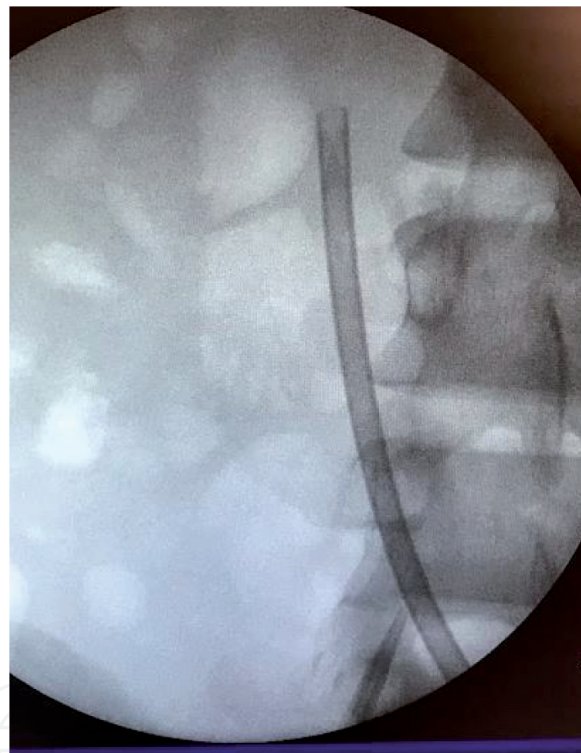
In that case I used thinner catheters inside the haemodialysis catheter. This step can be very cumbersome; so you also have to take it easy and use all your resources and skills to get the catheter where it needs to go (**Figures 16** and **17**).

Some brands of catheter brings thinner semi-rigid catheters for these cases, and they are inserted with 2 guide wires and 2 semi-rigid catheters, one for each lumen (**Figure 18**).

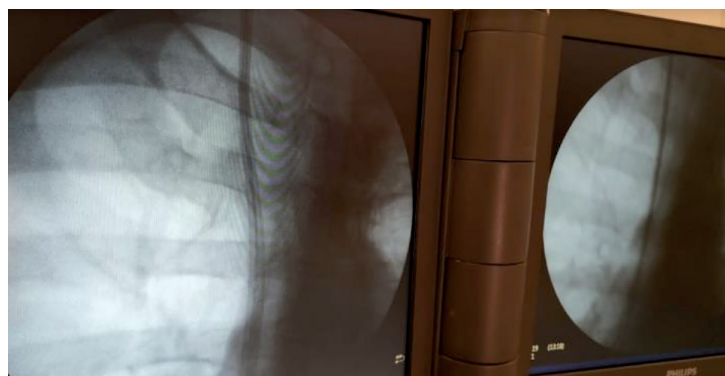




**Figure 15.**  
*A Once the guidewire is in the inferior vena cava, in this case, progressively thicker dilators are advanced B Sheath where 2 guide wires were passed.*



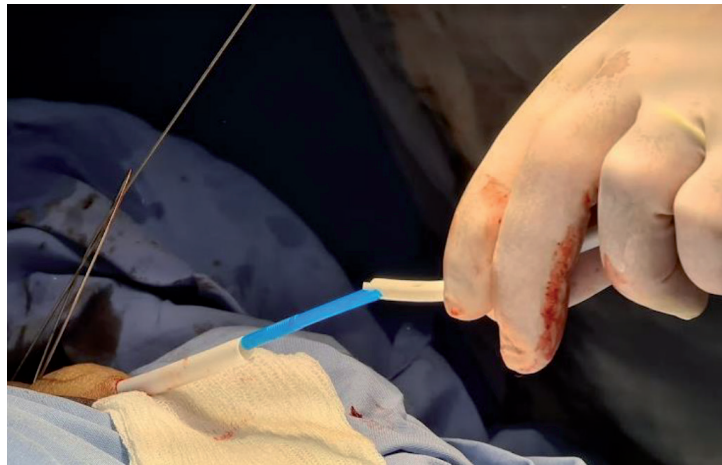**Figure 16.**  
*Double lumen catheter in inferior cava.*



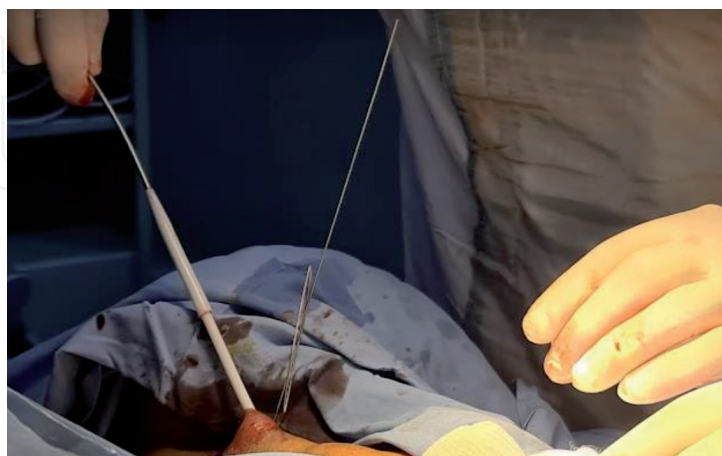**Figure 17.**  
*Double lumen catheter in right atrium by superior cava.*



**Figure 18.**  
*Catheter model with 2 semi-rigid catheters, which guide wires are passed inside, all this inside the 14 French double lumen catheter.*



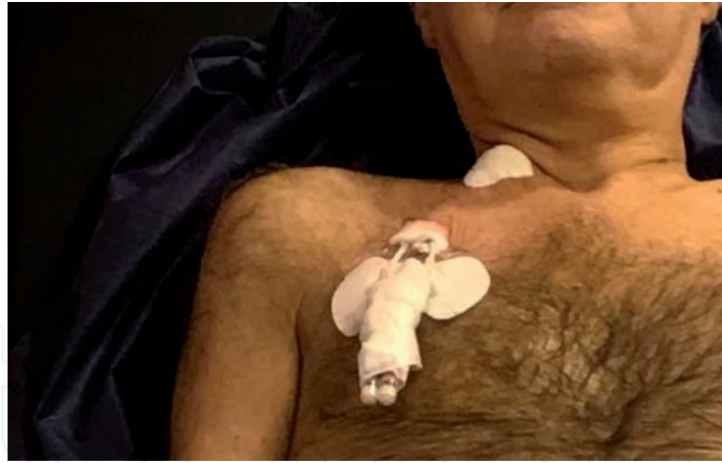**Figure 19.**  
*Tunnelling a double lumen catheter.*



**Figure 20.**  
*Tunnelling a double lumen catheter.*

### 3.7 Seventh step

The catheter is positioned and the corresponding tests are performed to obtain adequate flow; tunnelling is performed (Figures 19–21).



**Figure 21.**  
*In this case, we passed the kit of two catheters through the right jugular.*

More adequate tunnelling, either with a tunneller that comes with the kit, or with an incision of the necessary size, since some catheters must first be tunneled and then inserted; this is not possible in these cases because you have to push directly and not through a tunnel.

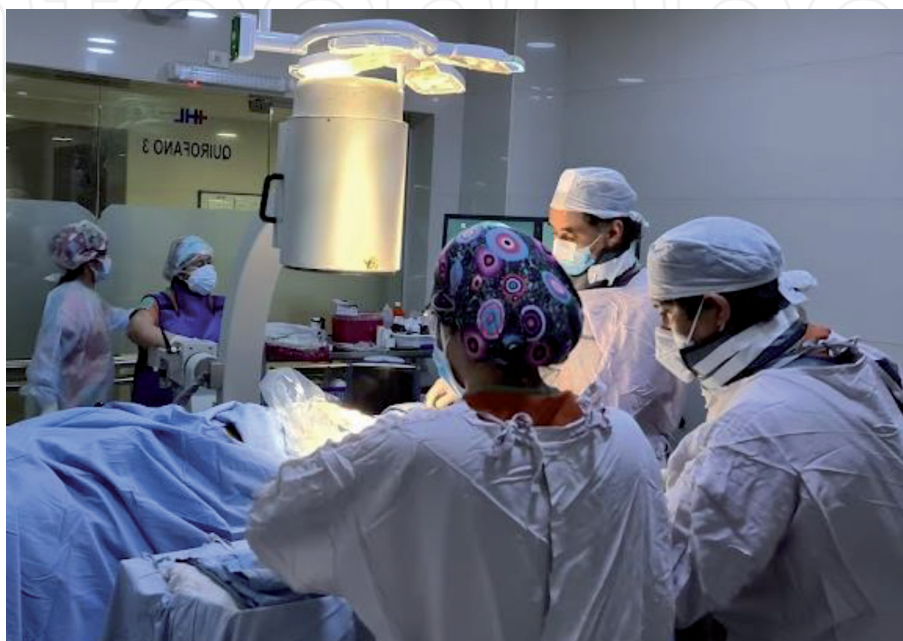#### **4. Continue with dialysis**

In this way, we can continue with dialysis on these patients, and it gives us time to perform an arteriovenous fistula somewhere.

#### **5. Conclusion**

It is not a quick procedure; it requires a lot of patience, previous planning, especially, questioning the patient about his history of vascular access, a meticulous physical examination, and rigorous examination with echo doppler.

Currently, we have several patients operated in this way; I consider it an acceptable technique to save lives with a procedure that until now has had no complications.



## **Acknowledgements**

To my Family who support me many and many hours in the operating room.  
To my colleagues who trust their patients in my hands.  
To patients who trust their lives in our hands.

## **Conflict of interest**

The authors declare no conflict of interest.

## **Notes**

All images are my property.

## **Author details**

Arturo Rafael Vizcarra  
Scire Cardiovascular SRL, Larcade Hospital, San Miguel, Buenos Aires, Argentina

\*Address all correspondence to: [avizcarra2@gmail.com](mailto:avizcarra2@gmail.com)

## **IntechOpen**

© 2021 The Author(s). Licensee IntechOpen. This chapter is distributed under the terms of the Creative Commons Attribution License (<http://creativecommons.org/licenses/by/3.0>), which permits unrestricted use, distribution, and reproduction in any medium, provided the original work is properly cited. 



## References

[1] Scher LA, Shariff S. Strategies for hemodialysis access: A vascular surgeon's perspective. *Techniques in Vascular and Interventional Radiology*. 2017;**20**(1):14-19. DOI: 10.1053/j.tvir.2016.11.002

[2] Su SH. Points to remember: Cardiovascular consequences of hemodialysis vascular accesses. *Methodist DeBakey Cardiovascular Journal*. 2014;**10**(3):202-203. DOI: 10.14797/mdcj-10-3-202.PMID

[3] Loskutov A, Dave A, Gooden C, Saucier NA, Cho KH, Wible BC, et al. Vascular access via translumbar hemodialysis reliable outflow dialysis catheter in a case of severe central venous occlusion. *Journal of Vascular Access*. 2018;**19**(4):410-411. DOI: 10.1177/1129729818762972

[4] Inston N, Khawaja A, Mistry H, Jones R, Valenti D. Options for end stage vascular access: Translumbar catheter, arterial-arterial access or right atrial graft? *Journal of Vascular Access*. 2020;**21**(1):7-18. DOI: 10.1177/1129729819841153

[5] Jeffrey HL, Niklason LE, Roy-Chaudhury P. Challenges and novel therapies for vascular access in haemodialysis. *Nature Reviews Nephrology*. 2020;**16**:586-602

[6] Gouda ZE, Emara MM, Elbarbary HS, Koura MAA, Elarbagy AR. Studying alternative approaches for placement of cuffed hemodialysis catheters in hemodialysis patients with bilateral internal jugular vein occlusion. *Journal of Vascular Access*. 2019;**20**(3):250-259. DOI: 10.1177/1129729818794414

[7] Vizcarra A, Hermida O. Exhaustion of vascular accesses for hemodialysis: access by thrombosed vein. *Revista de Nefrología, Diálisis y Trasplante*. 2020;**40**(02):179-182