

M. Schumacher
A. Berlis

The balloon retriever technique

M. Schumacher (✉) · A. Berlis
Department of Neuroradiology,
University of Freiburg,
Breisacher Strasse 64,
79106, Freiburg, Germany
E-mail: SCHU@nz.ukl.uni-freiburg.de
Tel.: +49-761-2705181
Fax: +49-761-2705195

Abstract We report a 50-year-old woman with a large supraophthalmic aneurysm. An attempt was made to treat this by endovascular occlusion of the distal internal carotid artery with coils but they could not be placed satisfactorily. During withdrawal a coil became stuck, stretched and finally detached inside the guiding catheter. It was salvaged easily with a balloon retriever technique. This seems to be a useful way to remove stretched coils.

Introduction

Interventional neuroradiologists need to have techniques and devices available for safe, effective emergency retrieval of intravascular material, e.g., for embolectomy or for removal of a foreign body. Several types of foreign body retrieving devices including forceps, baskets or snares have been developed for use in complications such as premature coil detachment, breakage or migration. However, not all situations can be managed using a snare, since it requires the object to have a free end or loop which can be captured. Such techniques are particularly unsuitable when part of a wire or coil lies within the microcatheter. For this situation a special balloon retriever technique has been developed and used successfully, as described below.

Case report

A 50-year-old woman presented with many years of headache and a large supraophthalmic aneurysm on the C1 segment of the internal carotid artery (ICA) (Fig. 1). A year prior to admission to

our hospital an attempt at combined endovascular and neurosurgical occlusion failed. On admission the patient was alert and the examination was normal. Digital subtraction angiography was performed (Fig. 1) with the intention to treat the patient by occluding the distal ICA. After well-tolerated temporary balloon occlusion under local anaesthesia, a microcatheter was positioned distal to the aneurysm under general anaesthesia. An attempt to place a 5 mm Guglielmi detachable coil was not satisfactory, and while trying to remove the coil it appeared to be stuck in the ICA. It progressively stretched, extending from its original site all the way to the femoral artery. With further traction the very stretched coil finally detached inside the microcatheter (Fig. 2). A small balloon (2 mm diameter, 10 mm long) was introduced after the microcatheter had been removed from the guiding catheter. Then the balloon catheter was advanced slowly and carefully into a position above the free end of the coil. The balloon was inflated and gently withdrawn, dragging the coil downwards (Fig. 2). When the coil was within the guiding catheter the whole system was removed. The patient tolerated the entire procedure well.

Combined microsurgical and endovascular treatment with clipping of the ICA proximal and distal to the aneurysm under temporary balloon occlusion was carried out 2 weeks later. Angiography immediately after the procedure showed complete occlusion of the ICA and the aneurysm. The patient had an incomplete left oculomotor and abducens palsies, with eventual recovery, but 2 years later had a persistent right homonymous hemianopia.

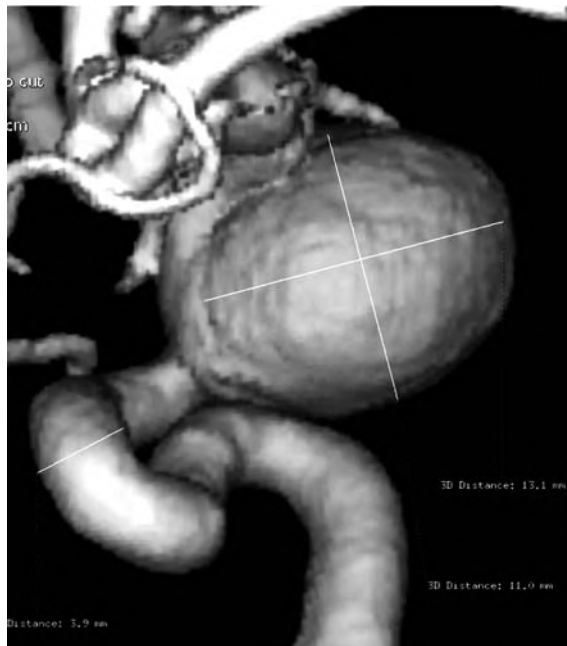

Fig. 1 Rotational 3D angiography showing a 11×13 mm internal carotid artery aneurysm. It was planned to treat the aneurysm by distal occlusion of the parent artery with coils

Discussion

With increasing use of endovascular techniques one must be aware of the potential for intravascular loss of foreign material [1]. Retrieval of broken coils is possible in most cases using an endovascular snare, as shown by Graves et al. [2]: in animal experiments only three of 33 attempts to retrieve a coil failed. Endothelial or subintimal damage due to manipulation of the snare was not looked for, but vasospasm was excluded angiographically. The loop snare modified by Smith et al. [3] has been widely used, whereas small forceps [4, 5] have not been miniaturised for use in small vessels. Flexible grasping forceps and gooseneck snares do not fulfill the requirements for a flexible system which can be used in cerebral arteries. For access to the ICA medium-size systems such as the High flex basket (Angiomed) with a 20 mm threefold opening system and the 2.4 F Microvasive-Segura basket (Boston Scientific) with an opening width of 16 mm allow more effective manipulation to draw foreign bodies into the catheter [6, 7, 8, 9]. More complicated techniques which require additional puncture of vessels of the neck have been proposed for situations when a stretched coil cannot be retrieved by standard devices [10]. However, relatively stiff instruments can make retrieval impossible, particularly when the stretched coil is not clearly

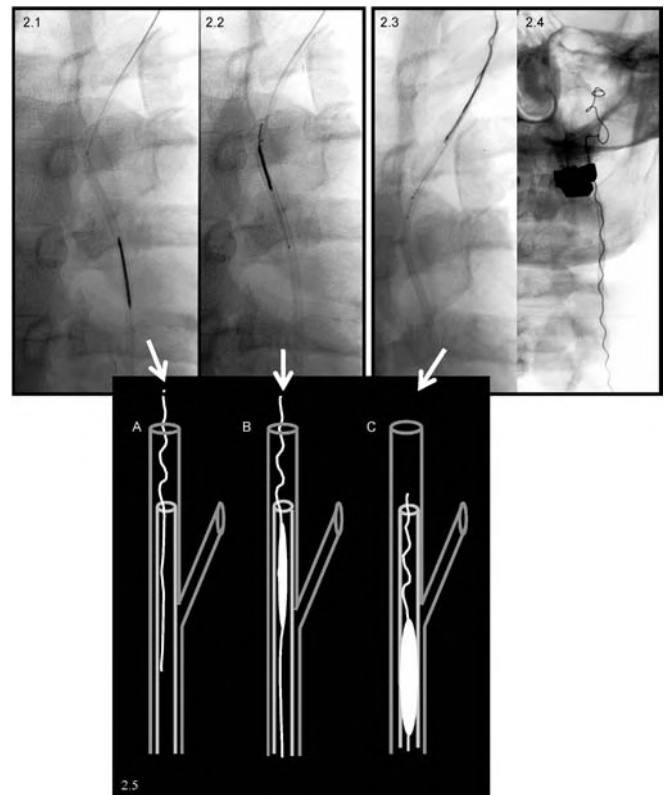


Fig. 2 Retrieval of the coil. **2.1** The free end (arrow) of the broken, stretched coil is visible in the guiding catheter. The microballoon catheter has been advanced close to the end of the coil. **2.2** The microballoon has reached the end of the coil and the microwire is pushed forward. **2.3** The microballoon has been inflated and moved upwards to test whether the coil is fixed by the balloon. The effect of this is manifest by the curve of the coil. **2.4** The coil has been withdrawn almost completely into the guiding catheter. **2.5A–C** Diagram of the procedure. **A** The stretched coil is detached, with its free end in the guiding catheter. The microcatheter has been removed. **B** The balloon retriever has been gently advanced distal to the free end of the coil and inflated. The ability to move the coil with pressure from the balloon is tested by sliding up and down. **C** Slow removal of the inflated balloon drawing the coil back into the guiding catheter

visible or is in contact with the vessel wall, which is often the case [10, 11].

If the stretched coil is inside the guiding catheter it can be fixed without manipulation at the vessel wall. For safe retrieval the coil should be fixed by the balloon as distally as possible inside the guiding catheter. After that the inflated balloon catheter can be pulled proximally inside the guiding catheter. If the errant coil follows the balloon it may be thus pulled back into the guiding catheter. If it does not, the whole system has to be removed together with the guiding catheter. This technique is very simple and safe and, should it fail, does not preclude the use of other techniques. In our case the coil had detached inside the catheter after extensive stretch-

ing. Although its end was free in the guiding catheter the balloon catheter could easily be introduced and passed distal to it.

Acknowledgements We thank Paul S. Jackson for reviewing the manuscript.

References

1. Radü EW, Schumacher M, Mader I (1993) Incidence and treatment of complications during neuroradiologic interventions. In: Steinbrich W, Gross-Fengels W (eds) *Interventional Radiology*. Springer-Verlag, Berlin Heidelberg, pp 213–234
2. Graves VB, Rappe AH, Smith TP, Sepetka I, Ahuja A, Strother CM (1993) An endovascular retrieving device for use in small vessels. *AJNR* 14: 804–808
3. Smith TP, Graves VB, van Halbach V, et al (1993) Microcatheter retrieval device for intravascular foreign body removal. *AJNR* 14: 809–811
4. Dondelinger RF, Lepoutre B, Kurdziel JC (1991) Percutaneous vascular foreign body retrieval: experience of an 11-year period. *Eur J Radiol* 12: 4–10
5. Selby JB, Tegtmeyer CJ, Bittner GM (1990) Experience with new retrieval forceps for foreign body removal in the vascular, urinary, and biliary systems. *Radiology* 176: 535–538
6. Cekirge S, Weiss JP, Foster RG, Neimann HL, McLean GK (1993) Percutaneous retrieval of foreign bodies: experience with the nitinol goose neck snare. *J Vasc Interv Radiol* 4: 805–810
7. Egglin TK, Dickey KW, Rosenblatt M, Pollak JS (1995) Retrieval of intravascular foreign bodies: experience in 32 cases. *Am J Roentgenol* 164: 1259–1264
8. Gabelmann A, Kramer S, Gorich J (2001) Percutaneous retrieval of lost or misplaced intravascular objects. *Am J Roentgenol* 176: 1509–1513
9. Uflacker R, Lima S, Melichar AC (1986) Intravascular foreign bodies: percutaneous retrieval. *Radiology* 160: 731–735
10. Terada T, Mazumoto H, Nakamura R, Kinoshita Y, Nakai E, Itakura T (1996) Dual microcatheter and guidewire snare technique for retrieval of intravascular foreign body: Technical note. *Neuroradiology* 38: 615–617
11. Connors JJ III, Wojak JC (1999) *Interventional neuroradiology: strategies and practical techniques*. Saunders, Philadelphia, pp 48–49