

Salivary duct strictures

M. Koch, J. Zenk, and J. Brown

Introduction

The phenomenon of salivary gland obstruction has been widely documented and is readily recognized from its characteristic presenting symptom of gland engorgement and subsequent swelling during or shortly after eating. This is known as postprandial swelling. Chronic sialadenitis is commonly associated with an acute or chronic inflammation and obstruction of the excretory duct. The main causes of obstructive disorders are stones in about 60–70%, stenosis in about 15–25%, inflammation of the duct (sialodochitis) in about 5–10%, and other obstructions such as anatomic variations or foreign bodies in about 1–3% (Koch *et al.* 2005, Brown 2006, Ngu *et al.* 2007)

Salivary duct stricture formation is a less well appreciated cause of duct obstruction. Salivary duct strictures are an obstructive phenomenon about which remarkably little is known or understood. The development of stenosis has been documented in many tubular structures throughout the body, and appears to be the result of fibrosis developing within the walls of soft tissue ducts and tracts. The narrowing of a major salivary gland duct by any cause will result in a similar presentation of mealtime-related swelling of the affected gland, but it is central to the management of the condition that the true cause is accurately identified.

Incidence of salivary duct strictures

Much has been written about salivary stones, or calculi, as a cause of obstruction but until recently duct strictures have been largely overlooked as a cause of problems.

The incidence of salivary duct strictures has been investigated in 1362 patients (Ngu *et al.* 2007) referred for sialography to investigate mealtime-related symptoms of gland pain and swelling. In this series 35.6% of those investigated showed no radiological evidence of a salivary obstruction but 64.4% revealed a benign obstruction. In this cohort of 877 cases 73.2% were found to have a salivary calculus while 22.6% revealed no calculus but instead showed a stricture within the main salivary duct. The remaining 4.2% were diagnosed with mucous plugs, these representing thick and coagulated mucogelatinous salivary products which may play an important role in early stone formation and exacerbation of obstructive symptoms.

Strictures were observed most frequently in the parotid ducts (75.3%) and notably were almost three times (71.9%) more common in women (mean age 52 years) than in men (mean age 53 years). In 13 of 185 cases (7%) strictures affected the parotid glands bilaterally. In the main (66.7%), the stenoses were single or multiple single-point strictures and resided in the middle third of Stenson's duct. The remaining strictures (33.3%) resembled a continuous band of scar tissue along the duct.

Sialendoscopic examination of the salivary ducts confirmed these data with 19.8% (N = 63) of 318 patients with obstructive symptoms diagnosed with strictures. (Koch *et al.* 2008a). A bias

towards the parotid gland was also evident with 25.4% in the submandibular gland (SMG) and 74.6% in the parotid (N = 63) (Koch *et al.* 2008a). The nature of the stenosis in a series of parotid lesions (111 stenoses in 93 patients) was of multiple strictures (n ≥2) in 12.9% and 6.5% with bilateral lesions. Stenoses were located at the papilla in 9% of cases, at the hilum/proximal duct in 19.8%, 34.2% in the middle and 36.9% in the distal duct system. The mean age of patients was 49 years with a slight female predominance (57%) (Koch *et al.* 2009a).

Aetiology of strictures

The paper by Ngu *et al.* (2007) highlights differences between the incidence of salivary calculi and salivary duct stenosis. Calculi are more common in the submandibular ductal system while strictures appear more in the parotid glands. The reason for this difference is not clear. Possibilities are that the duct is narrower in the parotid compared to the SMG and so may be more readily obstructed by mild fibrosis. The parotid ducts follow a more superficial path through the cheeks and therefore may also be more vulnerable to external trauma. Lacerations to the face may occasionally compromise the parotid duct, but this does not explain the silent development of a stricture, which is the norm.

Ascending infection or the presence of an irritant calculi may play a role, but stones and infections are more prevalent in the SMG rather than the parotid gland. A study of stenosis cases showed that most patients had a history of obstructive symptoms for more than a year before diagnosis but without any detectable cause or trigger. In these cases a possible subclinical chronic parotitis may be an inductive factor, but in about 40% of patients a variety of conditions were present that could convincingly lead to stenosis. These included sialolethiasis with or without treatment (25.8%), allergic phenomenon (11.8%), autoimmune disease (5.4%), bruxism (4.3%), parotidectomy (3.2%) and radiotherapy (1.1%) (Koch *et al.* 2008b, 2009a).

Diagnosis

Ngu *et al.* (2007) showed that with strictures the classical symptoms of mealtime syndrome only occurred in about 30% of individuals. In the main (60%) the primary complaint was irregular and intermittent salivary gland swelling which was not related to meals. It often occurred in the early morning before or during the first meal of the day. The explanation is that stagnant saliva, which dams up behind a stricture, tends to clot and form a mucus plug. Thus overnight, when parotid flow is minimal, a plug forms which in the morning is washed forward and impacts in the stricture.

Signs and symptoms indicative of a stricture are a swollen gland that is present on waking or develops rapidly at the first meal of the day. The swelling lasts several hours before resolving suddenly with a rush of foul-tasting saliva. Diagnosis is by recognition of a subtle difference in obstructive symptoms from stones, followed by ultrasound, sialogram or direct inspection by sialendoscope. Imaging plays a central role not only in confirming the diagnosis but also in characterizing the type of stricture (position, length, and number) and its severity.

Ultrasound is a very effective imaging method: it is quick, safe and cost-effective. The stricture can be visualized easily after first administering a sialogogue (such as a vitamin C tablet or lemon juice) which acts to fill the duct proximal to the obstruction and enhances the taper of the duct as it enters the stenosis (Bozzato *et al.* 2009). Within the stenosis the duct is not visible on ultrasound. Location and degree of proximal duct dilatation can be measured exactly (see Fig. 26.2b), and checks made for any calculus formation.




Fig. 26.1 (a) Sialogram of a diffuse parotid stricture within the distal portion of the right parotid duct with proximal duct dilatation. (b) Sialogram of a point stricture close to the genu of the left submandibular duct.

Sialography is also an excellent way of visualizing the salivary ducts and allows classification into point strictures and diffuse strictures (Fig. 26.1), but it is no longer widely practised because of the drift to cross-sectional imaging. In its absence, ultrasound is an excellent alternative. MR sialography uses heavily T2-weighted sequences to image saliva, thus it will demonstrate the duct system especially if a sialogogue is given and this avoids need for administration of radiographic contrast media (Tanaka *et al.* 2008). It is a promising new technique, though more expensive.

Sialendoscopy has also received broad acceptance for the diagnosis of obstructive disorders as it provides direct visual evidence of the lesion and avoids radiation exposure, and may then be used in managing the identified obstruction. A set of endoscopes have been developed for this purpose with outer diameters ranging from 0.8 to 1.6 mm and length marked in centimetres along the barrel. As long as the endoscope is able to pass along the duct then the character of the stricture can be assessed with respect to site, number, length, degree of narrowing, and especially tissue quality around the stenosis. An attempt has been made to classify strictures from endoscopic observations with the tissue quality the defining feature (Marchal *et al.* 2008, Koch *et al.* 2009a). Inflammatory changes can be distinguished from scarred fibrotic tissue. Type 1 (inflammatory) strictures (Fig. 26.2a) show variable grades of luminal narrowing, whereas fibrotic stricture can have two appearances. One form (type 2) has a minor to medium-grade stenosis with web formation throughout the duct system and/or formation of a proximally dilated megaduct (Fig. 26.2b), the second (type 3) has a long or complete fibrotic stenosis (Fig. 26.2c) (Koch *et al.* 2009a). Endoscopic management has been designed to deal with these three types of stricture.

Treatment of salivary gland strictures

The symptoms that accompany strictures seldom merit parotidectomy (Nahlieli *et al.* 2002, Baurmash 2004, Koch *et al.* 2008a, 2008b). Strictures do not frequently lead to acute adenitis; more commonly a foreign body, such as a stone, is required for ascending infection. The advent of minimally invasive techniques has changed the surgical perspective towards gland-sparing therapy (Amin *et al.* 2001, Moody *et al.* 2000, Nahlieli *et al.* 2001, Drage *et al.* 2002, Motamed *et al.* 2003, Baurmash 2004, McGurk *et al.* 2006, Koch *et al.* 2008b).

A range of techniques which avoid surgical sialadenectomy are now available. Endoscopic dilatation is possible (Nahlieli *et al.* 2001, Koch *et al.* 2008a, 2008b, 2009b), as are transoral duct

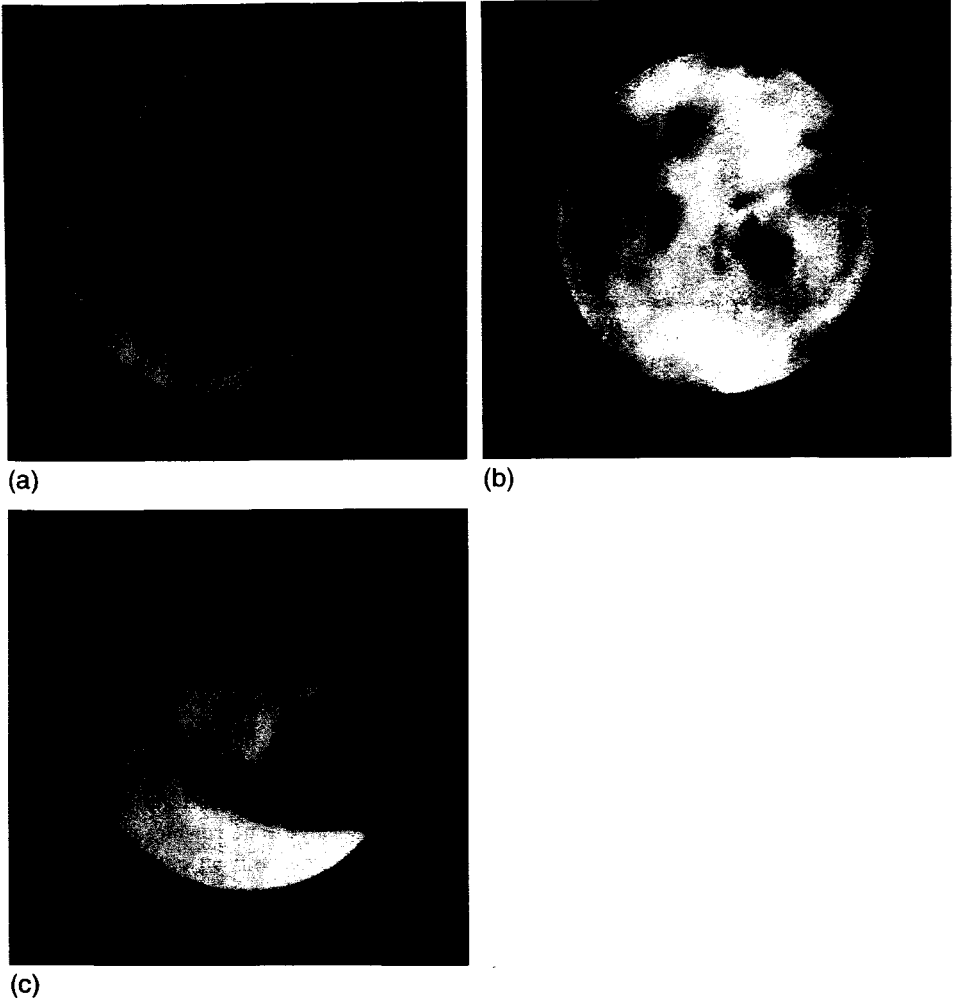


Fig. 26.2 (a) Type 1 stricture: inflammatory; red inflamed areas along the duct are evident on endoscopy. (b) Type 2 stricture: a band of scar tissue has started to form forming a ring within the lumen of the duct. (c) Type 3 stricture: the lumen is all but closed with a complete fibrotic stenosis.

procedures (Cohen *et al.* 2003, Koch *et al.* 2008a, 2008b) or combined endoscopic and transcatheter techniques (Marchal 2007). The resection of strictures and replacement with a vein graft has been tried before but with little success. The majority of inflammatory stenoses may be successfully treated by an endoscopic irrigation and intraductal steroid instillation. Fibrous stenoses require active dilatation by endoscopic or radiological means (Koch *et al.* 2008a, 2008b, 2009b) both of which can be performed under local anaesthesia (except in children and non-compliant adults) (Nahlieli *et al.* 2001, Koch *et al.* 2008a, 2008b). Results are surprisingly good, with 85–95% of patients not requiring further therapy (Nahlieli *et al.* 2001, Koch *et al.* 2008a, 2008b). This does not infer the stenosis has been eliminated completely, as many reform partially, but the resulting lumen of the duct is wide enough to allow saliva to flow again. For some reason the patients

remain largely asymptomatic or learn to control their symptoms effectively (Buckenham *et al.* 1992, Drage *et al.* 2002, Brown 2006). Postdilatation radiological images showed a 92% success rate immediately after balloon dilatation, with 82% of cases demonstrating complete elimination of the stricture (Drage *et al.* 2002). Sometimes the stricture is so tight it is not possible to pass the balloon, which is a limitation of the technique, but this also applies to the endoscope.

Patient preparation for a radiologically or endoscope-guided dilatation is as for stone extraction. The papilla is infiltrated with local anaesthetic and the duct washed with 2% lidocaine. Operative procedures are indicated when conservative methods fail. In the parotid, papillotomy or distal duct slitting should be undertaken with extreme caution. Unlike in the SMG, they commonly result in fresh stricture formation (Cohen *et al.* 2003, Koch *et al.* 2008a, 2008b). Stents can help prevent recurrent stenosis, but this is an ever-present problem once the distal duct is opened. This is especially the case when strictures occur at the papilla after extended papillotomy or distal duct slitting of Stensen's duct. The length of the stricture can be estimated by sialogram (see Fig. 26.5) and the distal portion of the duct resected followed by resiting of the main duct. When the stricture is in the mid section of the parotid duct it can be exposed by a combined endoscopic-surgical preauricular approach, then the damaged duct replaced with a vein patch. Follow-up results relating to patency are awaited (Marchal 2007). Nahlieli *et al.* (2001) and Koch *et al.* (2008a, 2008b) believe all surgical procedures in the duct system should be followed by temporary stent implantation in order to help prevent recurrent stenosis.

Ligation of the excretory duct is an option and may avoid parotidectomy if minimally invasive techniques fail. The role of ligation has been disputed, with some authors reporting success rates of only 50% (Baurmash 2004). Experience shows ligation is effective as long as the duct is not grossly dilated proximal to the ligature and all foreign bodies (stones) are removed prior to ligation. As an additional treatment option, repeat intraglandular application of botulinum toxin may also be attempted as an alternative to removal of the gland (Ellies *et al.* 2004).

Minimally invasive treatment algorithms for salivary gland strictures

Therapeutic options vary both between glands and type of stenosis encountered and are discussed separately. The first option for strictures at the punctum is to dilate. If this is unsuccessful in the submandibular system then opening or bypassing the punctum surgically are reliable options, which is not the case for the parotid duct punctum. Point strictures of ducts generally respond well to balloon dilatation, while diffuse strictures less so. In the submandibular system it is possible to open the duct into the floor of mouth more proximally by slitting or simple re-direction in diffuse strictures. Such duct slitting can extend into the hilum for very proximal submandibular duct strictures.

Operative technique

Sialendoscopic-controlled duct dilation (interventional sialendoscopy)

Various endoscopes and instruments have been developed for this purpose as well as different baskets, drills of various sizes, microforceps, and low- and high-pressure balloons (Fig. 26.3.).

Dilatation of the papilla is performed by lacrimal and Nettleship dilators. Dilation of the papilla is difficult in the SMG. Once dilated the duct is irrigated with local anaesthetic by an indwelling venous catheter (22 G, 0.9 mm). This will facilitate the insertion of the endoscope. The position of the advancing endoscope within the gland is shown by transillumination. Irrigation opens the duct lumen so that intraductal structures and strictures become clearly visible. In the presence of

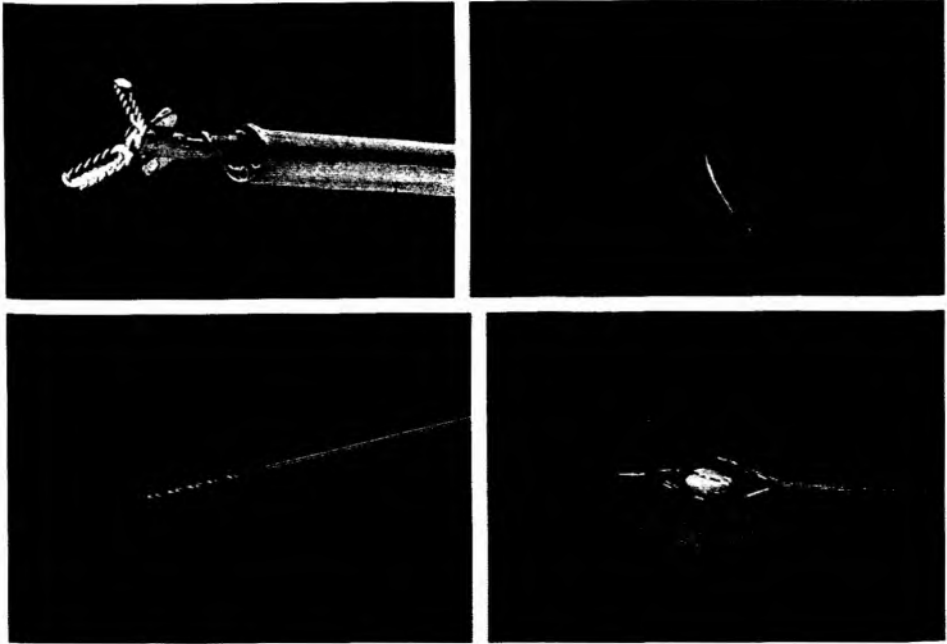


Fig. 26.3 Instruments—forceps, balloon, drill, and basket—used with endoscopy to break open a stricture and then dilate it.

modest stenosis, the duct can be dilated with 50 mL of saline mixed with a steroid (e.g. 250 mg prednisolone). In case of profound fibrous stenosis (lumen obscured) (Nahlieli *et al.* 2001, Koch *et al.* 2008a, 2008b) both baskets and drills are effective in opening most types of strictures (point, diffuse). The technique is for the basket to be inserted into the stenotic area and the tissue distended by opening and rotating the basket. The drill (hand-held) is especially useful in complete duct obstruction (type 3) or in case of web-associated stenosis (type 2). Microforceps and balloons cannot be introduced into filiform or complete stenoses initially, but once the lumen is opened then they can be used for further dilation. High-pressure balloons are insufflated with NaCl up to a pressure of 10 bar (1 MN/m^2) for 60–120 seconds. Dilatation is considered successful if a 1.1 mm sialendoscope can pass easily along the duct. Custom-made polyurethane stents of various length (20–120 mm, 4.5–9F) may be placed. After endoscopic placement the stent is sutured to the buccal mucosa and left in situ for 6–8 weeks. Correct positioning of the stent can also be achieved with ultrasound (Fig. 26.4).

After dilatation the patient is prescribed systemic antiphlogistic medication (serrapeptase 10 mg 3×2/day and proxicam 2×20 mg/day) and in case of intensive inflammation additional antibiotic medication (roxithromycine 1×300 mg/day or ampicillin with sulbactam 3×1 g/day for 7–10 days). Gland massage and sialogogues are recommended.

Radiologically controlled duct dilatation (interventional sialography)

The duct orifice is first dilated by manual insertion and manipulation of duct dilators to achieve a suitable size to gain access to the distal duct. No surgical duct opening is necessary at any point.

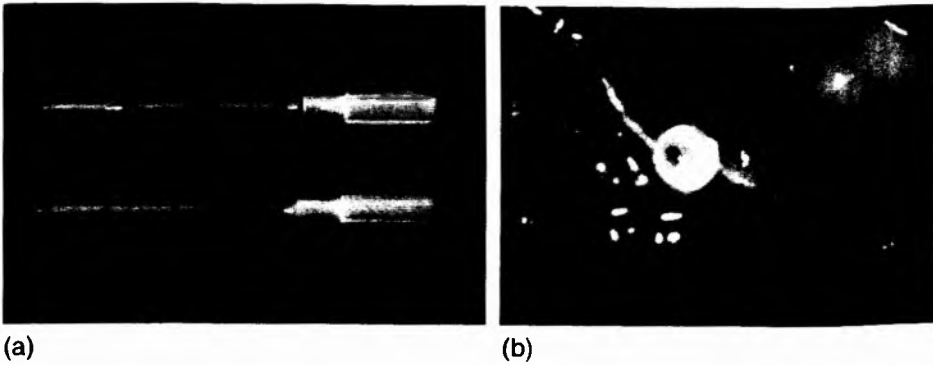


Fig. 26.4 (a) A salivary stent applicator, together with a stent sutured into position to support the parotid duct (b).

A guide wire is then passed down the duct and manipulated through the stenosis under radiological control during fluoroscopic screening, avoiding entry to accessory branches. A fine vascular balloon catheter, such as a 2 or 3 Fr Symmetry Stiff Shaft angioplasty balloon, may then be passed over the guide wire, and fed up to and through the stenosis. A balloon catheter with a reasonably rigid shaft and guide wire is helpful to push through densely fibrotic stenoses. A 2.5-mm balloon is suggested for parotid ducts in order to produce an inflated balloon diameter just larger than the normal duct diameter. If a stone lies proximal to the stenosis and the intention is to release the stone, then the choice of balloon is influenced by stone diameter. The balloon catheter is inserted to the most proximal stricture first then withdrawn, inflating periodically and working stepwise distally towards the duct orifice. The balloon is inflated rapidly to the full inflation pressure several times in each stricture, imaging being used to check on balloon position within the stenotic site, finally being deflated and withdrawn. A high-inflation-pressure, non-compliant angioplasty balloon such as the Symmetry balloon is recommended to break through dense fibrotic strictures as encountered within parotid ducts.

A newer design of balloon is the 'cutting balloon'. This has three microtome blades on the surface of the balloon which are deployed on inflation to create incisions into the fibrotic tissue in a controlled manner. This technique has been used effectively in the controlled dilatation of bypass grafts and haemodialysis fistulas where similarly severe fibrosis has compromised vessel lumen (Tsetis *et al.* 2006).

A postoperative sialogram is recommended to assess the degree of duct dilatation achieved. At this point a temporary flexible polythene stent may be placed and sutured *in situ* for 1–6 weeks (Fig. 26.5).

Sialogogues are advisable following the procedure, accompanied by gland massage to encourage salivary flow through the operative site. Postoperative oedema is common and the patient should be counselled regarding transient obstructive symptoms. Postoperative antibiotic therapy may be necessary in cases of pre-existing sialadenitis.

Clinical and sialographic review is recommended following balloon dilatation, as strictures may recur. In a review of 125 cases treated by balloon ductoplasty, on average 3 months post-procedure, 75% showed satisfactory elimination of the stenosis. 11 (9%) showed partial return of duct stricture, 14 (11%) showed persistence of the original stricture, and 5 (4%) developed increasing stenosis of the duct. The underlying aetiology of further stricture formation is unclear. It is possible that the inflammatory response that is induced by the procedure is sufficient to cause further fibrotic change, and in some patients the process is inexorable.

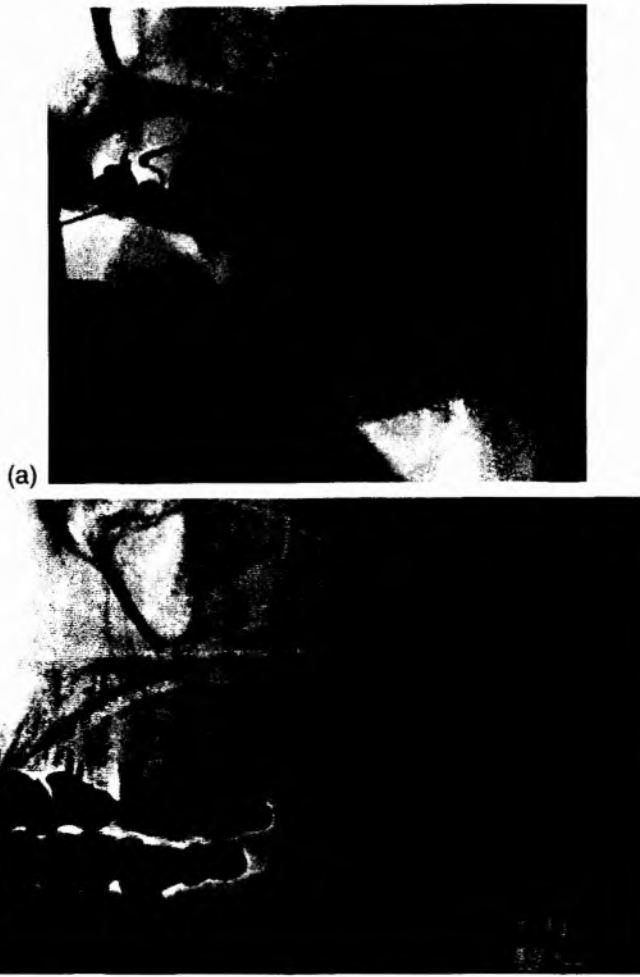


Fig. 26.5 (a) Sialogram showing stenosis located in the parotid duct before treatment. (b) Appearance on sialogram following dilatation.

Surgical technique

Transoral papillotomy and/or duct slitting in submandibular duct system

The procedure is performed as in treatment of stones with local anaesthesia (ultracaine 2% with adrenaline (epinephrine)). If extended duct slitting is contemplated for extensive submandibular ductal stenosis then anaesthesia should include the lingual nerve, the base of the anterior palatal arch, and the glossoalveolar fold. Dilatation is performed with a selection of dilators (lacrimal or salivary probes) and then the duct slit from distal to proximal. Duct slitting may extend into the hilar region and also into the gland parenchyma so the lingual nerve should be identified early in the procedure ('submandibulotomy'). If necessary, resection of the uncinat process has to be performed. The meticulous suturing of the duct epithelium to the surrounding mucosa with

absorbable sutures (e. g. 4-0 vicryl) is an important step to create a new ostium and to prevent recurrent stenosis due to formation of scar tissue. For this purpose, sutures in the hilar region are the most important (Zenk *et al.* 2001, McGurk 2005).

Transoral surgery in parotid duct system

If stenosis at the parotid papilla and/or distal duct fails to respond to dilatation then surgery is indicated. Papillotomy, distal duct slitting, or resection of the distal duct with reinsertion into the buccal mucosa are the recommended procedures. It is emphasized that papillotomy and distal duct slitting carry a high risk of restenosis and thus are not recommended as a routine procedure. A stent can be used to help reduce the risk of stenosis but is not always effective as restenosis may occur swiftly following stent removal.

Papillotomy consists of a through and through incision which includes the scarred tissue and all papillary layers (epithelium, muscle, and buccal mucosa). The incision can be extended to the distal duct if involved (extended papillotomy/distal duct slitting).

If no residual lumen exists the distal duct is resected and is reinserted into the buccal mucosa. This operation has a better success rate than the splitting procedures (Cohen *et al.* 2003, Koch *et al.* 2008b). One important precondition is that distance from the proximal end of the stenosis to the buccal mucosa should not exceed 15–20 mm. In some instances the proximal duct is massively dilated. This is mobilized and a neo-ostium created by suturing it to the oral mucosa with interrupted absorbable sutures (e.g. 5-0 vicryl).

Sialendoscopy is performed in all cases to exclude the presence of other pathology and to insert a stent to help prevent recurrent stenosis.

Results and experience

Sialendoscopic-controlled duct dilation (interventional sialendoscopy)

In a series of 25 patients (44% in SMG and 56 in parotid gland) treated by Nahlieli *et al.* (2001), success was achieved in 24/25 cases (96%) after a follow-up of 8–36 months, with repeat dilatation required in 16% of cases. Dilatation was achieved by endoscope, balloon, and forceps. In all cases a polyethylene stent was implanted after dilatation. In a second series of 61 patients with 67 gland strictures reported by Koch's group in Erlangen, Germany (25.4 % in the SMG and 74.6% in the parotid duct) immediate results showed successful dilation of 89.5% of all SMG and 85.5% of parotid gland strictures (overall 87% success). A more detailed report (Koch *et al.* 2008b) of 39 patients with parotid stenosis showed that 17.9% responded to conservative endoscopic measures, 56.4% by interventional sialendoscopy and 15.4% by operative surgery. The end result was that 5.1% of patients had persistent obstructive symptoms but not sufficient to warrant more treatment. In a further 5.1% the glands had to be resected. In 95% of cases the gland was preserved.

Radiologically controlled duct dilatation (interventional sialography)

In London a different approach was adopted for the management of strictures. Cases were referred to a radiologist with a special interest in salivary duct stenosis. These patients were managed by radiologically guided angioplasty balloon dilatation. Endoscopy was not employed and no distinction was made between inflammatory or fibrous lesions; strictures were simply dilated.

Over 10 years 311 balloon ductoplasty procedures were performed at Guy's and St Thomas' Hospital, London on 253 patients, with a female/male ratio of 2.4:1. The average age of the patients undergoing the procedure was 51.5 years. The data indicate a significantly higher incidence of stenosis in middle-aged women and mainly in the parotid (284 parotid versus

27 SMG) with 10.3:1 ratio. In 33% of cases the strictures were bilateral and these were almost always in the parotid.

In terms of technique 232 procedures were performed using Symmetry Stiff Shaft balloon catheters and 79 using cutting balloons. Immediate results showed 92.3% of strictures were successfully cannulated and dilated (287/311) while in 25 (7.7%) the guide wire could not be passed through the stenosis. Immediate postoperative sialographic assessment indicated elimination of the stricture in 227/311 (73%); 38/311 (12%) showed partial elimination, while 15% demonstrated no improvement or were not assessed by sialogram in the immediate postoperative period. An observation on technique was that 91.2% (62/68) of cutting balloons resulted in an immediate elimination of the stricture while only 75% (165/219) of conventional Symmetry balloons gave a similar result.

Most patients undergoing clinical review at 3 months reported positive experiences and a resolution of symptoms. In the Symmetry balloon group 75 of 118 available for follow-up were asymptomatic (63.6%), while 24/118 (20.3%) reported an improvement in obstructive symptoms, but 19/118 (16%) found no improvement. In the cutting balloon group 31 were reviewed; 22/31 (71%) were asymptomatic, 6 improved (19%) and 3 found no improvement (9.7%).

Radiological review of the postoperative duct by sialography was undertaken in 121 patients. This investigation showed long-term elimination of the stricture in 65/90 (72.2%) of Symmetry balloon cases and in 23/31 (74%) cutting balloon cases, while relapse of the stricture was seen in 25/90 (27.8%) of Symmetry balloon cases and 6/31 (19.35%) cases treated by cutting balloon. There were no significant differences overall between the groups for outcome.

Summary

The treatment of obstructive diseases of the major salivary glands has undergone a fundamental transformation over the past 10–15 years. Salivary duct stenosis used to be untreatable. It now can be treated with a high success rate by minimally invasive methods. Both endoscopic and radiologically guided techniques seem effective, but treatment is still in its infancy and remains to be fully refined. Invasive duct surgery is held in reserve but also has a role in treating the recalcitrant lesion. The net result is that invasive therapy regimes and gland removal can be avoided in more than 95% of cases. Analysis of large patient groups shows that it is not one individual therapeutic modality that provides maximal therapeutic results, but rather the combination of various methods (McGurk *et al.* 2006, Koch *et al.* 2008a, 2008b, 2009a, 2009b).

Audience discussion

Dr P. Capaccio (Milan Italy): I propose the current status with regard to investigation and management. Ultrasonography as the first line of investigation for salivary obstruction. If you find a small stone (<4 mm) it can be retrieved with a basket. If larger and in the parotid (>4 mm and <8 mm) then the ideal treatment is lithotripsy. Large stones in both the parotid and SMG can be removed by endoscope-assisted surgery.

If no stone is found the patient is investigated by sialography in England, France, and Israel and MR sialography in Italy, Germany, and Switzerland unless a stricture is obvious on ultrasound. A stricture is treated by means of sialoendoscopy or interventional radiology. If no stone or stricture is detected then sialoendoscopy may be undertaken as a diagnostic procedure.

Dr F. Marchal (Geneva, Switzerland): I would advocate sialoendoscopy as a diagnostic procedure earlier in the investigative cascade. If one has no dedicated radiological support then sialoendoscopy is an alternative.

May I add that if you have a lithotripter, then any stone fragments that result from treatment can be retrieved with a basket. The alternative if you do not have a lithotripter is to try and break the stone with forceps. But a word of caution; I have broken a number of forceps when trying to crush stones. The forceps are expensive! Lasers have not proved very useful to date.

Regarding strictures: Stensen's duct is about 2 mm in diameter. The balloon catheters are 0.7 mm in diameter, so with a damaged duct with a stricture there is even less room for manoeuvre. So one has at one's disposal, balloons (high pressure) and blind dilators, that have to be used with caution. The Erlangen group have had great success with a hand drill to open up apparently occluded ducts.

Dr M. Frisch (USA): I think you should emphasize that the balloons should be high pressure. The low-pressure variety tend to pop.

Dr J. Brown (London, UK): In treating salivary strictures, the pressure used to dilate the stricture is really crucial. We use the highest pressure balloons that we can get our hands on. Even then, a point stenosis may indent the balloon. So we have moved to cutting balloons. They have small microtomes mounted on the surface of the balloon. As you inflate the balloon, the blades cut the stricture and allow it to dilate. The technique we use is to just inflate, then release and inflate again. We do not hold the duct open for minutes at a time.

Professor Nahlieli (Israel): Low-pressure balloons are prone to break.

Professor M. McGurk (London, UK): Balloons can be used with endoscopes or under radiological control. I am not sure which is the best technique. The balloon is in front of the endoscope, so as the balloon opens then vision is obscured. It is difficult to work out what is happening in the duct. The balloon can slip out of the stricture as it is inflated. This is easier to visualize under radiological control but not so easy with the endoscope. The difficulty of positioning the balloon in the correct place can be overcome by using long balloons if they are available.

A low-pressure balloon popped when I was trying to dilate a stricture and it ruptured the duct completely. If this happens there is no need to worry. I left the patient for 2 months and a sialogram showed the duct had reformed and looked normal. Similarly, if you perforate a duct wall with an endoscope there are no consequences. Stop the procedure and wait a few weeks and the hole heals spontaneously.

Professor Nahlieli: If the balloon bursts then small fragments of sialastic material can remain in the tissues. This can cause problems.

Dr Brown: One difference between the endoscope and radiological technique is that when you use an endoscope to dilate strictures you dilate the most distal stricture first. In the radiological team we first visualize the whole duct and then work from proximal strictures backwards along the duct to the ostium. I feel the most proximal stricture with the greatest dilatation behind is the primary problem and for that reason I prefer to treat it first.

Professor Nahlieli: If you want to dilate a stricture under direct endoscopic vision, the best method is with micro drills. These are hand-held drills which are passed into the stricture and rotated. After a short period, as if a tight elastic band is cut, the duct suddenly springs open.

Editorial comment

The management of salivary strictures was a dark and essentially unproductive art until Drs Koch and Brown illuminated the subject by way of endoscopes and radiological imaging. They have both made a significant contribution to this subject. Dr Koch has tackled strictures from an endoscopic perspective and this has allowed identification of different groups of strictures by their clinical appearance. Dr Brown, in contrast, has used radiological techniques and has shown that balloon dilatation of strictures is effective in minimizing symptoms. Experience shows that

splitting at the punctum of the parotid is fraught with problems, as is repositioning the duct within the buccal mucosa.

The use of vein grafts to replace strictures should be considered with caution until data validating its use is available. In the late 1980s a large series of patients at St Richards Hospital, Chichester, UK were treated with vein grafts to replace strictures in the parotid duct. Mr Malcom Bailey who was the senior registrar in the unit (personal communication) reviewed the results, which were a universal failure in terms of duct patency. However, the glands were asymptomatic. The explanation was that once complete obstruction occurred the parotid gland ceased to function and quietly atrophied. In itself this is a reasonable result, as it avoids parotidectomy. Essentially a breakthrough has been made in the management of salivary strictures. The vast majority can be dealt with conservatively with good effect. This is a tribute to Dr Koch and Dr Brown.

References

- Amin MA, Bailey BM, Patel SR. (2001) Clinical and radiological evidence to support superficial parotidectomy as the treatment of choice for chronic parotid sialadenitis: a retrospective study. *Br J Oral Maxillofac Surg*, **39**, 348–52.
- Baurmash HD. (2004) Chronic recurrent parotitis: a closer look at its origin, diagnosis, and management. *J Oral Maxillofac Surg*, **62**, 1010–18.
- Bozzato A, Hertel V, Bumm K, et al. (2009) Salivary simulation with ascorbic acid enhances sonographic diagnosis of obstructive sialadenitis. *J Clin Ultrasound*, **37**, 329–32.
- Brown JE. (2006) Interventional sialography and minimally invasive techniques in benign salivary gland obstruction. *Semin Ultrasound CT MR*, **27**, 465–75.
- Buckenham T, Page JE, Jeddy T. (1992) Technical report: Interventional sialography—balloon dilatation of a Stensen's duct stricture using digital subtraction sialography. *Clin Radiol*, **45**, 34.
- Cohen D, Gatt N, Olschwang D, Perez R. (2003) Surgery for prolonged parotid duct obstruction: a case report. *Otolaryngol Head Neck Surg*, **128**, 753–754.
- Drage NA, Brown JE, Escudier MP, Wilson RF, McGurk M. (2002) Balloon dilatation of salivary duct strictures: report on 36 treated glands. *Cardiovasc Intervent Radiol*, **25**, 356–9.
- Ellies M, Gottstein U, Rohrbach-Volland S, Arglebe C, Laskawi R. (2004) Reduction of salivary flow with botulinum toxin: extended report on 33 patients with drooling, salivary fistulas, and sialadenitis. *Laryngoscope*, **114**, 1856–60.
- Koch M, Zenk J, Bozzato A, Bumm K, Iro H. (2005) Sialoscopy in cases of unclear swelling of the major salivary glands. *Otolaryngol Head Neck Surg*, **133**, 863–8.
- Koch M, Zenk J, Iro H. (2008a) Diagnostic and interventional sialoscopy in obstructive diseases of the salivary glands. *HNO*, **56**, 139–44.
- Koch M, Iro H, Zenk J. (2008b) Role of sialoscopy in the treatment of Stensen's duct strictures. *Ann Otol Rhinol Laryngol*, **117**, 271–8.
- Koch M, Iro H, Zenk J. (2009a) Sialendoscopy-based diagnosis and classification of parotid duct stenoses. *Laryngoscope*, **119**, 1696–703.
- Koch M, Iro H, Zenk J. (2009b) Algorithms for treatment of salivary gland obstructions. *Otolaryngol Clin N Am*, **42**, 1173–92.
- Marchal F. (2007) A combined endoscopic and external approach for extraction of large stones with preservation of parotid and submandibular glands. *Laryngoscope*, **117**, 373–7.
- Marchal F, Chossegros C, Faure F, et al. (2008) Salivary stones and stenosis. A comprehensive classification. *Rev Stomatol Chir Maxillofac*, **109**, 233–6.
- McGurk M. (2005) Surgical release of a stone from the hilum of the submandibular gland: a technique note. *Int J Oral Maxillofac Surg*, **34**, 208–10.

- McGurk M, Escudier MP, Thomas BL, Brown JE. (2006) A revolution in the management of obstructive salivary gland disease. *Dent Update*, **33**, 28–30, 33–6.
- Moody AB, Avery CM, Walsh S, Sneddon K, Langdon JD. (2000) Surgical management of chronic parotid disease. *Br J Oral Maxillofac Surg*, **38**, 620–2.
- Motamed M, Laugharne D, Bradley PJ. (2003) Management of chronic parotitis: a review. *J Laryngol Otol*, **117**, 521–526.
- Nahlieli O, Shacham R, Yoffe B, Eliav E. (2001) Diagnosis and treatment of strictures and kinks in salivary gland ducts. *J Oral Maxillofac Surg*, **59**, 484–90; discussion, 490–2.
- Nahlieli O, Sacham R, Yoffe B, Eliav E. (2002) Superficial parotidectomy for chronic recurrent parotitis? *J Oral Maxillofac Surg*, **60**, 970; author reply 970.
- Ngu RK, Brown JE, Whaites EJ, Drage NA, Ng SY, Makdissi J. (2007) Salivary duct strictures: nature and incidence in benign salivary obstruction. *Dentomaxillofac Radiol*, **36**(2), 63–7.
- Tanaka T, Ono K, Ansai T, Yoshioka I, *et al.* (2008) Dynamic magnetic resonance sialography for patients with xerostomia. *Oral Surg Oral Med Oral Pathol Oral Radiol Endod*, **106**, 115–23.
- Tsetis D, Morgan R, Belli A-M. (2006) Cutting balloons for the treatment of vascular stenoses. *Eur Radiol*, **16**, 1675–1683.
- Zenk J, Constantinidis J, Al-Kadah B, *et al.* (2001) Transoral removal of submandibular stones. *Arch Otolaryngol Head Neck Surg*, **127**, 432–6.