

# Prognostic factors in limited (T1–2, N0–1) oropharyngeal carcinoma treated with surgery ± adjuvant therapy

Georgios Psychogios, MD, PhD,<sup>1\*</sup> Konstantinos Mantsopoulos, MD, PhD,<sup>1</sup> Abbas Agaimy, MD, PhD,<sup>2</sup> Michael Koch, MD, PhD,<sup>1</sup> Johannes Zenk, MD, PhD,<sup>1</sup> Frank Waldfahrer, MD, PhD,<sup>1</sup> Heinrich Iro, MD, PhD<sup>1</sup>

<sup>1</sup>Department of Otorhinolaryngology, Head and Neck Surgery, Friedrich Alexander University of Erlangen–Nuremberg, Erlangen, Germany, <sup>2</sup>Institute of Pathology, Friedrich Alexander University of Erlangen–Nuremberg, Erlangen, Germany.

**ABSTRACT:** *Background.* Surgical therapy for early oropharyngeal carcinoma leads to excellent oncologic results but often requires adjuvant radiotherapy. The purpose of this study was to identify prognostic factors that worsen the outcome of limited oropharyngeal carcinoma treated with surgery ± adjuvant therapy.

*Methods.* Two hundred sixty-six patients were retrospectively evaluated between 1980 and 2007.

*Results.* Overall 5-year disease-specific survival (DSS) was 88.7% and local control (LC) was 93.3%. The univariate analysis showed a significant difference in DSS between pT1 and pT2 oropharyngeal carcinoma (DSS, 94.0% vs 81.2%;  $p = .008$ ) and patients with tumor depth greater than 5

mm (DSS, 94.5% vs 78.9%;  $p = .031$ ). No difference could be found as to N classification, marginal status, p16 human papillomavirus (HPV) status, type of treatment, and adjuvant radiotherapy.

*Conclusion.* Primary surgical treatment is an effective therapy of limited oropharyngeal carcinoma. Patients with pT2 status and tumor depth of more than 5 mm show a significantly worse survival rate and should be further investigated in future clinical trials. © 2013 Wiley Periodicals, Inc. *Head Neck* 35: 1752–1758, 2013

**KEY WORDS:** oropharyngeal cancer, prognostic factors, HPV, tumor depth, surgery

## INTRODUCTION

The management of patients with early oropharyngeal squamous cell carcinoma (SCC) remains controversial. At the beginning of the new millennium, several studies showed that radiotherapy in combination with chemotherapy offer similar oncologic and functional results with lower severe complication rates in advanced oropharyngeal carcinoma.<sup>1–3</sup> Furthermore, the increasing importance of human papillomavirus (HPV) infection in oropharyngeal carcinoma<sup>4,5</sup> and better survival after radiochemotherapy<sup>6</sup> in this group of patients have led many centers throughout the world to adopt primary radiochemotherapy as the definitive treatment for oropharyngeal carcinoma.<sup>7–9</sup>

However, recent studies show that both radiotherapy and chemotherapy can cause serious morbidity such as dysphagia, xerostomia, mandibular osteoradionecrosis, and pharyngeal strictures and may be associated with higher mortality rates.<sup>10,11</sup> On the other hand, other stud-

ies showed that the evolution of primary surgery has greatly reduced morbidity and mortality and improved function with even better oncologic results in some cases.<sup>12–14</sup> Surgical treatment also allows for accurate staging of the disease and avoidance of radiotherapy in cases with clear margins and absence of negative prognostic factors, retaining this therapeutic option in case of recurrence or second primary tumor, which occur in about 15% to 29% of the patients.<sup>15,16</sup>

Unfortunately, there are no studies examining the role of prognostic factors in early oropharyngeal carcinoma. Most recent studies concentrate on oncologic results of primary surgical therapy<sup>15,17–20</sup> or radiochemotherapy.<sup>11,16,21</sup> The purpose of this paper was to show the oncologic results of primary surgical therapy with or without adjuvant radiochemotherapy and to identify prognostic factors associated with worse outcome of surgically treated limited oropharyngeal carcinoma. To our best knowledge, this is the largest study of limited oropharyngeal carcinoma to date. It is also the first study to investigate the prognostic role of p16 immunohistochemistry as a surrogate marker of HPV infection in this patient group.

## PATIENTS AND METHODS

Patients referred to our hospital between 1980 and 2007 with previously untreated SCC of the oropharynx who underwent definitive surgical treatment were considered for selection. Included were all patients who, after

\*Corresponding author: G. Psychogios, Department of Otorhinolaryngology Head and Neck Surgery, Friedrich Alexander University of Erlangen–Nuremberg, Waldstrasse 1, 91054 Erlangen, Germany. E-mail: Georgios.Psychogios@uk-erlangen.de or gpsychogios@gmail.com

This work was presented at the American Academy of Otolaryngology – Head and Neck Surgery 2011 Annual Meeting and OTO EXPO, September 11–14, 2011, San Francisco, California.

The authors disclosed no conflicts of interest.

TABLE 1. Number of cases according to surgical technique and affected anatomic subsite of the oropharynx.

	Anatomic location				Total
	Tonsillar region	Soft palate	Base of tongue	Lateral and posterior pharyngeal wall	
Surgical technique					
Diathermy	87	78	20	15	200
Laser	13	16	25	12	66
Total	100	94	45	27	266
DSS	88.0%	88.1%	88.1%	86.7%	$p = .76$
LC	93.3%	92.8%	93.1%	96.2%	$p = .52$

Abbreviations: DSS, disease-specific survival; LC, local control.

the histological examination, proved to have a pT1–2 N0–1 M0 tumor (stage I–III). Exclusion criteria were previous treatment for head and neck carcinomas, distant metastases at the time of diagnosis, histology other than SCC, as well as patients with second primary tumors at the time of diagnosis. Relevant approval from the institutional review board of the hospital (Ethikkommission Universität Erlangen) was obtained. Staging was reevaluated after reviewing the surgical and pathology reports according to the 2010 American Joint Committee on Cancer and Union Internationale Contre le Cancer classification.<sup>22</sup> Standard preoperative diagnostics included clinical examination, ultrasonography, and CT. MRI was also used in a few cases.

The endpoints for the analysis were disease-specific survival (DSS) as well as local control (LC) and regional control (RC). DSS was defined using the time from the date of diagnosis to death from the cancer or complications of treatment. Time to LC or RC was calculated from the date of initial diagnosis to the date of most recent clinical review when local or regional recurrence was confirmed. Calculations of survival were made with Kaplan–Meier estimates and compared by the means of the log-rank test. A  $p$  value  $< .05$  was considered significant. Multivariate analysis was performed with stepwise backward Cox regression using significant variables from the univariate analysis. All statistical analyses were performed using SPSS, version 19 (SPSS, Chicago, IL).

Resection of the primary tumor was performed using transoral electrocautery in most cases in which the tumor could be directly accessed or transoral laser microsurgery in cases in which the location was deeper (eg, base of the tongue, inferior pole of the tonsils). In a few cases, a combined (transoral and transcervical) resection was necessary. Whenever possible, en bloc resection of the tumor was performed. Most patients also received a neck dissection. In cases with known or suspected neck metastases, a modified radical neck dissection was typically performed. In all cN0 cases in which the neck was surgically managed, a selective dissection of levels II to IV was usually performed, either ipsilateral or bilateral to the side of tumor, depending on the exact location of the primary lesion.

The use of adjuvant therapy in the form of radiotherapy or radiochemotherapy was decided by our tumor board. Irradiation typically included the primary tumor site and the involved side of the neck. Various changes in treatment protocols, as well as technical developments, have been noted over the years. Today, however, typical indications for radiochemotherapy include the presence of

positive surgical margins when further surgery was not feasible, advanced neck disease, and extracapsular tumor spread. Typical indications for adjuvant radiotherapy include close margins, solitary cervical metastasis, and infiltration of lymph vessels or nerves in permanent histology. Sometimes a combination of soft criteria such as poor differentiation, large tumor dimension, or large tumor depth can result to offer the patient adjuvant radiotherapy.

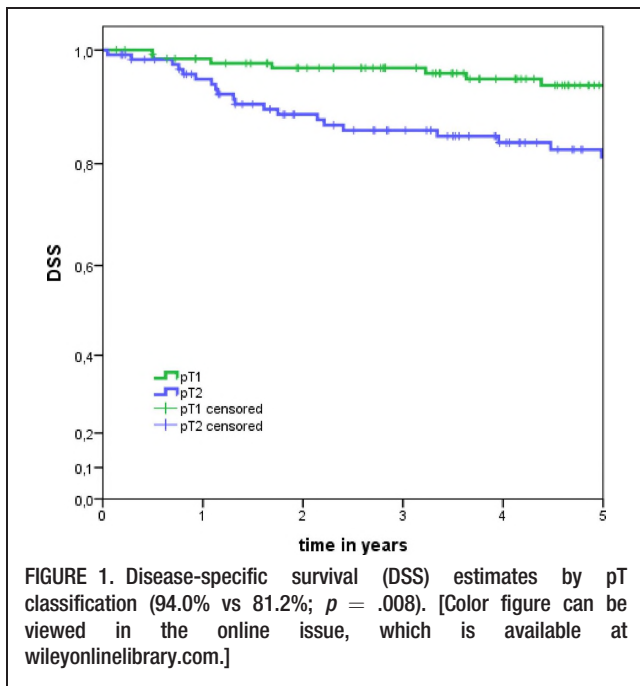
An HPV infection in tumor tissue was retrospectively determined using p16 immunohistochemistry as a highly sensitive and specific surrogate marker for HPV-associated carcinogenesis.<sup>23</sup> P16 immunohistochemistry was performed using a primary antibody retrieved from Santa Cruz Biotechnology (clone JC8, dilution: 1:100). Tumors were considered positive for p16 when strong nuclear and cytoplasmic staining was present in  $>60\%$  of cells. Status of p16 oncoprotein expression could be successfully determined in 83 patients with available paraffin blocks treated between 2000 and 2007. Characteristics of the 2 groups were controlled using the chi-square test.

## RESULTS

The final study population included 266 patients who met the inclusion criteria. The median age at presentation was 53 years ranging from 33 to 80 years (SD 9.81). Fifty-seven of the patients (21.4%) were women, with men to women ratio of 3.7:1. Mean follow-up was 6.4 years (range, 0.3–25.1 years).

The 5-year overall survival (OS) was 67.6%, DSS was 88.7%, LC was 93.3%, and RC was 96.2%. Of 266 patients, local recurrence occurred in 20 patients (7.5%), regional in 10 patients (3.8%), and distant metastasis in 11 patients (4.2%). Mean time to first local recurrence was 2.1 years.

The tonsillar region (ie, tonsil, tonsillar fossa, and pillars) was the most commonly affected subsite (37.6%), followed by the soft palate (35.3%), the base of the tongue (16.9%), and the posterior pharyngeal wall (10.2%). Univariate analysis did not reveal any significant differences in survival according to affected subsite. Almost all patients were operated on transorally. In 195 cases, the tumor was resected with electrocautery and in 66 cases with transoral laser microsurgery. Five patients were treated with a combined resection. Survival estimates according to surgical technique showed no statistically significant differences. Table 1 presents the number of patients according to surgical technique and anatomic



subsite affected. A free-flap reconstruction was performed in 10 cases, a pectoralis major flap in 15 cases, a local flap in 6 cases, and 235 cases were left for secondary wound healing.

After reevaluating the pathology reports of all patients, negative surgical margins (R0) had been achieved in 255 patients (95.9%) whereas positive margins (R+) remained in 11 patients (4.1%) at the end of surgical treatment. In 7 cases, patients refused a new resection and in 4 cases it was not possible because of bad general health. All R+ patients received an adjuvant therapy (5 radiotherapy and 6 radiochemotherapy). Because of the very low number of incompletely resected tumors, survival estimates for this group are flawed.

The neck was surgically treated in 205 patients. Of these, 93 patients had a cN0 classification and 112 had a cN+. A unilateral neck dissection was performed in 129 cases and bilateral in 76 cases. A median number of 25 lymph nodes (SD  $\pm 9$ ) were identified in each cervical side after neck dissection. One hundred fifty-one patients proved to have a pN0 classification and 54 patients had pN1. Of the 61 patients without neck dissection, 60 had a cN0 classification and only 1 had cN1. The last patient died because of tumor bleeding 10 days after the initial resection and before the planned neck dissection. This patient was also the only case of therapy-related mortality. The univariate analysis showed a trend toward a better DSS in patients who received a neck dissection (92.1% vs 86.8%;  $p = .053$ ). However, pN1 classification of the neck did not prove to be a negative prognostic factor in this study, if compared with pN0 (DSS, 88.3% vs 86.9%;  $p = .71$ ). A worse, but statistically not significant, regional control was determined (97.4% vs 92.1%;  $p = .45$ ). Of the 54 patients with pN1 classification, 44 received postoperative adjuvant radiochemotherapy and

10 did not. DSS did not differ significantly in the 2 groups (90.0% vs 88.7%;  $p = .53$ ).

Adjuvant therapy was applied in 180 of the 266 patients (67.7%), 155 in the form of radiotherapy and 25 radiochemotherapy. A mean cumulative radiation dosage of 60 Gy (SD, 12.5 Gy) has been applied using conventional or accelerated fractionation and intensity modulated radiation therapy since 2004. A concomitant cisplatin-based chemotherapy was applied if judged necessary. Patients with adjuvant therapy showed a trend toward a better LC (95.3% vs 89.0%;  $p = .07$ ) but identical DSS as those who did not receive such a treatment (88.0% vs 87.9%;  $p = .96$ ).

Disease in all patients was staged according to pathological T classification. One hundred thirty-nine cases (52.3%) had a pT1 primary tumor and 127 (47.7%) had a pT2. Univariate analysis showed that OS (74.3% vs 60.4%;  $p = .04$ ) and DSS (94.0% vs 81.2%;  $p = .008$ ; Figure 1) were significantly better in pT1 patients. On the other hand, LC and RC did not show any differences. T1 tumors did not benefit from an adjuvant treatment (DSS 92.0% for 73 patients with adjuvant treatment and 96.4% for 66 patients without;  $p = .41$ ), but T2 tumors seemed to have a benefit (DSS 85.1% for 107 with adjuvant treatment and 68.5% for 20 patients without;  $p = .008$  but log-rank test underpowered).

Median pathologic tumor depth was 5 mm (range, 1–29 mm). Univariate analysis was performed to prove the best cutoff of tumor depth for DSS and OS. After calculating all possible combinations, the best cutoff was found to be at 5 mm. OS (81.1% vs 56.0%;  $p = .04$ ) and DSS (94.5% vs 78.9%;  $p = .03$ ; Figure 2) proved to be significantly better in cases with tumor thickness of 5 mm or less. Patients with a tumor thickness greater than 5 mm, showed a trend toward a worse LC (96.5% vs 87.9%;  $p = .08$ ). Of the 50 patients with a tumor depth of more than 5 mm, 33 received an adjuvant therapy and 17 did

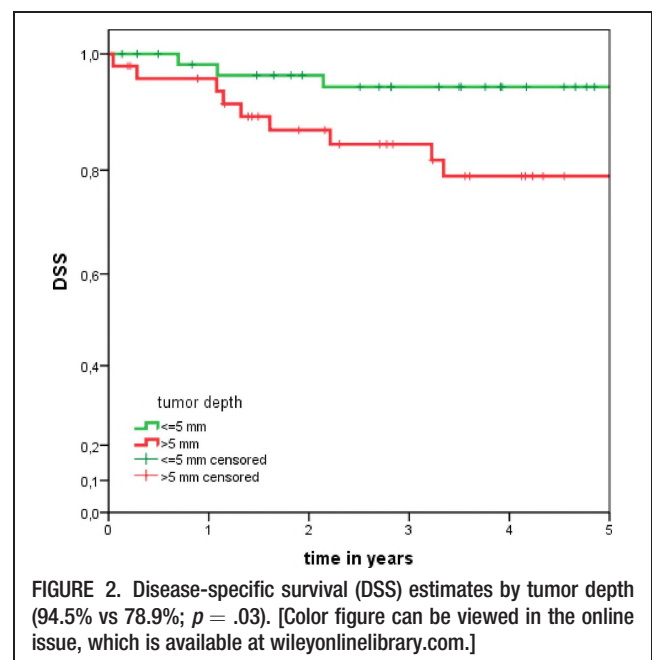


TABLE 2. Univariate analysis of potential prognostic factors for survival.

Variables (no. of patients)	LC	RC	DMC	DSS	OS
Age, y					
>53 (130)	0.946	0.96	<b>0.953</b>	0.876	<b>0.62</b>
≤53 (136)	0.912; <i>p</i> = .136	0.965; <i>p</i> = .937	<b>0.991; <i>p</i> = .038</b>	0.885; <i>p</i> = .422	<b>0.725; <i>p</i> = .002</b>
Sex					
Male (209)	0.942	0.966	0.97	0.864	<b>0.632</b>
Female (57)	0.906; <i>p</i> = .862	0.956; <i>p</i> = .834	0.980; <i>p</i> = .461	0.929; <i>p</i> = .185	<b>0.831; <i>p</i> = .003</b>
Tumor subsite					
Tonsillar region (100)	0.933	0.987	0.963	0.88	0.73
Soft palate (94)	0.928	0.975	0.987	0.881	0.664
Base of the tongue (45)	0.931	0.955	0.971	0.881	0.624
Posterior wall (27)	0.962	0.846	0.987	0.867	0.607
pT status					
pT1 (139)	0.943	0.973	0.991	<b>0.94</b>	<b>0.743</b>
pT2 (127)	0.924; <i>p</i> = .489	0.948; <i>p</i> = .318	0.949; <i>p</i> = .162	<b>0.812; <i>p</i> = .008</b>	<b>0.604; <i>p</i> = .049</b>
R status					
R0 (255)	0.935	0.961	0.971	0.879	0.672
R+ (11)	0.90; <i>p</i> = .850	“1”; <i>p</i> = .515	“1”; <i>p</i> = .282	0.909; <i>p</i> = .733	0.758; <i>p</i> = .417
Neck dissection					
Yes (205)	0.936	0.959	0.981	0.921	0.697
No (61)	0.925; <i>p</i> = .708	0.978; <i>p</i> = .398	0.970; <i>p</i> = .977	0.868; <i>p</i> = .053	0.604; <i>p</i> = .242
N status					
N0 (211)	0.917	0.974	0.971	0.883	0.673
N1 (55)	0.941; <i>p</i> = .077	0.921; <i>p</i> = .446	0.979; <i>p</i> = .078	0.869; <i>p</i> = .708	0.687; <i>p</i> = .638
Tumor depth					
≤5 mm (60)	0.965	“1”	0.98	<b>0.945</b>	<b>0.811</b>
>5 mm (50)	0.879; <i>p</i> = .117	0.971; <i>p</i> = .998	0.918; <i>p</i> = .343	<b>0.789; <i>p</i> = .031</b>	<b>0.560; <i>p</i> = 0.036</b>
Differentiation					
Well/moderate (188)	0.931	0.954	0.978	0.873	0.682
Poor (73)	0.986; <i>p</i> = .572	0.982; <i>p</i> = .886	0.967; <i>p</i> = .545	0.923; <i>p</i> = .692	0.700; <i>p</i> = .872
Perinodal invasion					
No (210)	0.931	0.96	0.977	0.889	0.68
Yes (6)	“1”; <i>p</i> = .519	0.667; <i>p</i> = .028	“1”; <i>p</i> = .711	0.533; <i>p</i> = .071	0.333; <i>p</i> = .164
Lymphatic invasion					
No (219)	0.934	0.955	0.978	0.872	0.668
Yes (16)	0.923; <i>p</i> = .946	“1”; <i>p</i> = .457	0.917; <i>p</i> = .315	0.923; <i>p</i> = .549	0.565; <i>p</i> = .678
Therapy					
Surgery only (86)	<b>0.89</b>	0.947	0.971	0.879	0.68
Surgery + radiotherapy (180)	<b>0.953; <i>p</i> = .074</b>	0.978; <i>p</i> = .882	0.973; <i>p</i> = .623	0.880; <i>p</i> = .964	0.675; <i>p</i> = .739
HPV					
No (52)	0.945	0.95	0.971	0.919	0.795
Yes (31)	No events	No events	No events	0.952; <i>p</i> = .441	0.808; <i>p</i> = .592
Type of surgery					
Laser (66)	0.954	0.903	No events	0.85	0.688
Conventional (195)	0.924; <i>p</i> = .466	0.993; <i>p</i> = .013	0.962; <i>p</i> = .060	0.889; <i>p</i> = .777	0.675; <i>p</i> = .685
UICC					
I (113)	0.931	0.98	0.989	0.948	0.74
II (98)	0.902	0.963	0.946	0.804	0.592
III (55)	“1”	0.921	0.979	0.869	0.687

Abbreviations: LC, local control; RC, regional control; DMC, distant-metastasis-control; DSS, disease-specific survival; OS, overall survival; HPV, human papillomavirus; UICC, Union Internationale Contre le Cancer. The figures in boldface represent XXX.

not. Univariate analysis did not reveal any differences in survival.

Status of p16 oncoprotein immunohistochemical expression was determined in 83 patients. Thirty-one patients proved to be p16 positive and 52 were p16 negative. The mean age of the first group was 52.5 years and that of the second group was 54.5 years. No significant differences regarding mean age or T and N classification were found. Univariate analysis revealed similar OS (80.8% vs 79.5%; *p* = .59) and DSS (95.2% vs 91.9%; *p* = .44) in both

groups. There were not enough events to permit statistical comparison of LC and RC.

Table 2 shows the results of univariate analysis of all potential prognostic factors analyzed. Both age and sex proved to be important for OS but violated the proportional assumption of the Cox regression and could not be included in the multivariate analysis. Tumor differentiation did not affect survival. For perinodal and lymphatic invasion, statistical analysis was flawed because of the low number of cases in 1 group. After selecting the



TABLE 3. Results of multivariate analysis for disease-specific survival.

Factor	SE	Wald (chi-square)	p value (Wald)	Odds ratio (95% CI)
T classification (T1 vs T2)	0.354	6.628	.01	2.49 (1.24–4.97)
Tumor depth (≤5 mm vs >5 mm)	0.513	4.260	.04	2.88 (1.06–7.87)

Abbreviation: CI, confidence interval.

appropriate variables from the univariate analysis, multivariate analysis was performed. The T classification and tumor depth proved to be statistically significant independent predictors of reduced DSS and OS (Tables 3 and 4).

## DISCUSSION

Limited oropharyngeal carcinoma is an infrequent but highly curable disease. A number of retrospective studies have shown that surgery, but also radiotherapy, can produce excellent results in this patient group (Tables 5 and 6). DSS was 69% to 94% for primary surgery with adjuvant radiotherapy if necessary, and 60% to 95% for primary radiotherapy followed by surgical salvage if needed. The only comparative study published to date showed a slightly better DSS of surgically versus nonsurgically treated patients, even though statistically not significant (69% vs 60%;  $p = .22$ ).<sup>24</sup> This study used a national prospective audit, perhaps explaining the worse survival in

comparison to all other studies. Unfortunately, there are no high-quality comparative studies of the 2 treatment strategies.

The philosophy in our department is to offer most patients with limited oropharyngeal carcinoma a primarily surgical treatment with adjuvant therapy if necessary. The reasons for this approach are as follows. First, and most important, the excellent oncologic results (DSS = 88.7%) at the high end of the existing literature. Second, the low complication profile of surgery. The general use of transoral techniques and the application of a laser minimize the complication rates and improve function.<sup>25,26</sup> The last reason is the high incidence of second primary tumors which is between 15% and 29% even in limited oropharyngeal carcinoma.<sup>15,16</sup> Because radiotherapy can only be applied once in a therapeutic dose, the question why not to use surgery, which can be applied as often as necessary, and reserve radiotherapy for relapse or second malignancy seems quite justified. This aspect becomes even more important in HPV-associated oropharyngeal carcinoma, in which patients mostly develop disease at a younger age.<sup>6,27</sup> On the other hand, as this study showed, many of the patients intended to be treated with surgery alone and eventually required an adjuvant radiochemotherapy and had the increased morbidity of a combined treatment.<sup>28,29</sup>

The main purpose of this study was to offer head and neck surgeons the information needed to optimize treatment, particularly regarding the necessity of adjuvant therapy. Therefore, it is of great importance to determine

TABLE 4. Results of multivariate analysis for overall survival.

Factor	SE	Wald (chi-square)	p value (Wald)	Odds ratio (95% CI)
T classification (T1 vs T2)	0.168	3.827	.05	1.39 (0.999–1.928)
Tumor depth (≤5 mm vs >5 mm)	0.291	4.274	.039	1.83 (1.032–3.233)
Sex (male vs female)		Violation of the proportional hazards assumption.		
Age (>53 vs ≤53)		Violation of the proportional hazards assumption.		

Abbreviation: CI, confidence interval.

TABLE 5. Survival of limited oropharyngeal carcinoma after surgical management in the recent literature.

Authors	No. of patients	DSS	LC	OS	Type of therapy	Study period
Karatzanis et al, <sup>26</sup> 2011 pT1 Nx, Germany	123	92%	-	-	Surgery ± radiotherapy	1984–2005
O'Hara and MacKenzie, <sup>24</sup> 2011 T1–2N0, Scotland	42	69%		60%	Surgery ± radiotherapy	1999–2001
Psychogios et al, <sup>31</sup> 2012 pT2 pN0–1, Germany	93	84%	-	-	Surgery ± radiotherapy	1985–2005
Röösli et al, <sup>30</sup> 2009 T1–2Nx, Switzerland	238	T1 = 85.7% T2 = 77.5%	-	80.8% 63.1%	Surgery ± radiotherapy or radiochemotherapy	1990–2006
Moncrieff et al, <sup>17</sup> 2009 pT1–2Nx, Australia	92	83%	87%	-	Surgery ± radiotherapy	1987–?
Shin et al, <sup>19</sup> 2009 cT1–2cN0, Korea	46	83%			Surgery ± radiotherapy	1992–2006
Walvekar et al, <sup>15</sup> 2008 T1–2N0–1, United States	4	83%	-	-	Surgery ± radiochemotherapy	1982–2004
Lim et al, <sup>20</sup> 2008 pT1–2Nx, Seoul	19	94%	-	-	Surgery ± radiotherapy	1992–2004

Abbreviations: DSS, disease-specific survival; LC, local control; OS, overall survival.

TABLE 6. Survival of limited oropharyngeal carcinoma after nonsurgical management in the recent literature.

Authors	No. of patients	DSS	LC	OS	Type of therapy	Study period
O'Hara et al, <sup>24</sup> 2011 T1–2N0, Scotland	30	60%		50%	Radiotherapy ± salvage	1999–2001
Eisbruch et al, <sup>11</sup> 2010 cT1–2cN0–1, United States	67	95.5% (2 y)	91% (2 y)	-	IMRT	2001–2005
Selek et al, <sup>16</sup> 2004 cT1–2cN0, United States	175	85%	85%	70%	Radiotherapy ± salvage	1970–1998
Charbonneau et al, <sup>21</sup> 2006 T1cNx, Australia	164	-	82%	62%	Radiotherapy ± salvage	1990–1999

Abbreviations: DSS, disease-specific survival; LC, local control; OS, overall survival; IMRT, intensity modulated radiation therapy.

factors that increase the risk of recurrent disease and reduce survival. The retrospective nature of this article and the long period of study are the main limitations. Furthermore, because many patients received adjuvant radiotherapy, it is difficult to fully interpret and apply the findings.

The best prognostic factor of this group of patients proved to be the T classification. Our results show that patients with T2 tumors have a 2.5-fold chance of dying from their tumor in comparison to pT1. Unfortunately, our study does not have the statistical power to determine the necessity of adjuvant radiotherapy in T2 oropharyngeal carcinoma. Rösli et al<sup>30</sup> also found a significant difference in DSS between T1 and T2 oropharyngeal carcinoma (85.7% vs 77.5%;  $p < .001$ ). Other studies also demonstrate better survival for T1 tumors, although not always statistically significant.<sup>17,31</sup>

The second important prognostic factor of this study was tumor depth. A patient with a tumor depth of more than 5 mm had a 2.8-fold chance of dying from their tumor in this study. Other studies also proved a correlation between tumor depth and survival in early and advanced oral cancers.<sup>32,33</sup> Tumor depth also seems to be a predictive factor for cervical lymph node metastasis. There is, however, little agreement about the best cutoff point to be used and the clinical relevance.<sup>34,35</sup>

Recent studies have demonstrated a high concordance between direct detection of HPV and p16 overexpression in oropharyngeal carcinoma, indicating a high sensitivity and specificity of this simple test as a useful surrogate marker for assessing the HPV status in oropharyngeal carcinoma.<sup>23</sup> Our study shows that biological prognostic factors, such as HPV, can have variable importance in different stages of the same disease. A recent prospective study showed that patients with stage III or IV oropharyngeal carcinoma who were treated with primary radiochemotherapy showed significantly better survival if they were HPV positive.<sup>6</sup> All other studies published to date on this topic also concentrate on advanced oropharyngeal carcinoma.<sup>36,37</sup> According to our results, HPV infection as identified by the highly sensitive and almost specific p16 immunostaining does not influence the outcome of surgically treated limited oropharyngeal carcinoma and should therefore not play a role in the management of these tumors. One possible explanation is the generally good survival of limited oropharyngeal carcinoma irrespective of the p16 status. Because of the relative small number of patients in whom the p16 oncoprotein could be deter-

mined in our study, these data should be verified in a larger prospective study. Expression of p16 has been proven to be a reliable biomarker of infection with HPV in head and neck cancer, but direct determination of HPV with polymerase chain reaction would be even better.<sup>37,38</sup>

A solitary lymph node metastasis less than 3 cm does not worsen the prognosis in this group of patients. This is consistent with most of the literature.<sup>39,40</sup> Therefore, other known prognostic factors, such as perinodal invasion, should be taken into account in patients with pN1 status. A prospective multicentric trial currently being executed tries to give a definitive answer.<sup>41</sup> This study has not demonstrated any survival benefit from the use of neck dissection, a finding also reported from other studies.<sup>42</sup> Nevertheless, we always perform an elective neck dissection in our institution because of the high percentage of occult metastases, even in early oropharyngeal carcinoma,<sup>26,40,43</sup> and the high risk of losing the patient in the follow-up period in our region.

## CONCLUSION

This study confirms that primary surgery with or without adjuvant radiochemotherapy results in excellent survival in limited (T1–2, N0–1) oropharyngeal carcinoma. Tumor depth and pT classification proved to be important independent prognostic factors. Future clinical trials should investigate the use of adjuvant radiotherapy in this patient group. N1 classification and p16 expression (as a surrogate marker of HPV infection) did not alter survival and needs further investigation.

## Acknowledgements

The authors thank Philipp Grundtner for his valuable assistance during statistical analysis of the data.

## REFERENCES

1. Parsons JT, Mendenhall WM, Stringer SP, et al. Squamous cell carcinoma of the oropharynx: surgery, radiation therapy, or both. *Cancer* 2002;94:2967–2980.
2. Allal AS, Nicoucar K, Mach N, Dulguerov P. Quality of life in patients with oropharynx carcinomas: assessment after accelerated radiotherapy with or without chemotherapy versus radical surgery and postoperative radiotherapy. *Head Neck* 2003;25:833–839; discussion 839–840.
3. Mowry SE, Ho A, Lotempio MM, Sadeghi A, Blackwell KE, Wang MB. Quality of life in advanced oropharyngeal carcinoma after chemoradiation versus surgery and radiation. *Laryngoscope* 2006;116:1589–1593.
4. Ihloff AS, Petersen C, Hoffmann M, Knecht R, Tribius S. Human papilloma virus in locally advanced stage III/IV squamous cell cancer of the oropharynx and impact on choice of therapy. *Oral Oncol* 2010;46:705–711.

5. Chaturvedi AK, Engels EA, Anderson WF, Gillison ML. Incidence trends for human papillomavirus-related and -unrelated oral squamous cell carcinomas in the United States. *J Clin Oncol* 2008;26:612–619.
6. Ang KK, Harris J, Wheeler R, et al. Human papillomavirus and survival of patients with oropharyngeal cancer. *N Engl J Med* 2010;363:24–35.
7. Chen AY, Schrag N, Hao Y, Stewart A, Ward E. Changes in treatment of advanced oropharyngeal cancer, 1985–2001. *Laryngoscope* 2007;117:16–21.
8. Haigentz M Jr, Silver CE, Corry J, et al. Current trends in initial management of oropharyngeal cancer: the declining use of open surgery. *Eur Arch Otorhinolaryngol* 2009;266:1845–1855.
9. Cohan DM, Popat S, Kaplan SE, Riquel N, Loree T, Hicks WL Jr. Oropharyngeal cancer: current understanding and management. *Curr Opin Otolaryngol Head Neck Surg* 2009;17:88–94.
10. Pederson AW, Haraf DJ, Witt ME, et al. Chemoradiotherapy for locoregionally advanced squamous cell carcinoma of the base of tongue. *Head Neck* 2010;32:1519–1527.
11. Eisbruch A, Harris J, Garden AS, et al. Multi-institutional trial of accelerated hypofractionated intensity-modulated radiation therapy for early-stage oropharyngeal cancer (RTOG 00–22). *Int J Radiat Oncol Biol Phys* 2010;76:1333–1338.
12. Kreeft AM, van der Molen L, Hilgers FJ, Balm AJ. Speech and swallowing after surgical treatment of advanced oral and oropharyngeal carcinoma: a systematic review of the literature. *Eur Arch Otorhinolaryngol* 2009;266:1687–1698.
13. Weinstein GS, Quon H, O'Malley BW Jr, Kim GG, Cohen MA. Selective neck dissection and deintensified postoperative radiation and chemotherapy for oropharyngeal cancer: a subset analysis of the University of Pennsylvania transoral robotic surgery trial. *Laryngoscope* 2010;120:1749–1755.
14. Bozec A, Poissonnet G, Chamorey E, et al. Quality of life after oral and oropharyngeal reconstruction with a radial forearm free flap: prospective study. *J Otolaryngol Head Neck Surg* 2009;38:401–408.
15. Walvekar RR, Li RJ, Gooding WE, et al. Role of surgery in limited (T1–2, N0–1) cancers of the oropharynx. *Laryngoscope* 2008;118:2129–2134.
16. Selek U, Garden AS, Morrison WH, El-Naggar AK, Rosenthal DI, Ang KK. Radiation therapy for early-stage carcinoma of the oropharynx. *Int J Radiat Oncol Biol Phys* 2004;59:743–751.
17. Moncrieff M, Sandilla J, Clark J, et al. Outcomes of primary surgical treatment of T1 and T2 carcinomas of the oropharynx. *Laryngoscope* 2009;119:307–311.
18. Mantsopoulos K, Psychogios G, Waldfahrer F, Zenk J, Iro H. Surgical treatment of locally limited tonsillar cancer. *Surg Oncol* 2012;21:e13–e16.
19. Shin HA, Lim YC, Jeong HM, Choi EC. Role of primary surgery for early-stage (T1–2N0) squamous cell carcinoma of the oropharynx. *Oral Oncol* 2009;45:1063–1066.
20. Lim YC, Hong HJ, Baek SJ, et al. Combined surgery and postoperative radiotherapy for oropharyngeal squamous cell carcinoma in Korea: analysis of 110 cases. *Int J Oral Maxillofac Surg* 2008;37:1099–1105.
21. Charbonneau N, Gélinas M, del Vecchio P, et al. Primary radiotherapy for tonsillar carcinoma: a good alternative to a surgical approach. *J Otolaryngol* 2006;35:227–234.
22. American Joint Committee on Cancer (AJCC) Cancer Staging Manual, 7th edition. In: Edge SC, Byrd DR, Compton CC, Fritz AG, Greene FL, Trotti A, editors. New York: Springer-Verlag; 2010.
23. Ukpo OC, Flanagan JJ, Ma XJ, Luo Y, Thorstad WL, Lewis JS Jr. High-risk human papillomavirus E6/E7 mRNA detection by a novel in situ hybridization assay strongly correlates with p16 expression and patient outcomes in oropharyngeal squamous cell carcinoma. *Am J Surg Pathol* 2011;35:1343–1350.
24. O'Hara J, MacKenzie K. Surgical versus non-surgical management of early stage oropharyngeal squamous cell carcinoma. *Eur Arch Otorhinolaryngol* 2011;268:437–442.
25. Iro H, Mantsopoulos K, Zenk J, Waldfahrer F, Psychogios G. Results of transoral laser resection in T1–2 oropharyngeal, hypopharyngeal and laryngeal carcinomas. [Article in German] *Laryngorhinootologie* 2011;90:481–485.
26. Karatzanis AD, Psychogios G, Waldfahrer F, Zenk J, Velegakis GA, Iro H. Surgical management of T1 oropharyngeal carcinoma. *Head Neck* 2011;34:1277–1282.
27. Nguyen NP, Ly BH, Betz M, Vinh-Hung V. Importance of age as a prognostic factor for tonsillar carcinoma. *Ann Surg Oncol* 2010;17:2570–2577.
28. Bessell A, Glennly AM, Furness S, et al. Interventions for the treatment of oral and oropharyngeal cancers: surgical treatment. *Cochrane Database Syst Rev* 2011:CD006205.
29. Karatzanis AD, Psychogios G, Mantsopoulos K, et al. Management of advanced carcinoma of the base of tongue. *J Surg Oncol* 2012;106:713–718.
30. Rööslä C, Tschudi DC, Studer G, Braun J, Stoeckli SJ. Outcome of patients after treatment for a squamous cell carcinoma of the oropharynx. *Laryngoscope* 2009;119:534–540.
31. Psychogios G, Mantsopoulos K, Kuenzel J, et al. Primary surgical treatment of T2 oropharyngeal carcinoma. *J Surg Oncol* 2012;105:719–723.
32. Po Wing Yuen A, Lam KY, Lam LK, et al. Prognostic factors of clinically stage I and II oral tongue carcinoma — a comparative study of stage, thickness, shape, growth pattern, invasive front malignancy grading, Martínez-Gimeno score, and pathologic features. *Head Neck* 2002;24:513–520.
33. Huang SH, Hwang D, Lockwood G, Goldstein DP, O'Sullivan B. Predictive value of tumor thickness for cervical lymph-node involvement in squamous cell carcinoma of the oral cavity: a meta-analysis of reported studies. *Cancer* 2009;115:1489–1497.
34. Pentenero M, Gandolfo S, Carozzo M. Importance of tumor thickness and depth of invasion in nodal involvement and prognosis of oral squamous cell carcinoma: a review of the literature. *Head Neck* 2005;27:1080–1091.
35. Fukano H, Matsuura H, Hasegawa Y, Nakamura S. Depth of invasion as a predictive factor for cervical lymph node metastasis in tongue carcinoma. *Head Neck* 1997;19:205–210.
36. Ihloff AS, Petersen C, Hoffmann M, Knecht R, Tribius S. Human papilloma virus in locally advanced stage III/IV squamous cell cancer of the oropharynx and impact on choice of therapy. *Oral Oncol* 2010;46:705–711.
37. Shoustari A, Meenehan M, Sheng K, et al. Intensity-modulated radiotherapy outcomes for oropharyngeal squamous cell carcinoma patients stratified by p16 status. *Cancer* 2010;116:2645–2654.
38. Lassen P, Eriksen JG, Hamilton-Dutoit S, Tramm T, Alsner J, Overgaard J. Effect of HPV-associated p16INK4A expression on response to radiotherapy and survival in squamous cell carcinoma of the head and neck. *J Clin Oncol* 2009;27:1992–1998.
39. Ambrosch P, Kron M, Pradier O, Steiner W. Efficacy of selective neck dissection: a review of 503 cases of elective and therapeutic treatment of the neck in squamous cell carcinoma of the upper aerodigestive tract. *Otolaryngol Head Neck Surg* 2001;124:180–187.
40. Strojjan P, Ferlito A, Langendijk JA, Silver CE. Indications for radiotherapy after neck dissection. *Head Neck* 2012;34:113–119.
41. Moerigel M, Jahn-Eimermacher A, Krummenauer F, et al. Effectiveness of adjuvant radiotherapy in patients with oropharyngeal and floor of mouth squamous cell carcinoma and concomitant histological verification of singular ipsilateral cervical lymph node metastasis (pN1-state) — a prospective multicenter randomized controlled clinical trial using a comprehensive cohort design. *Trials* 2009;10:118.
42. Rodrigo JP, Shah JP, Silver CE, et al. Management of the clinically negative neck in early-stage head and neck cancers after transoral resection. *Head Neck* 2011;33:1210–1219.
43. Psychogios G, Mantsopoulos K, Bohr C, et al. Incidence of occult cervical metastasis in head and neck carcinomas: Development over time. *J Surg Oncol* 2012; doi: 10.1002/jso.23221. [Epub ahead of print].