

Conflict of interest
None.

Noninvasive diagnosis in dermatology

Julia Welzel, Sandra Schuh

Department of Dermatology and
Allergology, Augsburg Medical Center,
Augsburg, Germany

Summary

In addition to dermoscopy, there are other imaging and biophysical methods for the noninvasive diagnosis of skin lesions. Confocal laser microscopy allows for high-resolution imaging of the epidermis and upper dermis. It is particularly suitable in the differential diagnosis of melanocytic lesions. Optical coherence tomography (OCT) has a lower resolution compared to confocal laser microscopy but a greater depth of penetration. It is primarily used for imaging epithelial skin cancer, especially in the context of monitoring the effectiveness of nonsurgical therapies. Electrical impedance spectroscopy does not yield cutaneous images but rather provides a score based on the cellular irregularity of the skin. Multispectral analysis involves illumination of the skin with different wavelengths and likewise results in the computation of a score. Both methods are used in the differentiation of dysplastic nevi from melanoma. Other diagnostic imaging and biophysical methods are currently still in the developmental stages.

By increasing the sensitivity and specificity of clinical and dermoscopic findings, the aforementioned methods bring about an improvement in noninvasive diagnosis. They allow for skin lesions to be monitored over time and therapeutic effects to be quantified. Finally, they facilitate early diagnosis of skin cancer, and help avoid unnecessary surgery of benign lesions.

Introduction

For many years, dermoscopy and ultrasound were the only imaging methods available to dermatologists. Compared to other medical specialties, the need for imaging of the skin is naturally much lower, given that skin lesions can be visually assessed with the naked eye. However, clinical diagnostic measures are limited by their low resolution and depth of penetration. In case of doubt, a biopsy must be taken, which is time-consuming and invasive.

Indispensable in many cases, dermoscopy is the most important diagnostic tool; its significant role has been confirmed for a wide range of clinical situations. Ultrasound is used in the diagnosis of lymph node involvement during melanoma follow-up. High-frequency ultrasound of the skin, however, has not gained

Indispensable in many cases, dermoscopy is the most important diagnostic tool; its significant role has been confirmed for a wide range of clinical situations.

20-MHz ultrasound is still occasionally used for measuring tumor thickness and for monitoring the course of connective tissue disorders.

widespread clinical acceptance, given that the lack of resolution in the epidermis and dermis does not allow for the differentiation of tumors. 20-MHz ultrasound is still occasionally used for measuring tumor thickness and for monitoring the course of connective tissue disorders. Other radiological methods such as CT or MRI are more suitable for the visualization of deeper than superficial structures. Moreover, they are more expensive, and their resolution is too low.

In recent years, numerous new diagnostic methods have been developed in the field of dermatology. These include imaging procedures and physical methods that evaluate lesions and provide diagnostic data in an automated manner.

New methods, especially in the field of oncology, have to prove themselves with regard to their diagnostic specificity and sensitivity; this process usually takes years. Establishing such new methods in the routine diagnosis of skin disorders also depends on many other factors such as price, possible applications, measurement time, practicability, ease with which the interpretation of the results can be learned, and – last but not least – billing options. Thus, it frequently takes many years for a method to become established. Some techniques never become commercially available because the development process takes too long and depletes the financial resources of medical technology companies.

In the following paragraphs, methods already established in everyday clinical practice will be discussed in detail. Other devices and new developments will only be touched upon briefly.

Confocal laser microscopy

Confocal laser microscopy enables high-resolution, noninvasive, real-time imaging of the epidermis and upper dermis at cellular resolution.

Confocal laser microscopy (CLM) has been used in routine clinical practice at some dermatology departments and by many office-based dermatologists since the 1990s. It enables high-resolution, noninvasive, real-time imaging of the epidermis and upper dermis at cellular resolution. Its primary field of application is the differential diagnosis of pigmented lesions.

Technology

The contrast in the CLM images is due to differences in reflection intensity.

Mavig (Munich, Germany) is currently the only supplier of CLM devices. The VivaScope® 1500 operates with an 830-nm laser. The skin is illuminated from above; for imaging, only that fraction of light is used that is reflected from a defined plane and reaches the detector through an aperture diaphragm. This results in high-resolution horizontal images. The contrast in the CLM images is due to differences in reflection intensity. Keratin, and especially melanin, show a strong reflection so that pigmented cells appear particularly bright. The individual images have a size of 500 µm x 500 µm. However, by moving the lens laterally, these images can be combined to form two-dimensional mosaics of up to 8 mm x 8 mm. The (horizontal) planes can be incrementally moved downwards, with the images becoming increasingly blurred beyond a depth of 200 µm. The device also allows for the automatic creation of a stack of (a series of horizontal) images. The VivaScope is equipped with a polarized light camera, which enables a photo of the skin surface to be taken at the beginning of the imaging procedure, from which one can then navigate. The skin surface is fixed to the scanning head by an adhesive metal ring to reduce movement artifacts; it is attached to the scanning head through immersion oil, a transparent disc, and ultrasound gel.

There are various device modifications: a hand-held device with which one can record individual images, a multi-laser device with three different lasers for fluorescence diagnostics, and an *ex vivo* device (Table 1). Apart from structural

Table 1 Configuration of different devices for confocal laser microscopy.

Name	Laser	Image size	Area of application
VivaScope® 1500	830 nm	Individual image 500 µm × 500 µm, mosaic up to 8 mm × 8 mm	<i>In vivo</i> , reflection
VivaScope® 1500 Multiwave	488 nm, 658 nm, 785 nm	Individual image 500 µm × 500 µm, mosaic to 8 mm × 8 mm	<i>In vivo</i> , reflection and fluorescence
VivaScope® 3000	830 nm	Individual image 1000 µm × 1000 µm, no mosaic function	<i>In vivo</i> , reflection; for hard-to-access areas; for quick, flexible measurements
VivaScope® 2500	488 nm, 658 nm, 830 nm	750 µm × 750 µm, mosaic up to 20 mm × 20 mm	<i>Ex vivo</i> , reflection and fluorescence; for micrographic surgery, control of margins

Apart from structural imaging based on reflection, fluorescence diagnostics allow for the visualization of specific structures by adding exogenous fluorescent dyes.

imaging based on reflection, fluorescence diagnostics allow for the visualization of specific structures by adding exogenous fluorescent dyes. Examples of fluorescent dyes for *in vivo* diagnostics include sodium fluorescein, which can be applied topically or injected intradermally; acridine orange, which stains nuclei, has proven useful for *ex vivo* studies.

The resolution of all devices is 1 to 3 µm, and thus at the cellular level. Standardized imaging of a lesion consists of three mosaics at the level of the upper epidermis, the dermoepidermal junction, and the upper dermis as well as of three to four image stacks that appear relevant under polarized light. The entire documentation process takes approximately eight minutes per lesion.

Indications

In order to be able to correctly interpret the horizontal microscopic images, a definition of “normal skin” must first be established. In healthy skin, the stratum corneum shows large polygonal, highly reflective corneocytes. The epidermis underneath has a honeycomb appearance with uniform cells of the same size. Due to their pigment content, the cells in the basal layer appear bright, resulting in a cobblestone pattern (Figure 1). The dermoepidermal junction is characterized by rings of pigmented basal keratinocytes around a dark dermal papilla with central capillaries. Measurement is so fast that the flow of blood cells can be seen in dermal vessels. The collagenous and elastic fibers in the papillary layer appear as a network.

CLM is primarily used in the differential diagnosis of pigmented lesions.

CLM is primarily used in the differential diagnosis of pigmented lesions. Due to their pigmentation, nevi exhibit a uniform pattern of annular, well-defined papillae that, in the case of compound nevi, contain nests of melanocytes (Figure 2). By contrast, a chaotic pattern prevails in melanoma (Figure 3). Even in upper layers of the epidermis, there are bright, large, partly dendritic and partly round cells, which correspond to a pagetoid spread of ascending melanocytes. The dermoepidermal junction is destroyed and filled with atypical polymorphic cells; the annular pattern of the papillae is thus no longer detectable. In lentigo maligna and lentigo maligna melanoma (Figure 4), numerous bright cells with very long dendrites are arranged around the follicular ostia.

Large studies have shown that CLM allows for more accurate detection of initial melanomas than dermoscopy and, in particular, for the distinction between dysplastic nevi and melanoma.

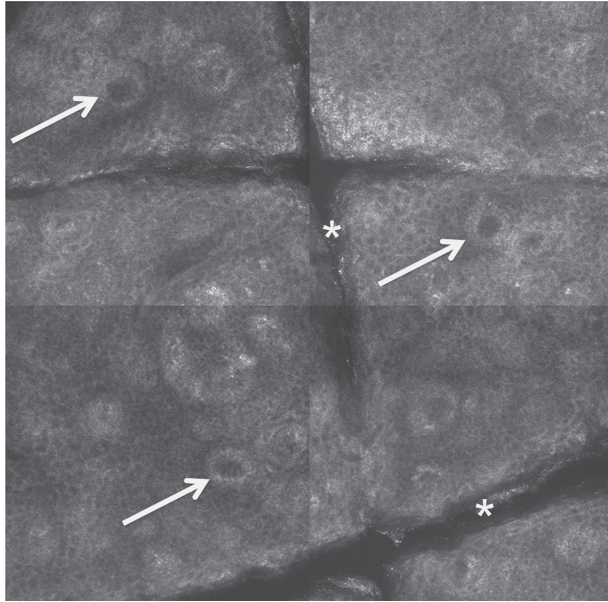


Figure 1 Confocal laser microscopy of healthy skin on the forearm; horizontal image at the level of the epidermis (1 mm x 1 mm). Skin grooves (stars) are visible. Keratinocytes are arranged in a regular honeycomb pattern. Rings of bright basal cells surround the dermal papillae (arrows).

Large studies have shown that CLM allows for more accurate detection of initial melanomas than dermoscopy and, in particular, for the distinction between dysplastic nevi and melanoma. Employing CLM can thus reduce the excision rate

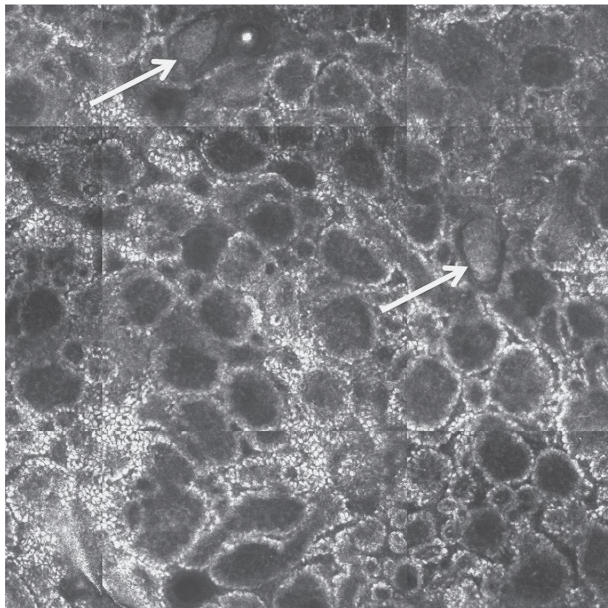


Figure 2 Confocal laser microscopy of a compound nevus on the thigh; horizontal image at the level of the dermoepidermal junction (1 mm x 1 mm). Due to its pigment content, the bright basal layer of the epidermis exhibits a cobblestone pattern. The papillae are annular and well-defined, containing isolated nests of melanocytes (arrows).

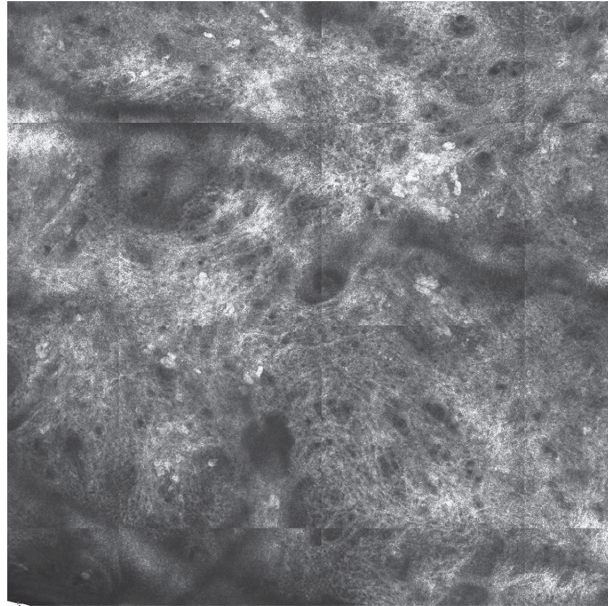


Figure 3 Confocal laser microscopy of a melanoma (trunk); horizontal image at the level of the dermoepidermal junction (1 mm x 1 mm). Numerous bright atypical, partly dendritic cells are found in the epidermis. The normal papillary architecture is replaced by a chaotic pattern.

of benign vs. malignant lesions (number needed to excise) [1, 2]. Using the hand-piece, the margins of a lentigo maligna can also be better visualized compared to dermoscopy, even in nonpigmented extensions.

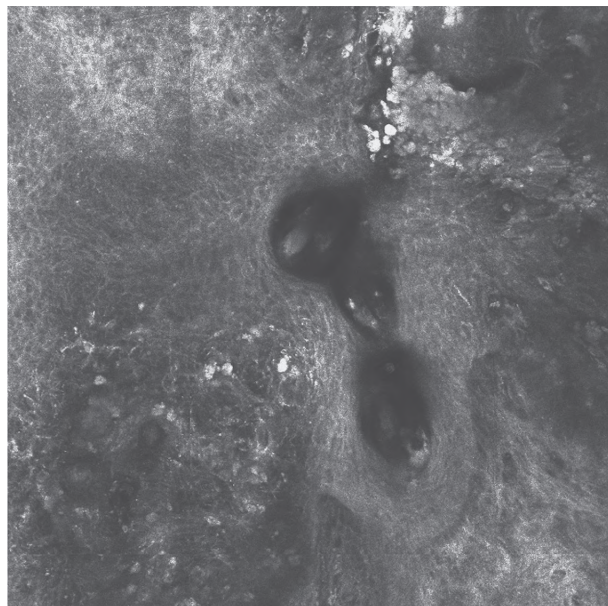


Figure 4 Confocal laser microscopy of a lentigo maligna melanoma on the face; horizontal image at the level of the dermoepidermal junction (1 mm x 1 mm). Perifollicularly, there are bright atypical, partly dendritic cells.



Figure 5 Confocal laser microscopy of Bowen's disease (cheek); horizontal image at the level of the upper epidermis (1 mm x 1 mm). The stratum corneum shows bright reflections and some parakeratotic cells. Below this irregular honeycomb pattern of the epidermis.

The penetration depth of the signal is insufficient to determine the extent of tumor invasion.

While epithelial tumors too can be diagnosed with CLM, keratoses frequently pose a diagnostic challenge, as they cause shadow artifacts. In actinic keratoses and Bowen's disease, the epidermal honeycomb pattern is irregular (Figure 5). Invasive squamous cell carcinoma show brightly reflective horny masses in the upper dermis. The superficial dermal components of basal cell carcinoma are readily recognizable as highly characteristic cones with dark margins; moreover, they show peripheral palisading of cells and nuclear polarization (Figure 6). Deeper tumor components, on the other hand, only appear as dark silhouettes. The penetration depth of the signal is insufficient to determine the extent of tumor invasion.

Numerous inflammatory and infectious skin disorders have also been studied using CLM. Cutaneous lymphomas are characterized by intraepidermal cells (epidermotropism). Eczematous, psoriasiform, and lichenoid patterns of inflammation can be distinguished [3]. Blister formation in bullous autoimmune diseases can also be visualized. Larger pathogens such as fungal hyphae and scabies or demodex mites can be diagnosed *in vivo* without prior preparation of the skin. However, CLM has not yet been used in the routine diagnosis of inflammatory skin diseases as deeper infiltrates are not detectable, and the pattern is more difficult to assess due to the horizontal imaging.

CLM can also be used *ex vivo* on freshly excised tissue; no tissue fixation is required. However, pretreatment with acetic acid or citric acid increases the contrast, and fluorescence staining, for example, with acridine orange (for nuclear staining) allows for better differentiation between epithelial tumors and the surrounding stroma. The tissue is placed on its side and scanned. Unlike *in vivo* CLM, this results in cross-sectional images similar to histological sections [4]. *Ex vivo* CLM is used in the context of micrographically controlled surgery for basal cell carcinoma (Figure 7).

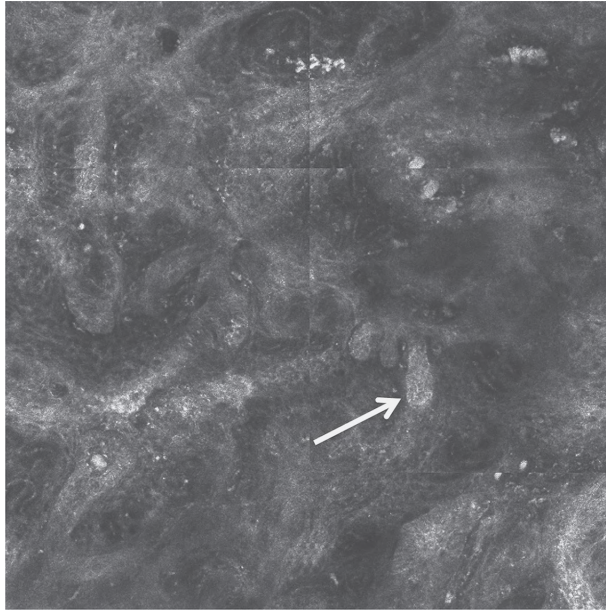


Figure 6 Confocal laser microscopy of a basal cell carcinoma; horizontal image at the level of the dermoepidermal junction (1 mm x 1 mm). Peripheral palisading of basaloid cells (arrow).

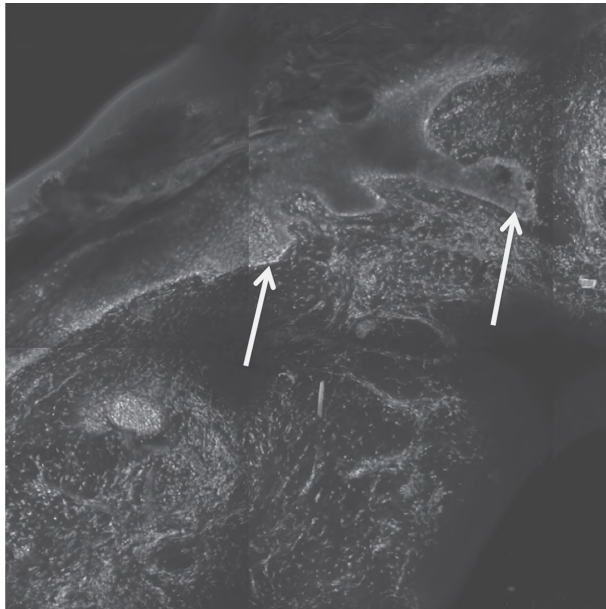


Figure 7 Ex vivo confocal laser microscopy of a superficial basal cell carcinoma; cross-sectional plane (1 mm x 1 mm). Tumor nodules (arrow) arising from the epidermis. Staining with acridine orange results in a bright fluorescent nuclear signal.

Optical coherence tomography

Optical coherence tomography (OCT) is a somewhat newer technique compared to CLM. First developed in the field of ophthalmology, it has been an established procedure of this specialty for more than 25 years. Given that the skin is a highly

Optical coherence tomography is primarily employed in the diagnosis of basal cell carcinoma.

dispersive medium, the technique had to be modified for dermatological purposes. In the meantime, OCT has also been routinely used at some dermatology departments and by a number of office-based dermatologists specialized in the diagnosis of cutaneous tumors in Germany. It is primarily employed in the diagnosis of basal cell carcinoma.

Technology

OCT provides real-time cross-sectional images of the skin with a penetration depth of 1 to 1.5 mm and a resolution of less than 10 μm .

OCT is an interferometric procedure. The skin is irradiated with broadband light from a super-luminescent diode, or an oscillating or tunable laser. The light reflected from the specimen can only interfere the light in the reference arm if both travel the same path length, that is to say they “meet” within the short coherence length. OCT provides real-time cross-sectional images of the skin with a penetration depth of 1 to 1.5 mm and a resolution of less than 10 μm . The images have a length of several millimeters and can be combined by moving the scanning head laterally to create three-dimensional blocks, which also allows for a simultaneous display of horizontal images.

A further technical advancement, dynamic OCT allows for simultaneous visualization of superficial blood vessels.

The VivoSight[®] from Michelson Diagnostics Ltd. (Maidstone, Kent, England) is currently the only commercially available CE-certified OCT device whose diagnostic accuracy has been investigated in large studies. No pretreatment of the skin is necessary. A flexible scanning head is manually placed on the site to be examined; a spacer ensures the optimum focal plane. A three-dimensional image, measuring 6 mm x 6 mm, can be recorded in 30 seconds. A further technical advancement, dynamic OCT allows for simultaneous visualization of superficial blood vessels. This method does not utilize the Doppler effect but rather involves rapid, repetitive scanning of the same site, which enables the detection of moving pixels that correspond to cellular blood components.

The SKINTELL by AGFA (Belgium) was another OCT device that provided a higher resolution with a smaller field of view and a lower penetration depth; however, that device is currently unavailable. A portable device combining both dermoscopy and OCT (NITID by DermaLumics, Madrid, Spain) is available on the market. This device is currently in its final stages of development and optimization. For many years, the Thorlabs company from Lübeck, Germany, has been offering OCT devices for dermatological purposes assembled according to customer specifications. In addition to the basic unit, several scanners – among them a hand-held device – several scanning lenses, reference length adapters, spacers, and other accessories are offered. However, these devices are not CE-certified so they can only be used in experimental studies (Table 2). The latest development in OCT is from the DAMAE company who will introduce the OLIV system in the coming years. It promises a high resolution comparable to that of CLM devices, with vertical imaging and a medium penetration depth (approximately 800 μm).

Indications

With respect to OCT too, knowledge of the appearance of healthy skin is essential in order to be able to assess pathological changes. The corneal layer in glabrous skin presents as a broad, homogeneous, wavy layer interrupted by helical sweat gland ducts (Figure 8). In hairy skin, the corneal layer is so thin that it appears as a narrow double line. Beneath, the epidermis presents as a narrow band, separated from the dermis by a dark line. The papillary dermis shows a stronger signal. In the reticular dermis, lymphatic and blood vessels can be detected as oblong or round cavities with a low signal. Due to the moving blood flow, blood vessels appear

Table 2 Devices for optical coherence tomography.

System	Resolution	Penetration depth	Field of view	Remarks
VivoSight DX (Michelson Diagnostics)	Lateral < 7.5 μm , axial < 5 μm	1.5 mm	Cross-sectional plane 6 mm x 2 mm En face 6 mm x 6 mm	Dynamic OCT with vascular imaging; comprehensive data available
SKINTELL (AGFA)	Lateral 3 μm , axial 3 μm	< 750 μm	Cross-sectional plane 1.8 mm x 0.75 mm En face 1.8 mm x 1.5 mm	Not currently available; comprehensive data available
Callisto (Thorlabs)	Lateral 8 μm , axial < 7 μm	1.5 mm	Cross-sectional plane 10 mm x 1.9 mm	Not CE-certified; only experimental studies
NITID (Dermalumics)	Lateral 12 μm , axial 11 μm	1.5 mm	Cross-sectional plane 9 mm x 1.5 mm	No studies to date

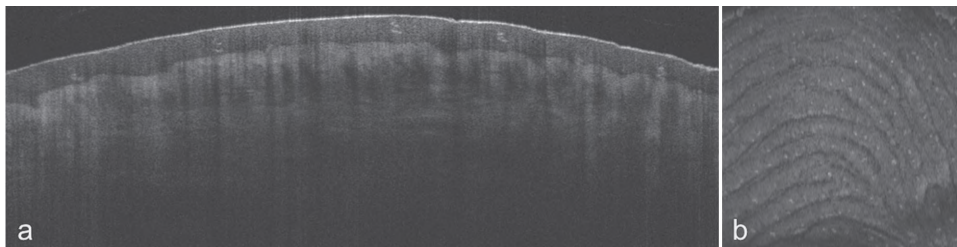


Figure 8 Optical coherence tomography of healthy skin (fingertip); cross-sectional image, (6 mm x 2 mm) (a) and horizontal image (6 mm x 6 mm) (b). The uppermost broad layer is the stratum corneum with helical sweat gland ducts. The horizontal image shows the ridges of the fingerprint with eccrine ostia.

Due to the moving blood flow, blood vessels appear as a color-coded red network on dynamic OCT (horizontal view).

OCT is primarily used in the diagnosis of epithelial skin tumors, in particular basal cell carcinoma.

Based on epidermal thickness, signal intensity, and the aforementioned morphological criteria, OCT allows for highly accurate distinction between actinic keratosis and basal cell carcinoma.

as a color-coded red network on dynamic OCT (horizontal view). In general, the subcutaneous adipose tissue cannot be visualized.

OCT is primarily used in the diagnosis of epithelial skin tumors, in particular basal cell carcinoma. Large studies have shown that basal cell carcinomas are characterized by signal-poor, sharply demarcated tumor nodules surrounded by characteristic dark rims [5]. Frequently, nodular basal cell carcinomas exhibit dark cysts at the center of the tumor nodules (Figure 9). Several subtypes can be distinguished. In the case of superficial basal cell carcinomas, there are numerous cell clusters branching off from the epidermis (Figure 10), especially on 3D scan, whereas the findings in sclerosing basal cell carcinoma are reminiscent of a school of fish, with small, signal-poor ovoid structures.

On the other hand, actinic keratoses exhibit marked – often multilayered – thickening of the stratum corneum. The epidermis is frequently acanthotic (Figure 11). In invasive squamous cell carcinoma, the dermoepidermal junction is no longer intact.

Based on epidermal thickness, signal intensity, and the aforementioned morphological criteria, OCT allows for highly accurate distinction between actinic keratosis and basal cell carcinoma [6]. When adding dynamic OCT, vascular patterns can also be used for diagnosis [7]. In basal cell carcinoma, large horizontal telangiectases accompany the tumor nodules, whereas actinic keratoses often show a chaotic pattern of dotted and comma vessels.

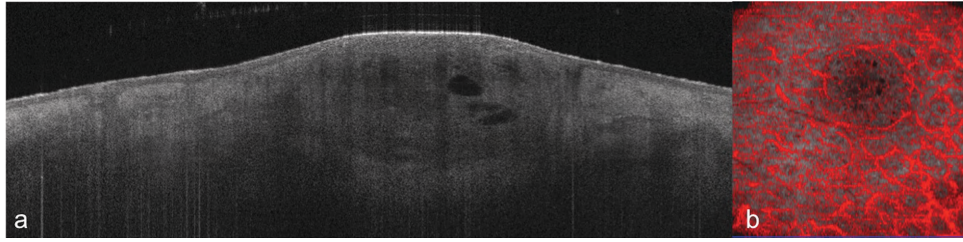


Figure 9 Optical coherence tomography of a nodular basal cell carcinoma; cross-sectional image (6 mm x 2 mm) (a) and horizontal image (dynamic OCT, 6 mm x 6 mm) (b). The tumor appears as a sharply demarcated nodule with a dark rim underneath an atrophic epidermis. Inside the tumor, there are some signal-free cysts. Using dynamic OCT, the vessels surrounding the tumor are displayed in red.

Given its low resolution, OCT is not yet suitable for the differential diagnosis of melanocytic lesions, although the vascular pattern can also provide valuable clues with respect to potential malignancy (Figures 12, 13).

Dynamic OCT offers several options for more experimental research. It has been used to visualize and quantify subtle physiological changes in blood flow as well as drug effects. For example, vasoconstriction of superficial blood vessels on the cheeks following topical treatment with brimonidine gel (0.33 %) has been demonstrated in rosacea patients as well as healthy individuals [8]. OCT can also be employed in the follow-up of wounds as well as for the evaluation of therapeutic effects in connective tissue disorders and the quantification of drug-related side effects such as steroid atrophy.

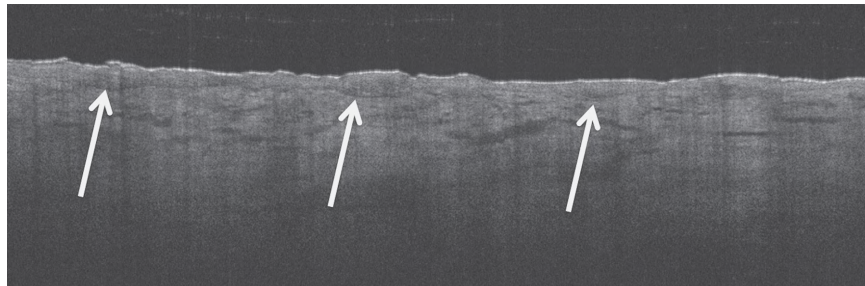


Figure 10 Optical coherence tomography of a superficial basal cell carcinoma; cross-sectional image (6 mm x 2 mm). The tumor cell clusters can be seen as superficial protrusions of the epidermis into the dermis, surrounded by a dark rim (arrows).

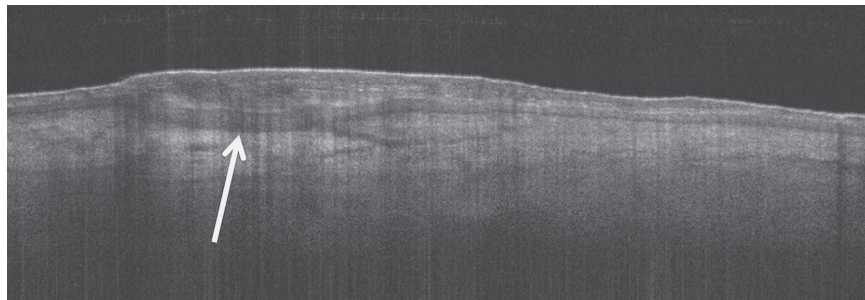


Figure 11 Optical coherence tomography of an actinic keratosis; cross-sectional image (6 mm x 2 mm). The stratum corneum shows marked, multilayered thickening. The dermoepidermal junction (arrow) is still intact.

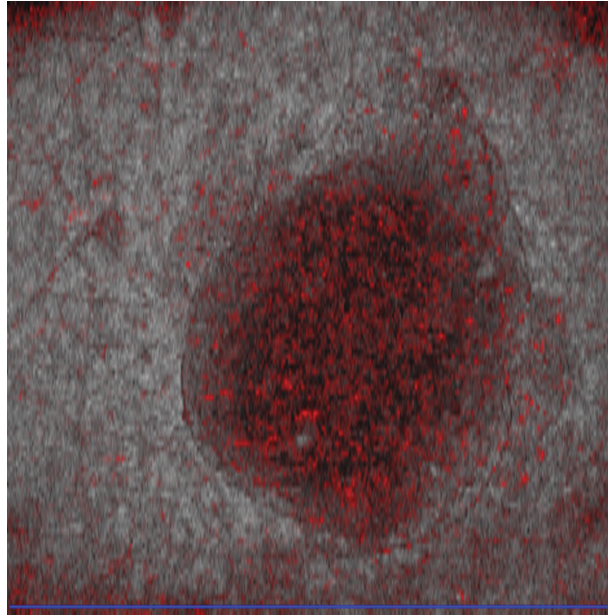


Figure 12 Dynamic OCT of a melanocytic nevus (chest); horizontal image (6 mm x 6 mm). The lesion shows regular dotted vessels.




Figure 13 Dynamic OCT of a melanoma (flank); horizontal image (6 mm x 6 mm). Here, the blood vessels are increased in number, dilated, polymorphic, and arranged in a chaotic pattern.

Electrical impedance spectroscopy

Electrical impedance spectroscopy (EIS) is not an imaging procedure. Based on the impedance pattern in the tumor, it enables conclusions to be drawn concerning the regular or irregular arrangement of cells. Accordingly, the method does not yield a

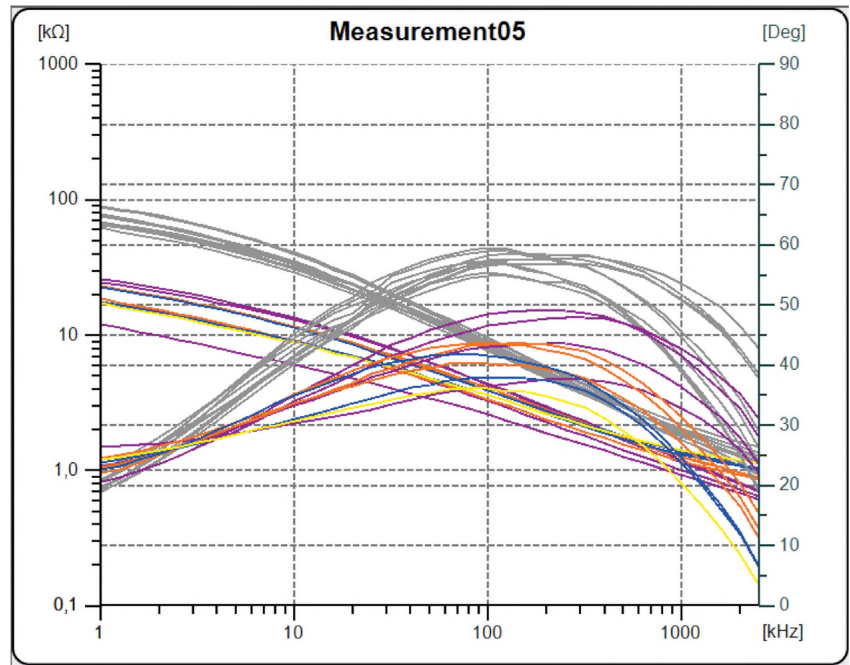
Electrical impedance spectroscopy is not an imaging method but rather yields a score that indicates the degree of cellular heterogeneity.

diagnosis but only a score that indicates the likelihood of malignancy. The method has been evaluated in multicenter studies on benign nevi and melanoma. The differentiation from other tumors such as basal cell carcinoma or seborrheic keratosis is not possible. Hence, EIS should only be used for melanocytic lesions.

Technology

The handheld probe contains numerous tiny spikes. After degreasing the skin, it is softly pressed onto the skin (without causing actual injury); the current flows between the spikes. The flow of the current is influenced by the properties of the cells between and underneath the spikes. If the arrangement, size, and type of the cells are regular, the recorded curves are also regular. Tumor cells, on the other hand, are characterized by irregular curves due to their polymorphism. From these curves, the system calculates a score that reflects the degree of abnormality of the lesion. The device has been calibrated using histologically confirmed nevi, dysplastic nevi, and melanomas. It is designed to be highly sensitive at the expense of its specificity in order to avoid misdiagnosis of melanoma as a benign lesion. Along with the score, the device indicates the likelihood of a lesion being malignant (Figure 14).

From these curves, the system calculates a score that reflects the degree of abnormality of the lesion.



8



Figure 14 Electrical impedance spectroscopy (EIS) of a dysplastic melanocytic nevus. The upper diagram demonstrates the curves compared to the adjacent healthy skin. The calculated score (below) of 8 is markedly elevated.

Limitations of this method include areas that do not permit measurement for anatomical reasons, such as the hairy scalp, palms and soles, curved surfaces as well as very soft, pliable skin such as on the abdomen.

Indications

EIS is suitable and designed for differentiating benign from malignant melanocytic lesions.

EIS is suitable and designed for differentiating benign from malignant melanocytic lesions. The measurement is not meant to result in a diagnosis; rather, it is used to evaluate a melanocytic lesion that has previously been examined on clinical grounds and/or by dermoscopy. EIS is very well suited for the detection of early melanomas in patients with multiple dysplastic nevi [9]. It is also possible to monitor lesions over time, and to see whether the score changes towards malignancy. Ulceration, inflammation, or post-biopsy scar tissue greatly limit the validity of this procedure. Thus, lesions associated with changes of the skin surface should not be examined.

Although EIS can also be used for the assessment of epithelial tumors (benign vs. malignant), it does not allow for the distinction between different tumor entities, nor between seborrheic keratoses and melanocytic nevi or melanomas. Interpretation of the scores should therefore always be conducted in the context of clinical and dermoscopic findings and consider potential differential diagnoses.

Other methods

Multiphoton tomography

Multiphoton tomography does not only display structural changes but also provides information on physiological and pathophysiological (functional) processes in the skin.

Multiphoton tomography (MPT) is a high-resolution imaging method. MPT is currently still time-consuming and also very expensive due to the complex technology involved. Studies conducted to date are therefore still experimental. There is, however, evidence from studies on healthy subjects as well as on patients showing that serial measurements too are possible. It is safe to say that the diagnostic potential of this method is very high, as it allows for the visualization of dynamic biochemical and pathophysiological processes at the subcellular level, which can be achieved with no other method. While MPT is similar to confocal laser microscopy, the images generated are not the result of simple reflection of light but caused by two other phenomena. Following two- or multiphoton excitation, autofluorescence of endogenous fluorophores generates a fluorescent signal that is detected. In addition, interaction between the light and individual molecules results in frequency doubling, which, for example, provides indications as to the quality of the skin's fiber network. Moreover, conclusions with respect to the microenvironment can be drawn by measuring the fluorescence lifetime. Most recent developments facilitate the visualization of intradermal water and lipid molecules through coherent anti-Stokes Raman spectroscopy (CARS). Thus, MPT does not only display structural changes but also provides information on physiological and pathophysiological (functional) processes in the skin.

The resolution is at the subcellular level (1 μm). Similar to confocal laser microscopy, the penetration depth is limited to approximately 200 μm .

DermaInspect® (JenLab GmbH, Jena, Germany) is a CE-certified multiphoton tomography device, with various modifications for multimodal imaging (DermaInspect® CARS-MPT or MPTflex™ CARS).

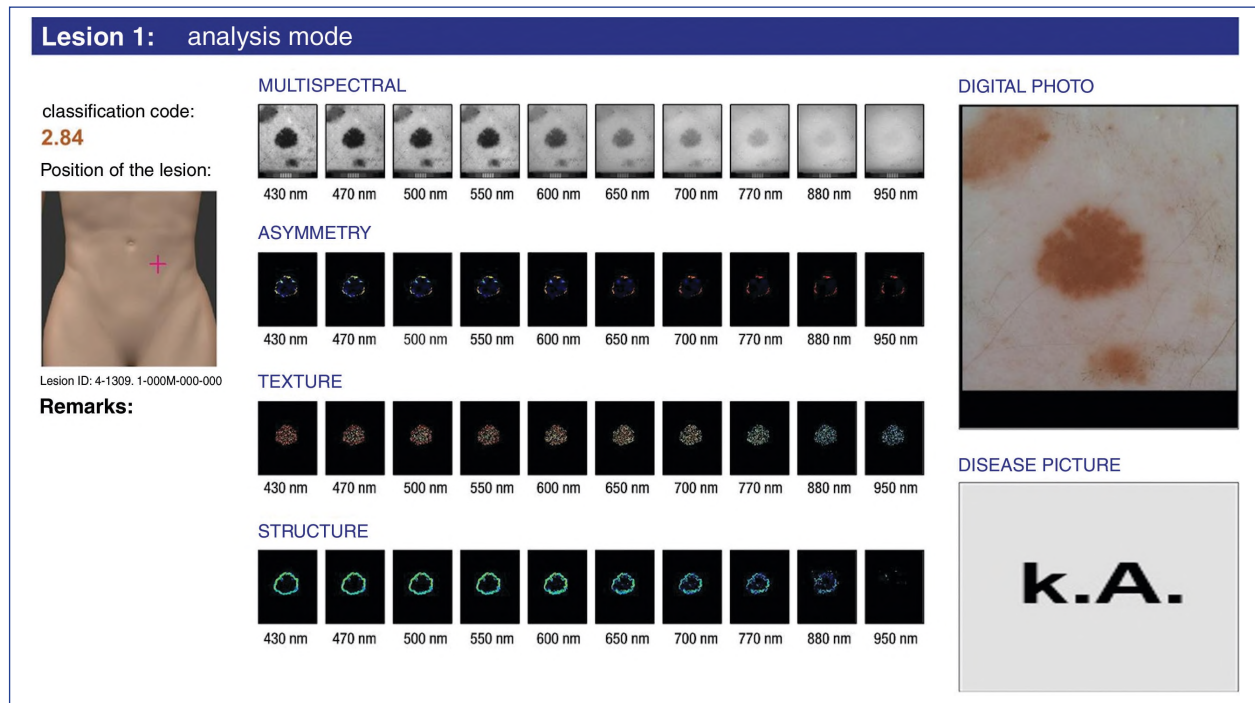


Figure 15 MelaFind analysis of a dysplastic nevus. The device automatically calculates symmetry, border, pigment distribution, and other parameters at various levels of the lesion. Assessment is based on a score, which, in this case, is elevated (2.84).

Multispectral analysis

Similar to dermoscopy, multispectral analysis involves illumination of the skin, however, with multiple wavelengths. Horizontal images from various tissue levels are automatically analyzed for color distribution, symmetry, and patterns. Initially, such individual findings merely resulted in the indication whether the lesion showed structural disorganization and thus was conspicuous or not. Subsequent technological advances have made it possible to obtain a classifier score that indicates the likelihood of a lesion being a melanoma (Figure 15). Given that this method does not allow for the differentiation between melanocytic and non-melanocytic lesions, it is imperative that the lesions to be examined be preselected using dermoscopy. Interpretation of the score should also take into account “historic” parameters such as the duration of the lesion and any observed changes. The cutoff for the score is designed to achieve the highest possible sensitivity at the expense of specificity. Consequently, the goal is not to overlook any potential melanoma, while having to accept that the score will “recommend” the excision of many dysplastic nevi. Hence, multispectral analysis can be used as a screening tool in patients with multiple dysplastic nevi in order to detect any particularly conspicuous lesions [10]. Another option is to conduct repeated short-term measurements – as in sequential video dermoscopy – and to observe whether and in what way the score changes.

MelaFind® used to be a commercially available multispectral analysis device. In Germany, marketing and support were recently discontinued.

Multispectral analysis can be used as a screening tool in patients with multiple dysplastic nevi in order to detect any particularly conspicuous lesions.

Raman spectroscopy

One application of Raman spectroscopy is *in vivo* detection of antioxidants in the skin.

Raman spectroscopy is an optical method that studies the inelastic scattering of light from molecules or solid objects, and allows for selective detection of substances in the skin. Using a resonance effect, it is even possible to specifically detect minute amounts of molecules. One application of Raman spectroscopy is *in vivo* detection of antioxidants in the skin. There are also a few experimental studies as regards the diagnosis of skin cancer. Given its somewhat mediocre selectivity, combining Raman spectroscopy with any kind of imaging method offers an interesting prospect. For a short period of time, the Raman spectrometer Verisante® was commercially available in Germany; this, however, is no longer the case.

Optoacoustic imaging

In dermatology, multispectral optoacoustic tomography has already been used in pilot studies on the detection and noninvasive diagnosis of sentinel lymph nodes.

A new and innovative development in dermatology is optoacoustic imaging (multispectral optoacoustic tomography, or MSOT). Short laser pulses are used to cause thermo-elastic expansion of a dye. This expansion gives rise to ultrasound waves that can be recorded with a microphone. Apart from exogenous fluorescent dyes, endogenous dyes such as melanin can also be used for imaging. The sound wave pattern is converted into a high-resolution three-dimensional image.

In dermatology, MSOT has already been used in pilot studies on the detection and noninvasive diagnosis of sentinel lymph nodes [11]. The sentinel node can be detected with high accuracy. Even though it is also possible to detect small amounts of melanin pigment in lymph nodes, the method does not allow for the differentiation between melanophages, capsular nevi, and micrometastases of a melanoma. Larger studies will demonstrate whether negative findings render sentinel lymph node biopsies unnecessary. Currently, Acuity Echo (iThera, Munich, Germany) is the only MSOT device available.

Dermatofluoroscopy

In dermatofluoroscopy, imaging is based on the specific self-fluorescence of melanin in melanosomes.

In dermatofluoroscopy, imaging is based on the specific self-fluorescence of melanin in melanosomes. Albeit very small, such self-fluorescence can be largely selectively detected using the two-photon absorption method. Here, the spectra of normal melanocytes, nevomelanocytes, and melanoma cells are different. The pigmented lesion is scanned using a grid of multiple, tiny measuring points designed to only detect the spectrum of melanin. From the several hundred different spectra within the lesion, a score is determined that indicates whether the lesion is benign or malignant.

The Magnosco DFC1 dermatofluoroscope (Magnosco GmbH, Berlin, Germany) is currently in the development stage. The procedure takes several minutes, and must be performed under a light-proof cover.

Conclusion

In dermatology, noninvasive diagnostic methods include imaging techniques that allow for noninvasive, real-time examination of the skin. While confocal laser microscopy has become an established modality in the diagnosis of melanocytic lesions, optical coherence tomography is routinely used in the diagnosis of basal cell carcinoma. Compared to dermatoscopy, both methods increase sensitivity and specificity and may be used for early detection; in some cases, they can help prevent biopsies. Other imaging methods are still in a more experimental stage of

While confocal laser microscopy has become an established modality in the diagnosis of melanocytic lesions, optical coherence tomography is routinely used in the diagnosis of basal cell carcinoma.

development. Procedures not used in the diagnosis but rather for the differential diagnosis of pigmented lesions include methods that assess structural abnormalities of a lesion by providing a score. In this context, electrical impedance spectroscopy has already become well established.

The field of diagnostic methods in dermatology is currently undergoing rapid evolution. It is to be expected that novel methods or combinations thereof will further enhance the assessment of many parameters such as resolution and penetration depth, sensitivity, specificity, and selectivity, thus facilitating true “optical biopsies”.

References

- 1 Xiong YD, Ma S, Li X et al. A meta-analysis of reflectance confocal microscopy for the diagnosis of malignant skin tumours. *J Eur Acad Dermatol Venereol* 2016; 30: 1295–302.
- 2 Borsari S, Pampena R, Lallas A et al. Clinical indications for use of reflectance confocal microscopy for skin cancer diagnosis. *JAMA Dermatol* 2016; 152: 1093–8.
- 3 Ardigo M, Longo C, Gonzalez S. Multicentre study on inflammatory skin diseases from The International Confocal Working Group: specific confocal microscopy features and an algorithmic method of diagnosis. *Br J Dermatol* 2016; 175: 364–74.
- 4 Welzel J, Kästle R, Sattler EC. Fluorescence (Multiwave) Confocal Microscopy. *Dermatol* 2016; Clin 34: 527–33.
- 5 Ulrich M, von Braunmuehl T, Kurzen H et al. The sensitivity and specificity of optical coherence tomography for the assisted diagnosis of nonpigmented basal cell carcinoma: an observational study. *Br J Dermatol* 2015; 173: 428–35.
- 6 Schuh S, Kaestle R, Sattler EC et al. Optical coherence tomography of actinic keratoses and basal cell carcinomas – differentiation by quantification of signal intensity and layer thickness. *J Eur Acad Dermatol Venereol* 2016; 30: 1321–6.
- 7 Ulrich M, Themstrup L, de Carvalho N et al. Dynamic Optical Coherence Tomography in Dermatology. *Dermatology* 2016; 232: 298–311.
- 8 Themstrup L, Ciardo S, Manfredi M et al. In vivo micro-morphological vascular changes induced by topical brimonidine studied by dynamic optical coherence tomography. *J Eur Acad Dermatol Venereol* 2016; 30: 974–9.
- 9 Malvey J, Hauschild A, Curiel-Lewandrowski C et al. Clinical performance of the Nevisense system in cutaneous melanoma detection: an international, multicentre, prospective and blinded clinical trial on efficacy and safety. *Br J Dermatol* 2014; 171: 1099–107.
- 10 Hauschild A, Chen SC, Weichenthal M et al. To excise or not: impact of MelaFind on German dermatologists’ decisions to biopsy atypical lesions. *J Dtsch Dermatol Ges* 2014; 12: 606–14.
- 11 Stoffels I, Morscher S, Helfrich I et al. Metastatic status of sentinel lymph nodes in melanoma determined noninvasively with multispectral optoacoustic imaging. *Sci Transl Med* 2015; 7: 317ra199.

Correspondence to

Prof. Dr. med. Julia Welzel
Department of Dermatology and
Allergology
Augsburg Medical Center

Sauerbruchstraße 6
86179 Augsburg, Germany

E-mail: julia.welzel@klinikum-
augsburg.de

Fragen zur Zertifizierung durch die DDA

1. Welche Aussage zur konfokalen Lasermikroskopie ist falsch?

- a) Die konfokale Lasermikroskopie liefert Tiefenschnittbilder der Haut in Echtzeit.
 - b) Die Bilder werden durch Lateralverschiebung zu zweidimensionalen Übersichtsbildern von mehreren Quadratmillimetern zusammengesetzt.
 - c) Die In-vivo-Bildgebung zeigt Einzelzellen der Epidermis.
 - d) Für Übersichtsbilder muss der Messkopf an der Hautoberfläche fixiert werden.
 - e) Die Eindringtiefe ist limitiert auf die obere Dermis.
-

2. Welche Aussage zur konfokalen Lasermikroskopie ist richtig?

- a) Die konfokale Lasermikroskopie eignet sich zum schnellen Screening multipler atypischer Pigmentläsionen.
 - b) Panniculitiden können mittels konfokaler Lasermikroskopie diagnostiziert werden.
 - c) Die In-vivo-Bildgebung erfordert eine vorherige Anfärbung der Haut.
 - d) Die konfokale Lasermikroskopie ermöglicht eine Beurteilung der Einzelzellmorphologie von Keratinozyten.
 - e) Zur ex vivo konfokalen Lasermikroskopie muss das Gewebe mit Formalin fixiert werden.
-

3. Welche Aussage zur konfokalen Lasermikroskopie ist falsch?

- a) Sie eignet sich zur Differenzialdiagnose von melanozytären Läsionen.
- b) Melanozytäre Nävi zeigen ein regelmäßiges Ringmuster dermalen Papillen.
- c) Maligne Melanome weisen im Stratum spinosum dendritische Melanozyten auf.
- d) Die Tumordicke kann mittels konfokaler Lasermikroskopie vermessen werden.

- e) Dermale Nester von Compound-Nävi sind in der konfokalen Lasermikroskopie in den Papillen erkennbar.
-

4. Welche Aussage zur konfokalen Lasermikroskopie ist falsch?

- a) Basalzellkarzinome sind unscharf begrenzte Tumorknoten mit Hornperlen.
 - b) Aktinische Keratosen zeigen ein atypisches Wabenmuster in der Epidermis.
 - c) Keratosen behindern die Bildgebung durch Signalschatten.
 - d) Basalzellkarzinome weisen oft typische erweiterte Blutgefäße mit langsamem Blutfluss auf.
 - e) Die Infiltrationstiefe von Basalzellkarzinomen lässt sich mittels konfokaler Lasermikroskopie nicht bestimmen.
-

5. Welche Aussage zur optischen Kohärenztomographie (OCT) ist falsch?

- a) Mittels OCT können dynamische Veränderungen wie Blutfluss sichtbar gemacht werden.
 - b) Der Messkopf muss an der Haut fixiert werden, da bei der langsamen Messung sonst Bewegungsartefakte entstehen.
 - c) Die OCT zeigt Tiefenschnittbilder der Haut bis in die mittlere Dermis.
 - d) Eine Vorbehandlung der Haut ist nicht erforderlich.
 - e) Die OCT eignet sich zur Diagnostik der Feldkanzerisierung.
-

6. Welche Aussage zur optischen Kohärenztomographie (OCT) ist richtig?

- a) Die OCT ermöglicht eine Beurteilung zellulärer Atypien.
- b) Die OCT eignet sich zur Differenzialdiagnostik melanozytärer Läsionen.
- c) Eine simultane Darstellung horizontaler und vertikaler Schnittbilder ist nicht möglich.

- d) Der Messkopf ist so groß, dass es schwierig ist, an der Nase oder im Augenwinkel zu messen.
 - e) Aktinische Keratosen lassen sich von Basalzellkarzinomen differenzieren.
-

7. Welche Aussage zur optischen Kohärenztomographie (OCT) ist falsch?

- a) Knotige Basalzellkarzinome zeigen oft zentral signalarme Zysten.
 - b) Superfizielle Basalzellkarzinome stellen sich durch Zapfen, die von der Epidermis ausgehen, dar.
 - c) Die Dicke von Basalzellkarzinomen lässt sich meist nicht vermessen.
 - d) Die seitlichen Grenzen von Basalzellkarzinomen sind meist gut detektierbar.
 - e) Fibrosierende Basalzellkarzinome bestehen aus unscharf begrenzten Arealen mit multiplen signalarmen Strängen.
-

8. Welche Aussage zur elektrischen Impedanzspektroskopie (EIS) ist falsch?

- a) An den Bildern der EIS lassen sich Inhomogenitäten optisch beurteilen.
 - b) Während der Messungen werden Spikes in die Hautoberfläche gedrückt.
 - c) Eine Unterscheidung zwischen malignen Melanomen und Plattenepithelkarzinomen ist nicht möglich.
 - d) Die EIS liefert einen Score, der die Wahrscheinlichkeit für das Vorliegen eines malignen Melanoms wiedergibt.
 - e) Die Höhe des Scores korreliert mit dem Risiko für Malignität.
-

9. Welche Aussage zu bildgebenden Methoden ist richtig?

- a) Die konfokale Lasermikroskopie ermöglicht eine Messung der Dermisdicke.
- b) Die optische Kohärenztomographie erlaubt eine Differenzierung von Zellen.

- c) Die Multiphotonentomographie benötigt exogene Fluorophore zur Bildgebung.
 - d) Die optische Kohärenztomographie hat eine höhere Eindringtiefe als die hochfrequente 20-MHz-Sonographie.
 - e) Mit der konfokalen Lasermikroskopie lassen sich Veränderungen des Stratum corneum und der Corneozyten untersuchen.
-
- 10. Welche Aussage zu physikalischen Messmethoden ist falsch?**
- a) Sie liefern Messwerte, die Hinweise auf Inhomogenitäten im Gewebe geben.
 - b) Sie eignen sich zum Screening pigmentierter Läsionen.
 - c) Sie erlauben eine Differenzialdiagnostik zwischen verschiedenen Tumorentitäten.
 - d) Sie sind nur zur Beurteilung melanozytärer Läsionen zugelassen.
 - e) Sie haben eine hohe Sensitivität auf Kosten einer niedrigeren Spezifität.