



THE UNIVERSITY *of* EDINBURGH

Edinburgh Research Explorer

Predominant Spastic Paraparesis Associated With the D178N Mutation in PRNP

Citation for published version:

Thams, S, Paucar, M, Wingård, L, Thonberg, H, Smith, C, Nennesmo, I & Svenningsson, P 2021, 'Predominant Spastic Paraparesis Associated With the D178N Mutation in PRNP', *Neurology Genetics*, vol. 7, no. 6, pp. e636. <https://doi.org/10.1212/NXG.0000000000000636>

Digital Object Identifier (DOI):

[10.1212/NXG.0000000000000636](https://doi.org/10.1212/NXG.0000000000000636)

Link:

[Link to publication record in Edinburgh Research Explorer](#)

Document Version:

Publisher's PDF, also known as Version of record

Published In:

Neurology Genetics

General rights

Copyright for the publications made accessible via the Edinburgh Research Explorer is retained by the author(s) and / or other copyright owners and it is a condition of accessing these publications that users recognise and abide by the legal requirements associated with these rights.

Take down policy

The University of Edinburgh has made every reasonable effort to ensure that Edinburgh Research Explorer content complies with UK legislation. If you believe that the public display of this file breaches copyright please contact openaccess@ed.ac.uk providing details, and we will remove access to the work immediately and investigate your claim.



Predominant Spastic Paraparesis Associated With the D178N Mutation in PRNP

Sebastian Thams, MD, PhD,* Martin Paucar, MD, PhD,* Louise Wingård, MD, PhD, Håkan Thonberg, PhD, Colin Smith, MD, PhD, Inger Nennesmo, MD, PhD, and Per Svenningsson, MD, PhD

Correspondence

Dr. Paucar
martin.paucar-arce@sl.se

Neurol Genet 2021;7:e636. doi:10.1212/NXG.0000000000000636

Spastic paraparesis is a very rare manifestation of prion diseases, occurring in both sporadic prion disease¹ and inherited prion disease.² The D178N mutation in the prion protein (*PRNP*) gene is associated with familial fatal insomnia (FFI) or familial Creutzfeldt-Jakob disease (fCJD),³ and in some cases, FFI and fCJD overlap.^{4,5} Herein, we describe a patient harboring the D178N mutation in *PRNP* with initially predominant spastic paraparesis.

Case Presentation

A 70-year-old woman was admitted due to increasing dyspnea starting 6 months before admission. Relatives reported progressive gait difficulties, personality change, and frequent falls starting 2 months before admission. There were no signs of insomnia, but apnea during sleep was reported. She was a former smoker, investigations demonstrated mild emphysema and reduced FEV1%, and the patient was diagnosed with mild COPD. Her saturation was normal (95%) during ambient air breathing. Recurrent desaturation during sleep was noticed, but polysomnography (PSG) was not performed. OSA was diagnosed on these grounds, and the patient was treated with bronchodilators and CPAP, which alleviated dyspnea. On examination, spastic paraparesis, hyperreflexia, clonus, Babinski and Hoffman signs, and abnormal Romberg test were found. The patient could stand up only with support and was prone to fall backward. Two months after motor onset, the patient became a wheelchair user. The patient had confusion and apraxia; the Montreal Cognitive Assessment yielded 11 points, but her rapid deterioration prevented further cognitive assessment. Dyspnea and dysarthria worsened; imperative auditory hallucinations and dysphagia appeared early on. MRI of the brain with contrast revealed widespread white matter hyperintensities (WMHs) in subcortical areas and an incidental anterior communicating artery aneurysm. The WMHs were interpreted as angiopathic. In the left cerebellar hemisphere, 2 older small infarctions were found; the thalamus and the spinal cord had a normal appearance. Neuronal autoantibodies were absent; in her CSF, both cell number and albumin levels were normal, but neurofilament light protein and tau were elevated. In CSF, level of phosphorylated tau (p-tau) was within the reference range, resulting in a ratio t-tau/p-tau of 12.8, β 42-amyloid was reduced, protein 14-3-3 was absent, and real-time quaking-induced conversion (RT-QuIC) for prion protein was negative (eTable 1, links.lww.com/NXG/A488). Motor neuron disease was suspected, but repeated EMG and MEP studies performed twice were normal. The patient developed somnolence, became bedridden and anarthric, contracted recurrent pneumonias, and died 7 months after the onset of motor symptoms. The patient's next of kin authorized autopsy and provided consent for this report.

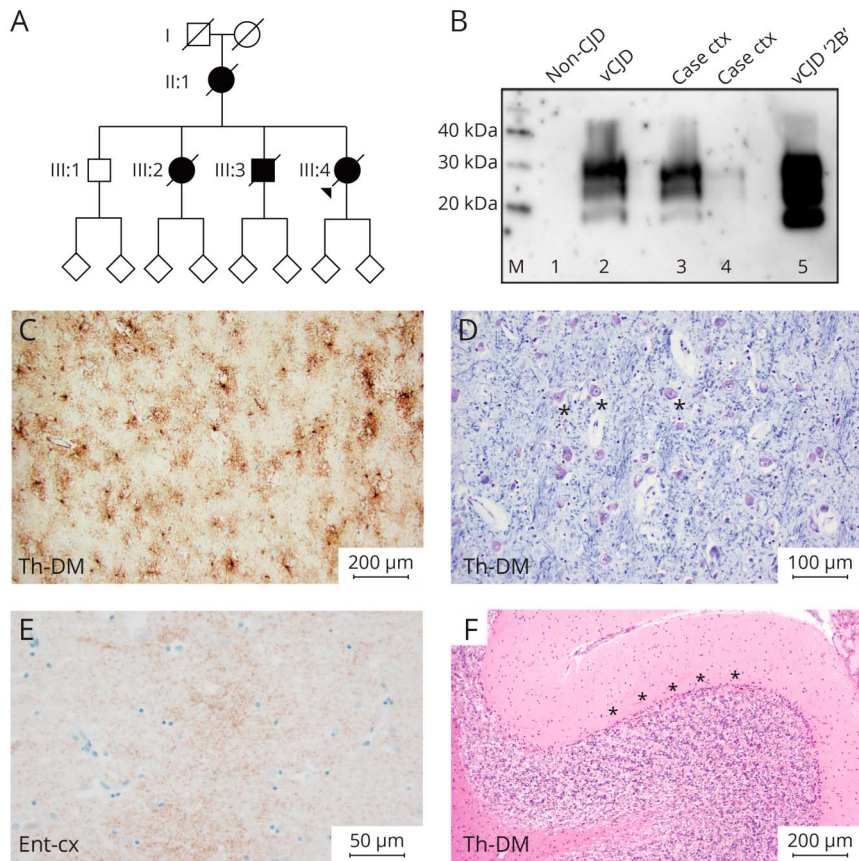
*These authors contributed equally to this work.

From the Department of Neurology (S.T., M.P., P.S.), Karolinska University Hospital, Stockholm, Sweden; Department of Clinical Neuroscience (S.T., M.P., P.S.), Karolinska Institutet, Stockholm, Sweden; Department of Psychiatry (L.W.), North West District in Stockholm, Sweden; Department of Molecular Medicine and Surgery (H.T.), Center for Molecular Medicine, Karolinska Institutet; Department of Clinical Genetics (H.T.), Karolinska University Laboratory, Karolinska University Hospital; Colin Smith (C.S.), National CJD Research & Surveillance Unit, Edinburgh, United Kingdom; and Department of Pathology (I.N.), Karolinska University Hospital, Stockholm, Sweden.

Go to Neurology.org/NG for full disclosures. Funding information is provided at the end of the article.

The Article Processing Charge was funded by the authors.

This is an open access article distributed under the terms of the Creative Commons Attribution-NonCommercial-NoDerivatives License 4.0 (CC BY-NC-ND), which permits downloading and sharing the work provided it is properly cited. The work cannot be changed in any way or used commercially without permission from the journal.



(A) The index case in a Spanish family (arrowhead) was affected with a late-onset and fast progressive neurodegenerative disease with prominent paraparesis. A genetic study revealed that she harbored the D178N mutation in *PRNP*. In addition, the neuropathologic assessment was compatible with familial fatal insomnia. (B) NaPTA Western blot analysis. M: magic marker; lane 1: unspiked NaPTA (500 μL of 10% brain homogenate—non-CJD case); lane 2: spiked NaPTA (500 μL of 10% brain homogenate—non-CJD case, spiked with 5 μL vCJD 10% brain homogenate); lane 3: frontal cortex sample from case (500 μL of 10% brain homogenate); lane 4: frontal cortex sample—additional sample from case (500 μL of 10% brain homogenate); lane 5: positive control type 2B (3 μL vCJD 10% brain homogenate). (C) Immunostaining for glial fibrillary acidic protein (GFAP) on section from the medial part of the thalamus shows astrocytosis. (D) Luxol fast blue staining on a parallel section to 1B shows the presence of several neurons indicated by asterisks. (E) Immunohistochemistry using the 12F10 antibody shows fine granular staining (brown) focally in the entorhinal cortex from the case. (F) Severe loss of Purkinje cells in the cerebellar cortex. The Purkinje cell layer is located below the asterisk. *PRNP* = prion protein.

Family History and Genetic Analyses

The patient (III:4) belonged to a family from the Castile region in Spain (Figure, A). One of her siblings (III:3), had died of a rapidly progressive disease, with anarthria and cognitive decline starting around age 35 years. The total course of disease in III:3 was 6 months, with a neuropathologic diagnosis of neuronal ceroid lipofuscinosis (Kufs disease). The neuropathologic report or charts were not possible to retrieve. Another sibling (III:2) and the patient’s mother (II:1) had a similar course of disease with age at onset around 35 years; neuropathologic examinations were, however, not made.

Whole-genome sequencing (WGS) was performed, which ruled out mutations in genes associated with lipofuscinosis but revealed the heterozygous D178N mutation in *PRNP*, polymorphism M/V at codon 129, and M in cis with the mutated allele (supplementary material, links.lww.com/NXG/A488).

Neuropathology

No macroscopic abnormalities were found on the cut surface except from prominent so-called Swiss cheese changes. The thalami were of normal size. Microscopically, astrogliosis in different thalamic nuclei (Figure, C), especially in the medial nuclei, was found without prominent neuronal loss (Figure, D).

In the medulla oblongata, severe loss of neurons and severe astrogliosis were found in the inferior olivary nuclei. The pyramid tracts appeared to be of normal size, and the motor neurons of the hypoglossal nuclei were well preserved. Spongiform changes were not present in the brain. Immunohistochemistry with an antibody against prion protein, 12F10 (Bertin Bioreagent), showed weak synaptic staining in the entorhinal cortex (Figure, E). There was a marked loss of Purkinje cells in the cerebellum (Figure, F). The spinal cord was not available for examination. Western blot analysis of frozen brain tissue demonstrated a type 2B PrP isoform (Figure, B, lane 3) (supplementary document, links.lww.com/NXG/A488).

Discussion

Wide variability of age at onset and clinical features has been described for the D178N mutation.^{3,5,6,7,e1–e6} A polymorphism at codon 129, either being valine (V) or a methionine (M), has been proposed as a strong modulator of the D178N mutation, with 129V on the same allele of the mutation associated with fCJD, whereas 129M is associated with FFI.³ Our case displays the typical neuropathologic abnormalities for FFI. It is important that homozygosity 129M is

usually associated with shorter disease duration compared with heterozygotes.^{e3} However, this association has been challenged.^{4,5,e5} Short disease duration, despite 129MV, and the initial predominant spastic paraparesis stand out in our case. Brain MRI studies may contribute when investigating prion phenotypes such as fCJD associated with E200K^{e7} but not cases with the D178N mutation. Furthermore, 14-3-3 is rarely positive in patients with the D178N mutation.⁵ Negative RT-QuIC for prion protein in our case contrasts with the high yield (83.3%) in a previous study.^{e8} Only once has irregular sleep pattern, but no apnea, been reported in D178N.⁵ This work has some limitations; PSG and dysautonomia tests were not performed due to the absence of insomnia and because dyspnea was interpreted as a COPD manifestation. Thus, central apnea may have been missed in our case. Another limitation is that the spinal cord was not available for examination. Finally, our serendipitous diagnosis illustrates the utility of WGS when investigating familial neurodegenerative diseases.

Acknowledgment

The authors are grateful to the patient's next of kin for consenting to this publication and to Dr. Rodrigo Bernaldo de Quirós in Spain. The authors are also grateful to Dr. Nicola Carrol in Edinburgh for performing allele analysis at codon 129.

Study Funding

No targeted funding reported.

Disclosure

The authors report no disclosures relevant to the manuscript. Go to Neurology.org/NG for full disclosures.

Publication History

Received by *Neurology: Genetics* November 8, 2020. Accepted in final form September 15, 2021.

Appendix Authors

Name	Location	Contribution
Sebastian Thams, MD, PhD	Karolinska University Hospital and Karolinska Institutet, Stockholm	Patient care and investigation, study concept and design, analysis and interpretation of data, and editing of the manuscript
Martin Paucar, MD, PhD	Karolinska University Hospital and Karolinska Institutet, Stockholm	Analysis and interpretation of clinical data and writing the first draft
Louise Wingård, MD, PhD	Department of Psychiatry, North West area in Stockholm	Patient care and investigation and editing of the manuscript
Håkan Thonberg, MD, PhD	Karolinska Institutet and Karolinska University Hospital, Stockholm	Interpretation of genetic data and editing of the manuscript
Colin Smith, MD, PhD	National CJD Research & Surveillance Unit, Edinburgh	Analysis of prion protein strain in brain tissue and editing of the manuscript
Inger Nennesmo, MD, PhD	Karolinska University Hospital, Stockholm	Neuropathologic assessment, study concept, and editing of the manuscript
Per Svenningsson, MD, PhD	Karolinska University Hospital and Karolinska Institutet, Stockholm	Supervision, analysis and interpretation of data, and editing of the manuscript

References

- Jansen C, Head MW, van Gool WA, et al. The first case of protease-sensitive prionopathy (PSPr) in The Netherlands: a patient with an unusual GSS-like clinical phenotype. *J Neurol Neurosurg Psychiatry*. 2010;81(9):1052-1055.
- Kitamoto T, Amano N, Terao Y, et al. A new inherited prion disease (PrP-P105L mutation) showing spastic paraparesis. *Ann Neurol*. 1993;34(6):808-813.
- Gambetti P, Parchi P, Petersen RB, Chen SG, Lugaresi E. Fatal familial insomnia and familial Creutzfeldt-Jakob disease: clinical, pathological and molecular features. *Brain Pathol*. 1995;5(1):43-51.
- Zerr I, Giese A, Windl O, et al. Phenotypic variability in fatal familial insomnia (D178N-129M) genotype. *Neurology*. 1998;51(5):1398-1405.
- Zarranz JJ, Digon A, Atarés B, et al. Phenotypic variability in familial prion diseases due to the D178N mutation. *J Neurol Neurosurg Psychiatry*. 2005;76(11):1491-1496.
- Lugaresi E, Medori R, Montagna P, et al. Fatal familial insomnia and dysautonomia with selective degeneration of thalamic nuclei. *N Engl J Med*. 1986;315(16):997-1003.
- Parchi P, Petersen RB, Chen SG, et al. Molecular pathology of fatal familial insomnia. *Brain Pathol*. 1998;8(3):539-548.

eReferences e1–e10 are available at: links.lww.com/NXG/A488.