



THE UNIVERSITY *of* EDINBURGH

Edinburgh Research Explorer

Postattenuation neurologic signs after surgical attenuation of congenital portosystemic shunts in dogs

Citation for published version:

Mullins, RA, Escribano Carrera, A, Anderson, DM, Billet, J-P, Brissot, H, Broome, C, de Rooster, H, Kirby, BM, Pratschke, KM, Tivers, MS, White, RN, Yool, DA & Youmans, KR 2021, 'Postattenuation neurologic signs after surgical attenuation of congenital portosystemic shunts in dogs: A review', *Veterinary Surgery*. <https://doi.org/10.1111/vsu.13729>

Digital Object Identifier (DOI):

[10.1111/vsu.13729](https://doi.org/10.1111/vsu.13729)

Link:

[Link to publication record in Edinburgh Research Explorer](#)

Document Version:

Publisher's PDF, also known as Version of record

Published In:

Veterinary Surgery

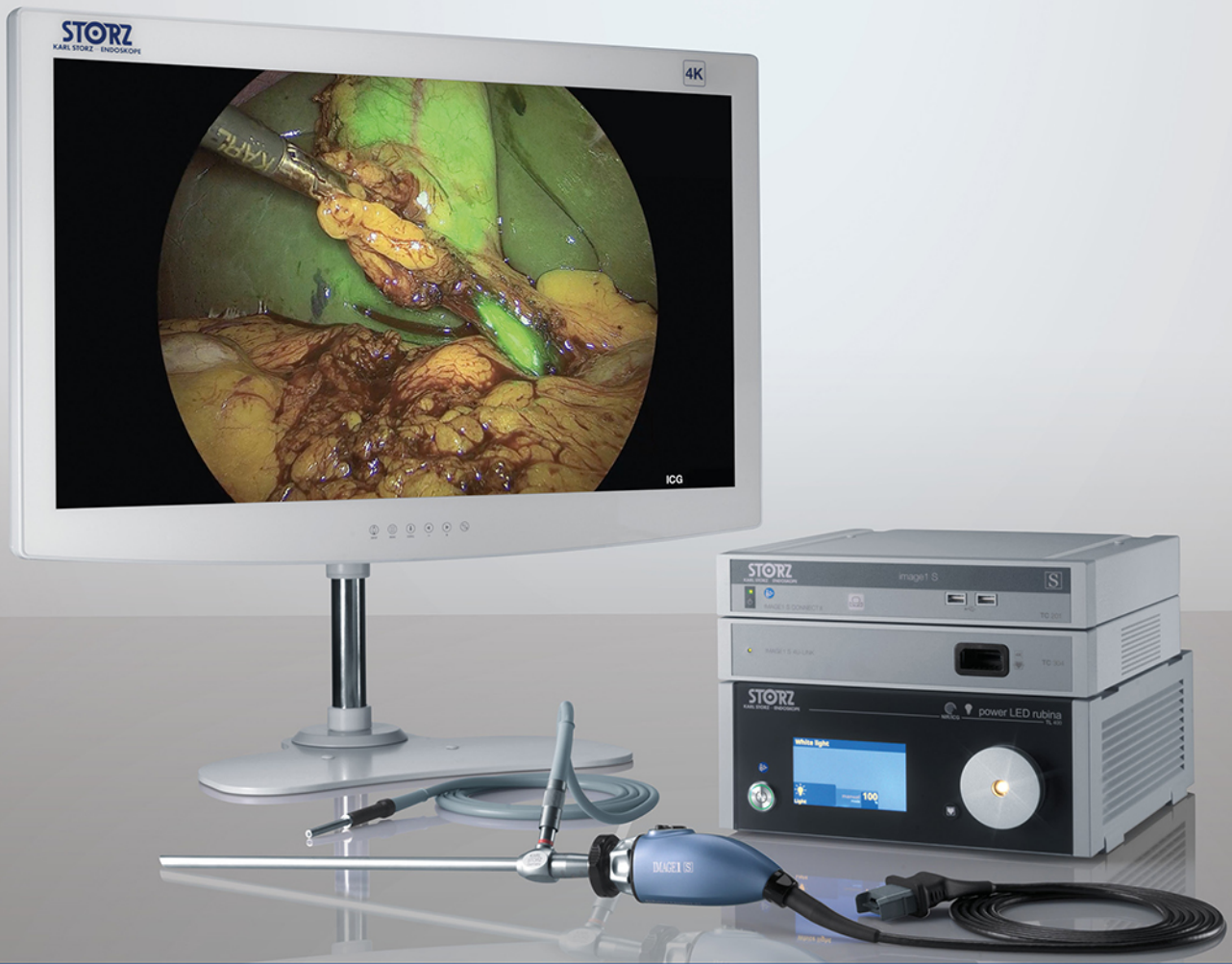General rights

Copyright for the publications made accessible via the Edinburgh Research Explorer is retained by the author(s) and / or other copyright owners and it is a condition of accessing these publications that users recognise and abide by the legal requirements associated with these rights.

Take down policy

The University of Edinburgh has made every reasonable effort to ensure that Edinburgh Research Explorer content complies with UK legislation. If you believe that the public display of this file breaches copyright please contact openaccess@ed.ac.uk providing details, and we will remove access to the work immediately and investigate your claim.





VET Special AD 1.0 09/2021/A-E

IMAGE1 S™ Rubina™

4K/NIR/ICG Imaging for Fluorescence Guided Surgery

The primary goal of any surgeon is to achieve optimal surgical results. To meet this objective the visualization and display of significant and critical structures is of crucial importance to the surgical workflow. 4K technology provides increased resolution and a wider color space while NIR/ICG offers imaging possibilities for perfusion and identifying anatomical structures invisible to the naked eye.

FREE Webinar

Fluorescence in Veterinary Minimally Invasive Surgery



REVIEW**Postattenuation neurologic signs after surgical attenuation of congenital portosystemic shunts in dogs: A review**

Ronan A. Mullins MVB, DECVS¹ | **Antía Escribano Carrera DVM, MSc¹** |
Davina M. Anderson MA VetMB, PhD, DSAS(ST), DECVS² |
Jean-Philippe Billet Dr.vét, DECVS³ | **Herve Brissot DV, DECVS⁴** |
Cameron Broome BVSc(Hons), DVCS, FANZCVS⁵ |
Hilde de Rooster DVM, MVM, PhD, DECVS⁶ |
Barbara M. Kirby DVM, MS, DACVS, DECVS¹ |
Kathryn M. Pratschke MVB, MVM, MScClinOnc, DECVS⁷ |
Michael S. Tivers BVSc(Hons), PhD, DECVS⁸ |
Robert N. White BSc(Hons), BVetMed, DSc, DSAS(ST), DECVS, SFHEA⁹ |
Donald A. Yool BVMS, PhD, DECVS, SFHEA¹⁰ |
K. Ruth Youmans BVSc, DVCS, MVetClinStud, FANZCVS¹¹

¹Section of Small Animal Clinical Sciences, University College Dublin, Dublin, Ireland

²Anderson Moores Veterinary Specialists, Winchester, UK

³Centre Hospitalier Vétérinaire Atlantia, Nantes, France

⁴Azurvet, Saint-Laurent-du-Var, France

⁵Veterinary Referral Hospital, Melbourne, Victoria, Australia

⁶Small Animal Department, Faculty of Veterinary Medicine, Ghent University, Merelbeke, Belgium

⁷Veterinary Clinical Services, The Royal (Dick) School of Veterinary Studies and The Roslin Institute, Easter Bush Campus, Midlothian EH25 9RG, UK

⁸Paragon Veterinary Referrals, Paragon Business Village, Red Hall Crescent, Wakefield, UK

⁹School of Veterinary Medicine & Science, University of Nottingham, Sutton Bonington Campus, Loughborough, UK

¹⁰University of Glasgow, School of Veterinary Medicine, Glasgow, UK

¹¹The Small Animal Surgeon Ltd, Auckland, New Zealand

Correspondence

Ronan A. Mullins, Section of small animal clinical sciences, University College Dublin, Dublin, Ireland.
 Email: ronan.mullins@ucd.ie

Abstract

The development of postattenuation neurologic signs (*PANS*) is a poorly understood and potentially devastating complication after surgical attenuation of congenital portosystemic shunts in dogs. Postattenuation neurologic signs include seizures but also more subtle neurologic signs such as depression,

After the first two authors, the author list is alphabetical.

This manuscript represents a portion of a thesis submitted by Dr Mullins to University College Dublin as partial fulfillment of the requirements for a Doctorate of Veterinary Medical Specialization.

This is an open access article under the terms of the Creative Commons Attribution-NonCommercial-NoDerivs License, which permits use and distribution in any medium, provided the original work is properly cited, the use is non-commercial and no modifications or adaptations are made.

© 2021 The Authors. *Veterinary Surgery* published by Wiley Periodicals LLC on behalf of American College of Veterinary Surgeons.

behavioral changes, tremors, and twitching. They most commonly occur within 7 days postoperatively and are typically unrelated to hyperammonemia, hypoglycemia, or electrolyte disturbances. This narrative review summarizes the findings of 50 publications from 1988-2020 that report occurrence of *PANS*. While most published reports included only dogs affected by postattenuation seizures (*PAS*), others included dogs with any form of *PANS*. Overall, *PANS* (including *PAS*) affected 1.6%-27.3% of dogs, whereas incidence of *PAS* ranged from 0%-18.2%. The etiology of *PANS* remains unknown; however, several theories have been proposed. Risk factors include preoperative hepatic encephalopathy, increasing age, and possibly certain breeds and extrahepatic shunt morphology. There is increasing evidence that prophylactic antiepileptic drugs do not prevent *PANS*. Treatment is centered around controlling neurologic signs with antiepileptic drugs and providing supportive intensive care. The 30-day survival rate in studies that included a minimum of four dogs affected by *PANS* was 0%-100% (median, 50.0%) and 0%-75.0% (median, 37.5%) for those with *PAS*. Mortality associated with *PANS* was typically related to occurrence of generalized seizure activity. Prognostic factors positively associated with short-term survival included having a history of preoperative seizures and development of focal seizures only. If affected dogs survived to discharge, survival for several years was possible, and the majority of neurologic signs manifested as part of the phenomenon of *PANS* appeared to resolve.

1 | INTRODUCTION

In 1988, Mathews and Gofton¹ reported fatal postattenuation seizures (*PAS*) in 3 dogs without preoperative seizures after surgical attenuation of a congenital extrahepatic portosystemic shunt (cEHPSS). Since then, occurrence of *PAS* or other postattenuation neurologic signs (*PANS*) has been mentioned or described in detail in 49 further reports.²⁻⁵⁰ Several terms have been used to describe this complication, including *postligation seizure syndrome*,^{11,27} *postligation neurologic dysfunction*,^{11,13,17,20,21,34} *postligation neurologic syndrome*,^{18,25} *postligation seizures*,^{11,16,39,42} *postattenuation neurologic signs*,^{41,50} and *postattenuation seizures*.^{46,47} While several investigators have described the occurrence of seizures,^{1,2,4,6-9,12,14,16,17,23-27,29-35,37-40,42,45-49} others have recognized that this phenomenon can manifest as more subtle neurologic signs such as depression, ataxia, behavioral change, tremors and twitching.^{5,10,11,13,15,18,20,22,28,41,43,50} Postattenuation neurologic signs has been defined as manifestation of any postoperative neurologic signs (including seizures) between surgery and discharge⁴¹ (most commonly within 7 days postoperatively) and typically unrelated to hyperammonemia, hypoglycemia, or electrolyte disturbances.^{12,13,16,38,39,41,46,47} This complication is considered distinct to hepatic encephalopathy (HE) for several reasons, including its occurrence even after complete shunt ligation^{1,13,15,41,43,46} and in dogs without preoperative neurologic

signs or seizures, its frequently refractory nature in comparison to preoperative neurologic signs,^{2,13,17,32,38,47} and its occurrence even in the face of normal or near normal ammonia concentrations.^{1,4,12,13,16,32,38,41,46}

The objective of this narrative review is to summarize the available literature pertaining to incidence, etiology, and risk factors for *PANS* in dogs, as well as the use of prophylactic antiepileptic drug(s) (AEDs), treatment, and prognosis for survival and outcome.

2 | SEARCH STRATEGY

An electronic literature search was performed in January 2021 using the PubMed database (www.ncbi.nlm.nih.gov/PubMed) with the aim of identifying all peer-reviewed articles without date restriction that reported occurrence of *PANS* in dogs. Search strategy details are presented in Appendix S1 in File S1. Exclusion criteria included articles in a non-English language, experimental or in vitro studies, reviews, editorials, letters to the editor, and studies that did not describe occurrence of *PANS*. Potential additional references were searched from reference lists of final PubMed selected articles. Article selection and data extraction were performed by the primary author.

The electronic search identified 962 citations, of which 706 were excluded based on their title and abstract. The

remaining 256 manuscripts were read in full, with 48 articles meeting the inclusion criteria.^{2,4-50} Reference lists within these 48 articles were hand searched for potential additional references, which yielded a further two articles meeting the inclusion criteria.^{1,3} Reference lists within these two articles were again hand searched and no further articles were identified.

3 | INCIDENCE OF POSTATTENUATION NEUROLOGIC SIGNS

Most published reports include only dogs affected by *PAS*,^{1,2,4,6-9,12,16,17,23-27,29-35,37-40,42,45-49} but others include dogs that manifest any form of *PANS*.^{5,10,11,13-15,18-22,28,36,41,43,44,50} Within the latter reports,^{5,10,11,13-15,18-22,28,36,41,43,44,50} *PANS* affected 2.6%-27.3% dogs. Overall, *PANS* (including *PAS*) affected 1.6%-27.3% of dogs (Appendix S2 in File S1).^{1,2,4-11,13-15,18-29,31-37,39-46,48-50} The true incidence of *PANS* may be underreported as subtle neurologic signs may go unrecognized.^{36,41} Postattenuation seizures are described predominantly after attenuation of *cEHPSS*, with a reported incidence of 0%-18.2%.^{1,2,4,7,10,11,13,15,18,19,23,25,27-29,31,32,34,37,39,41,44-46,48-50} Incidence of *PAS* after congenital intrahepatic portosystemic shunt (*ciHPSS*) attenuation ranges from 0%-14.3% (Appendix S2 in File S1).^{7,9,19,22,26,40,41,43}

4 | ETIOLOGY OF POSTATTENUATION NEUROLOGIC SIGNS

Etiology of *PANS* remains unknown; however, several theories have been proposed.

4.1 | Central nervous system (CNS) disease/derangement

4.1.1 | Altered central nervous system metabolism

Based on a single study,⁵¹ one *PANS* theory is that a decrease in systemic concentrations of endogenous benzodiazepines derived from the gastrointestinal tract occurs after shunt attenuation. Mean concentrations of endogenous benzodiazepines in portal and arterial blood of 15 dogs with congenital portosystemic shunts (*cPSS*) were significantly ($P < .05$) higher than those of eight healthy controls.⁵¹ Investigators proposed that if shunting caused stimulation of brain benzodiazepine receptors, a decline in systemic concentrations after shunt attenuation

could result in seizures.⁵¹ A decrease in cerebrospinal fluid (CSF) concentrations of endogenous benzodiazepines and changes in concentrations of neurotransmitters have also been theorized to precipitate seizures.² This theory relating to a decline in systemic or CSF endogenous benzodiazepine concentrations fails to explain the occurrence of *PANS* after partial ligation^{1,2,4,9,13,15,16,18,19,43,46} and delayed attenuation techniques.^{10,13,17-19,21,23,25-28,30,32,34,37,39,40,44-50} Administration of benzodiazepines has also proven unreliable in the management of *PANS*.^{2,13,17,18,32}

It is recognized that dogs with *cPSS* have significantly ($P < .0001$) increased whole blood manganese concentrations compared with healthy controls.⁵² In rats, exposure of astrocytes to manganese is associated with upregulation of "peripheral type" benzodiazepine receptors;⁵³ however, an association in dogs has not been investigated. Torisu and colleagues⁵⁴ identified hyperintensity of the lentiform nuclei on T1-weighted images in dogs with *cPSS*, which decreased after surgical attenuation. In a case report by the same investigators,³⁰ lentiform nuclei were confirmed to have significantly higher (> 4 times) manganese concentrations (as well as approximately twice the concentration of iron and copper) in a dog with *PAS* that was euthanized compared with a control group.

Postattenuation neurologic signs do not appear to be a manifestation of postoperative hyperammonemic-HE and seem distinct from neurologic signs observed preoperatively related to HE.¹⁶ They are reported predominantly in the presence of normal/near normal or significantly decreased (compared with preoperatively) ammonia concentrations,^{1,4,12,13,16,32,38,41,46} with only a few reported cases with concurrent hyperammonemia.^{2,4,30,41,46} In a retrospective study involving 253 dogs (28 of which developed *PANS*),⁴¹ no significant difference in preoperative or postoperative ammonia concentrations was identified among dogs that did or did not experience *PANS* or *PAS*. In another retrospective study involving 75 dogs affected by *PAS*,⁴⁶ ammonia concentrations around the time of *PAS* occurrence were < 70.0 $\mu\text{mol/L}$ in 76.7% of dogs for which values were available. In a further retrospective study involving 93 dogs with *PAS* (many of which were included in the previous study⁴⁶),⁴⁷ dogs with a history of preoperative seizures had a median ammonia concentration of 46.0 (range, 13.0-104.0) $\mu\text{mol/L}$ (< 70 $\mu\text{mol/L}$ considered normal)^{41,47} at the time of *PAS*. Some dogs with HE can have normal ammonia concentrations and the possibility of an unknown biochemical factor resulting in a nonhyperammonemic HE has been proposed as an explanation for *PANS*.^{4,55} However, absence of preoperative HE in some dogs and the refractory nature of *PANS* in comparison to preoperative HE suggest an alternative etiology than postoperative continuation of HE.^{4,17} Investigators in an older retrospective

case series² considered the presence of HE-induced brain lesions as a possible cause for *PAS* in four dogs; however, histologic signs supporting this were not identified on necropsy of two brain specimens.²

Occurrence of one or more postoperative metabolic events in the face of shunting-induced CNS damage has been theorized to result in *PAS*.² It has also been suggested the CNS of dogs with cPSS becomes adapted to a state of altered metabolism and that a change in this altered metabolic state postattenuation precipitates *PAS*.^{4,13} The presence of HE immediately preoperatively has been identified as a risk factor for *PANS* and *PAS*,⁴¹ with investigators proposing that a larger relative change in CNS environment postattenuation could be responsible for *PANS*.⁴¹

4.1.2 | Concurrent brain disease

Concurrent brain disease, including idiopathic epilepsy, congenital, inflammatory and noninflammatory brain disease, has been suggested as a possible cause of *PANS*.^{2,13,44} A congenital etiology, cerebral cortical disease, and idiopathic epilepsy were considered unlikely by investigators in a small retrospective case series² because of the positive preoperative response to treatment of HE in three affected dogs and absence of preoperative neurologic signs in another dog. In another retrospective case series,⁴ only 2 of 5 dogs with generalized *PAS* demonstrated preoperative neurologic signs, suggesting that pre-existing brain disease was not responsible for postoperative generalized seizures. A limitation of these case series^{2,4} is that they include a total of only 9 dogs. Evidence of inflammatory or congenital (eg, hydrocephalus) brain disease has not been identified on necropsy in affected dogs.^{2,4,20,23,39,44} Cerebrospinal fluid obtained from three dogs with cPSS identified mild inflammation in two^{2,4} (suspected due to prolonged seizure activity in one dog),² and was normal in the third dog.¹ In a retrospective study,⁴⁴ no evidence of necrotizing meningoencephalitis was identified on necropsy in any pug that developed *PANS* and subsequently died. Reye's syndrome, a rare and potentially fatal illness in people involving acute noninflammatory encephalopathy with fatty liver failure, has also been suggested as a possible cause of *PAS* but it was considered unlikely on the basis of decreased ammonia concentrations postoperatively and lack of elevated liver enzymes.² As far as we are aware, Reye's syndrome has not been reported in dogs. Using single photon emission computed tomography (SPECT), one study demonstrated areas of regional hypoperfusion and hyperperfusion within the brain of 8 dogs with cPSS and HE compared with 8 normal dogs.⁵⁶

4.1.3 | Acquired brain disease

Hypertensive encephalopathy has been considered a possible cause of *PAS*.² However, blood pressure during seizure activity has been reported in only four dogs and was within normal limits in all cases.^{2,32} Severe intraoperative hypotension has also been suggested as a cause of *PAS* because of secondary brain ischemia and subsequent neuronal necrosis.³⁹ However, no difference in incidence of *PAS* among dogs that did (8.4%) or did not (7.4%) experience intraoperative hypotension was identified in one retrospective study.³⁹ Finally, hypoxemia/brain hypoxia has been proposed as a possible cause of *PAS*,^{2,4,32,44} however, there is no strong evidence to support this. In two small retrospective case series,^{2,4} lesions consistent with hypoxia/anoxia identified in brain specimens of four nonsurvivors were suspected to be due to seizure activity rather than a cause.

4.2 | Perioperative hypoglycemia

Perioperative hypoglycemia is a recognized complication of cEHPSS attenuation in small dogs.⁵⁷ Hypoglycemia is sporadically reported in dogs with *PAS*^{1,2,4,46,47} but there are many reported cases of *PANS* and *PAS* that occurred with normoglycemia.^{1,4,10–13,16,17,32,38,39,44,46} In a retrospective study involving 75 dogs with *PAS*,⁴⁶ glucose concentrations at the time of seizure occurrence were ≥ 3.3 mmol/L in 91.9% dogs for which values were available. There are at least four reports of affected dogs receiving dextrose-containing fluids or eating voluntarily when *PANS* first commenced.^{1,4,12,13} Postattenuation neurologic signs can also progress despite treatment to correct hypoglycemia.^{2,4} Hypoglycemia-induced brain lesions may be an explanation but this concept has not been investigated.²

4.3 | Perioperative electrolyte disturbances

Variable degrees of derangement in electrolyte concentrations have been identified in a limited number of dogs at the time of *PAS*.^{2,4,16,25,47} Low to low-normal total calcium concentrations have been reported in at least seven dogs affected by *PAS*; however, ionized hypocalcemia was confirmed in only a single dog.^{2,13,16} Intravenous calcium supplementation in at least two of these dogs did not arrest seizures.^{2,13} Hypokalemia has also been identified in dogs affected by *PAS* and correction similarly did not always abolish seizures.^{2,16,46,47} There are many more reported cases of *PAS* occurring in the face of normal

electrolyte concentrations and the potential contribution of electrolyte derangement to occurrence of *PANS* remains unclear.^{12,32,38,46,47}

4.4 | Postoperative portal hypertension

A clear association between *PANS* and portal hypertension has not been demonstrated and there are several reports of *PANS* despite intraoperative measurement of portal pressures and adherence to recommended guidelines for attenuation.^{1,2,4,10–12,17,41} There are occasional reports of portal pressures measured at the time of *PAS*.^{2,4} In one affected dog, portal pressures measured via a catheter that had been left in situ in a jejunal vein were consistently within normal limits.⁴ No evidence of portal hypertension was identified, either grossly or following measurement of portal pressures in two affected dogs that underwent repeat celiotomy during *PAS*.^{2,4} There is one report¹¹ of *PANS* persisting after ligature removal for treatment of concurrent postoperative portal hypertension and another report¹⁰ of *PANS* developing after ligature removal. No gross evidence of portal hypertension was identified at necropsy in two dogs.¹

4.5 | Infectious disease

An infectious cause for *PANS* has not been identified. In a small case series,² serologic testing for canine distemper virus in two dogs yielded negative results and CSF bacterial culture from one dog failed to identify a causative organism.

5 | RISK FACTORS FOR POSTATTENUATION NEUROLOGIC SIGNS

Potential risk factors for *PANS* include:

5.1 | Presence of immediately preoperative hepatic encephalopathy

Neurologic signs consistent with HE are frequently diagnosed in dogs with *cPSS* but few studies report the prevalence of HE immediately preoperatively.⁴¹ In a retrospective study involving 253 dogs,⁴¹ the presence of HE immediately preoperatively was a risk factor for *PANS* (odds ratio [OR] 2.704, CI 1.057–6.922) and *PAS* (OR 3.538, CI 1.013–12.363). The presence of more severe CNS changes^{58,59} (eg, astrocyte swelling caused by neurotoxic substances such as ammonia), a less stable neurologic state, and a greater

relative change in CNS biochemical environment after shunt attenuation were considered to be implicated.⁴¹ This highlights that preoperative medical stabilization of HE should be a priority where possible.

5.2 | Increasing age

Increasing age has been identified in a recent study as a risk factor for *PANS* (OR 1.476, CI 1.223–1.780) and *PAS* (OR 1.364, CI 1.082–1.720),⁴¹ corroborating observations of several previous investigators.^{2,4,13,23,41,44,46,47} It has been suggested that the brain of older dogs is exposed to the abnormal metabolic consequences of shunting for longer or becomes adapted to a state of abnormal metabolism, with shunt attenuation in such dogs precipitating *PANS*.^{4,41} Postattenuation neurological signs have also been reported in dogs <12 months old^{1,2,4,16,17,21,23,25,32,41,43,47} and some studies report no significant difference in age of dogs that did or did not develop *PANS*.^{13,21,44}

5.3 | Extrahepatic portosystemic shunt morphology

Postattenuation neurological signs (including *PAS*) have been reported predominantly after correction of *cEHPSS*,^{1,2,4,10–13,15,18,19,21,23,25,27–29,31,32,34,37–39,41,44–50} with fewer reports after *cIHPSS* attenuation.^{5,7,9,16,17,21,22,26,36,40,41,43} In one retrospective study involving 89 dogs,¹³ those with *cEHPSS* (12.4%) were more likely ($P = .03$) to develop *PANS* than dogs with *cIHPSS* (0.0%). However, this is not supported by two larger retrospective studies involving 106 and 253 dogs, respectively.^{21,41} The incidence of *PAS* after *cEHPSS* attenuation is 0%–18.2%^{1,2,4,7,10,11,13,15,18,19,23,25,27–29,31,32,34,37,39,41,44–46,48–50} and 0%–14.3%^{7,9,19,22,26,40,41,43} after *cIHPSS* attenuation (Appendix S2 in File S1). *PANS* are reported after attenuation of portocaval, portophrenic, and portoazygos shunt submorphologies.^{10,13,46,47} One retrospective study identified a trend toward dogs with portoazygos shunts being at greater risk of *PANS* than dogs with portocaval shunts.¹³ Dogs with portoazygos shunts tend to be older at diagnosis than dogs with portocaval shunts and it is possible that their older age is responsible for increased risk of *PANS* in such dogs rather than the shunt submorphology.¹³

5.4 | Certain breeds

Certain breeds have been suggested to be at increased risk of *PANS*, including Jack Russell terriers,²¹ pugs^{10,13,44} and Maltese.^{1,13} However, these observations are derived from small study populations.

6 | FACTORS THAT HAVE NOT BEEN FOUND TO BE ASSOCIATED WITH INCREASED RISK OF POSTATTENUATION NEUROLOGIC SIGNS

6.1 | Method and degree of acute intraoperative shunt attenuation

Postattenuation neurologic signs are reported after complete and partial suture ligation;^{1,2,4,6,7,9,11–16,18,24,31,38,41,46,47} delayed attenuation techniques, including thin film banding (TFB);^{10,13,17,21,25,27,30,39,40,44–48,50} ameroid constrictor (AC) placement,^{16,18,23,26,28,32,34,39,44,46–48,50} and endovascular techniques.^{36,40} The incidence of *PAS* after suture ligation, TFB and AC placement is 0%–18.2%,^{1,2,4,6–9,11,13–15,18–20,22,24,26,28,31,35,42,43} 1.8%–18.2%,^{10,13,25,27,37,40,45,48,50} and 0%–13.0%,^{15,18,19,23,26,28,34,45,48,50} respectively (Appendix S2 in File S1). The incidence of *PAS* after coil embolization in dogs with cIHPSS was 3.7% in one study.⁴⁰ In another study,³⁶ *PANS* occurred in eight (8.4%) of 95 dogs undergoing coil embolization of cIHPSS. A number of investigators have compared the incidence of *PANS* directly between individual methods of shunt attenuation.^{13,40,48} Two studies found no significant difference in incidence of *PAS* among dogs with cEHPSS treated with TFB or AC.^{48,50} No significant difference in incidence of *PANS* was identified among dogs with cEHPSS that underwent partial attenuation with silk (14.3%) or TFB (11.4%) in another study.¹³ Case and colleagues⁴⁰ reported *PAS* in 9.7% dogs with cIHPSS after TFB and 3.7% after coil embolization; however, the investigators did not state if the difference was statistically significant.

No association has been identified between degree of acute intraoperative shunt attenuation and occurrence of *PANS*. In one retrospective study,¹³ 8.3% of dogs undergoing complete ligation with silk experienced *PANS*, in comparison to 13.0% of dogs that underwent partial attenuation with silk or TFB ($P = .6$). In a large-scale retrospective study,⁴¹ the degree of shunt attenuation (complete ligation vs. TFB or partial ligation) was not associated with *PANS* or *PAS*. Degree of intraoperative shunt occlusion with TFB (<3 mm versus no occlusion) was also not associated with occurrence of *PANS* in another study.²⁵

6.2 | Preoperative neurologic signs or seizures

As discussed previously, the presence of immediately preoperative hepatic encephalopathy has been identified as a risk factor for *PANS* and *PAS*.⁴¹ However, a clear association between presence of preoperative neurologic

signs or seizures overall (not just in the immediate preoperative period) and occurrence of *PANS* or *PAS* has not been identified.⁴¹ In three large retrospective studies,^{13,41,48} no difference in the incidence of *PANS* or *PAS* was identified among dogs that did or did not have preoperative neurologic signs/HE. However, investigators in two of these studies do not report specific timing of neurologic signs prior to surgery.^{13,48} Absence of preoperative neurologic signs/HE (prior to medical management or immediately preoperatively) does not exclude the possibility of *PANS*.^{39,41,47} In a study that included 93 dogs affected by *PAS*,⁴⁷ approximately 25% of affected dogs did not have preoperative neurologic signs and only 17.2% had preoperative seizures. In another retrospective study,²³ only 1 of 7 dogs with *PAS* had preoperative seizures, while in 3 small case series^{4,16,32} and a case report,¹⁷ no dog with generalized *PAS* had a history of preoperative seizures.

6.3 | Surgical or anesthesia time

In a retrospective study that included 124 dogs,³⁹ neither surgical nor anesthetic time was significantly different among dogs that did or did not experience *PAS*.

6.4 | Postoperative changes in natremia/serum osmolality

Investigators in a retrospective study proposed that *PANS* may be related to postoperative changes in natremia/osmolality.⁴¹ In that study,⁴¹ serum osmolality was significantly higher at two postoperative time points (median of 8 [$P = .016$] and 24 h [$P = .020$] postoperatively) in dogs affected by *PANS* and at all 3 postoperative time points (median of 1 [$P = .001$], 8 [$P = .002$], and 24 h [$P = .006$] postoperatively) in dogs affected by *PAS* compared with unaffected dogs. However, osmolality did not remain statistically significant in the multivariable analysis.⁴¹ There are no further studies investigating serum osmolality in dogs with *PANS*.

7 | USE OF PROPHYLACTIC ANTIEPILEPTIC DRUGS (AEDs)

Efforts to reduce the incidence of *PANS* have included prophylactic treatment with AEDs including benzodiazepines,^{24,45} phenobarbital,^{10,13,17,21,24,27,32} potassium bromide,^{23,24,26} and levetiracetam.^{34,39,41,45–48,60} None of these has unequivocally been demonstrated to reduce the incidence of *PANS* in dogs with cPSS; however, without

measurement of plasma drug concentrations, any conclusions regarding the efficacy of these AEDs is tentative.

7.1 | Levetiracetam

There are conflicting reports regarding the possible protective effect of prophylactic treatment with levetiracetam against development of *PANS*. In one retrospective study,³⁴ none of 42 dogs that had received preoperative levetiracetam, 20 mg/kg every 8 h (q8) for at least 24 h, experienced *PAS*, whereas four (4.8%) of 84 dogs that had not received levetiracetam developed *PAS*. This observation, however, was not supported by four subsequent larger retrospective studies.^{39,41,46,48} In one retrospective study,⁴¹ 6 (11.1%) of 54 dogs that had received prophylactic levetiracetam (20 mg/kg q8 for ≥ 24 h preoperatively and for ≥ 5 days postoperatively) developed *PANS*, whereas 22 (11.1%) of 199 dogs that had not received levetiracetam experienced *PANS*. Investigators also found a similar incidence of *PAS* among dogs that had or had not received levetiracetam (5.6% and 4.5%, respectively).⁴¹ In another large retrospective study,⁴⁶ the incidence of *PAS* was not significantly different among dogs that did (11.2%) or did not (6.7%) receive levetiracetam at ≥ 15 mg/kg q8 for ≥ 24 h preoperatively or a 60 mg/kg intravenous loading dose perioperatively, both followed by ≥ 15 mg/kg q8 postoperatively. However, the same levetiracetam protocol was not followed in all cases in that study.⁴⁶ A limitation of all published studies describing prophylactic treatment with levetiracetam is their retrospective nature and lack of randomization and standardization of treatment.^{34,39,41,46–48} Some studies provide no information regarding preoperative or postoperative dose or duration of levetiracetam.^{39,48} In the study by Fryer and colleagues,³⁴ some dogs did not receive any postoperative levetiracetam, with the authors placing emphasis on pretreatment. According to a pharmacokinetic study,⁶¹ failure to continue levetiracetam postoperatively, and at the appropriate dosage (20 mg/kg q8), would be expected to result in plasma drug concentrations decreasing below the recommended therapeutic range (5–45 $\mu\text{g/ml}$) after approximately 12 h. In another study,³⁹ some dogs prescribed levetiracetam received concurrent phenobarbital and/or potassium bromide, a practice that has been shown to alter the pharmacokinetics of levetiracetam significantly.^{62,63} Wallace and colleagues⁶⁰ described the administration of levetiracetam for a median (range) of 23 (1–29) days preoperatively and four (2–4) weeks postoperatively in six dogs that underwent cEHPSS attenuation with a polyacrylic acid-silicone device, none of which experienced *PANS*, but that study did not include a control group.

7.2 | Phenobarbital

Prophylactic treatment with phenobarbital has not been demonstrated to reduce the incidence of *PANS* but one retrospective study suggested that it may reduce its severity.¹³ In that study,¹³ prophylactic phenobarbital (5–10 mg/kg before induction followed by 3–5 mg/kg q12 for 3 weeks postoperatively) did not significantly decrease the incidence of *PANS* (6.5%) compared with a control population (15.5%). However, no dog that received phenobarbital experienced generalized *PAS*.¹³ Inadequacy of presurgical loading was suggested as a reason for failure to prevent *PANS* in that study completely, although serum phenobarbital concentration at the time of *PANS* occurrence was within therapeutic range in the one dog in which it was measured.³⁴ In a retrospective study involving 106 dogs,²¹ *PANS* were observed in 9.4% dogs despite most having received perioperative phenobarbital (5–10 mg/kg) and for 2 weeks postoperatively (2–5 mg/kg q12).

7.3 | Potassium bromide

Few studies report prophylactic treatment with potassium bromide and a protective effect has not been identified.^{23,26} In a retrospective study involving 28 dogs with cIHPSS,²⁶ one dog that had received a 24-h preoperative loading regimen of potassium bromide (100 mg/kg q6) experienced *PAS*. However, no information is provided regarding the overall number of dogs that received prophylactic potassium bromide.²⁶ In another retrospective study involving 168 dogs with cEHPSS,²³ four (8.3%) of 48 dogs that had received preoperative treatment with potassium bromide (44–100 mg/kg q24 for at least two weeks preoperatively) developed *PAS* compared with four (3.3%) of 120 dogs that did not receive potassium bromide. No information is provided regarding whether treatment was continued postoperatively in affected dogs.

8 | TREATMENT OF POSTATTENUATION NEUROLOGIC SIGNS

The idiopathic nature of *PANS* precludes accurate treatment of a specific cause.^{12,41} Treatment is therefore centered around providing supportive care measures and controlling neurologic signs using AEDs, including benzodiazepines,^{1,2,4,8,13,16–18,21,23,32,45,47} barbiturates,^{1,2,4,10–13,16–18,21,23,26,32,38,43,47} propofol,^{12,13,16,21,32,38,47} levetiracetam,^{41,43,45,47} alfaxalone,⁴⁷ potassium bromide,^{12,13,22,38,41,43,47} α -2 agonists,^{38,47} and benzodiazepine

antagonists.⁴⁷ There are no prospective randomized studies evaluating efficacy of one or more AEDs/treatment protocols. In a retrospective study involving 93 dogs affected by PAS,⁴⁷ no drug was associated with improved short-term survival in the multivariable analysis. A limitation of current literature is that treatment is nonrandomized and based on clinician preference. Because multiple AEDs are often administered concurrently and more aggressive treatments are likely to have been administered to more severely affected cases, interpretation of results is difficult.^{12,13,16,32,38,41,47} No consensus exists regarding best practice treatment of PAS or more subtle PANS. Generalized PAS in particular are often refractory to treatment and thus very challenging to control.^{1,2,4,6,7,9-13,16,18-21,23,26,31,32,34,35,38,39,41,44} In some cases, mild neurologic signs resolve without treatment, whereas other cases progress to refractory seizures, highlighting that very close monitoring is required.^{2,11,13,16,17,20,23,41} Treatment of PANS with benzodiazepines is controversial.⁶⁴ As discussed previously, one older study⁵¹ suggested a decline in systemic concentrations of endogenous benzodiazepines after shunt attenuation could precipitate PAS. This would suggest that prophylactic treatment with benzodiazepines may be efficacious in the prevention or treatment of PANS. However, in the majority of studies in which an assessment of the response to treatment of PANS with benzodiazepines is possible, they failed to control neurologic signs, particularly in cases of generalized PAS.^{2,4,8,13,16-18,23,32,34,41} There are several reports of treatment of PAS with propofol CRI,^{12,16,32,38,41,47} typically resulting in rapid control of even refractory seizures. Anecdotally, it has been suggested that use of propofol for management of PAS may be associated with elimination of external manifestations of seizure activity but may not arrest the brain activity causing the seizures. To our knowledge, this has not been investigated in dogs. Prior to the first reports of using propofol for control of PAS,^{12,16} barbiturates including pentobarbital and thiopental were administered in cases refractory to benzodiazepines.^{2,13} There are several reports of treatment of PANS and specifically PAS with phenobarbital, with mixed but mostly positive results.^{2,10,11,13,17,18,26,41} While levetiracetam is relatively frequently described as a prophylactic AED in recent literature,^{34,39,41,45-48,60} there are few reports describing its efficacy in the treatment of PANS.^{41,43,45,47} In one retrospective study,⁴¹ 9 dogs with PANS received treatment with levetiracetam, including 5 dogs with PAS. However, in 8 of those 9 dogs, other AEDs including phenobarbital and propofol were administered concurrently with levetiracetam, and in 1 case, PAS were described as refractory to levetiracetam.⁴¹ Treatment of PAS with levetiracetam was also not significantly associated with short-term survival in a more recent study.⁴⁷

9 | SURVIVAL/PROGNOSIS

The 30-day survival rate in studies of ≥ 4 dogs affected by PANS overall is 0%-100% (median, 50.0%)^{2,4,6,11,13,20,21,23,24,28,34,39,41,43,44,47,48,50} and for PAS specifically ($n \geq 4$ dogs) is 0%-75.0% (median, 37.5%) (Appendix S3 in File S1).^{2,4,6,13,20,23,24,34,39,41,47,48,50} Such variation in survival rates is likely related to varying numbers of dogs within reports and those with generalized versus focal PAS or more subtle PANS, different levels of experience in treating PANS and the extent to which they are treated, and possibly the managing clinician's perception of prognosis. Dogs that experience PANS other than PAS and those that experience focal PAS only (in comparison to generalized PAS) have a better outlook for survival.^{11,13,15,18,20,23,26,28,34,39,41,44,47} In a large retrospective study,⁴¹ all dogs with PANS other than seizures survived to discharge compared with the 7 (58.3%) of 12 dogs that experienced PAS. In another retrospective study,²⁰ dogs that experienced seizures or coma did not respond to treatment, whereas all those with more mild PANS survived. However, knowing that mild PANS are associated with a better prognosis has limited prognostic value as it is impossible to predict whether more subtle neurologic signs will progress to seizures.^{2,11,13,16,17,20,23} Among 76 dogs with generalized PAS in one study,⁴⁷ 13 (17.1%) were recorded as having experienced focal PAS that later progressed to generalized PAS. Generalized PAS may be more refractory to treatment, more distressing for the owner to observe, associated with a greater financial cost and the perception of a poorer prognosis for recovery, all of which may influence the decision to euthanize.^{13,47} In a retrospective study involving 7 dogs with PAS,²³ all dogs with focal PAS only survived to discharge, whereas none of those with generalized PAS survived. In another retrospective study involving 93 dogs with PAS,⁴⁷ only 32.3% dogs survived to 30 days; however, the majority experienced generalized PAS, which were significantly associated with mortality. In that study,⁴⁷ 21.1% of dogs with generalized PAS survived to 30 days in comparison to 82.4% of dogs with focal PAS only ($P = .0003$). Dogs with PAS that had a history of preoperative seizures had significantly ($P = .004$) increased odds of survival to 30 days compared with those that did not have preoperative seizures.⁴⁷ This corroborates findings of an earlier retrospective study³⁹ in which dogs with a history of preoperative seizures that subsequently experienced PAS had a sevenfold increased probability of survival (to discharge) compared with those without a history of preoperative seizures. It is possible that PAS experienced by both subsets of dogs may have a different etiopathogenesis or some dogs with

preoperative seizures (related to HE) may have continuation of these seizures postoperatively.^{39,46,47} There are no large-scale studies investigating neurologic outcomes of dogs affected by PANS that survive to 30 days but several reports document reoccurrence of seizure activity in the long term (>30 days).^{2,4,10,12,13,16,38} Without follow-up assessment of shunt closure, it is possible that return of neurologic signs or seizures could be related to the reoccurrence or persistence of HE because of residual or acquired shunting. If affected dogs survive to discharge, survival for several years is possible.^{3,32,38} On the basis of the overall small number of published reports, and specifically those describing long-term outcomes, and inconsistent follow-up times within reports, it is difficult to provide meaningful prognostic information regarding survival time and neurologic outcomes to owners of affected dogs.^{2,4,10,12,13,16,32,38} The majority of neurologic signs manifested as part of PANS appear to resolve,^{2,4,10,13,16,38} however, exact timing of resolution of signs is difficult to determine due to inconsistent follow up and lack of standardization of follow-up times. There are also no published studies investigating the long-term quality of life of dogs affected by PANS.

10 | CONCLUSION

The development of PANS is a potentially devastating complication after cPSS attenuation in dogs. Overall, PANS (including PAS) affect 1.6%–27.3% of dogs. Postattenuation seizures are described predominantly after attenuation of cEHPSS, with a reported incidence of 0%–18.2%; however, this may reflect the greater frequency of cEHPSS in dogs compared with cIHPSS. The etiology of PANS remains elusive; however, a number of risk factors have been identified, including increasing age and presence of HE immediately preoperatively. A history of preoperative seizures is associated with improved survival for dogs that develop PAS. Certain breeds may also be predisposed to PANS. There is increasing evidence to suggest that prophylactic treatment with levetiracetam does not prevent PANS. Treatment of PANS is supportive and centered around administration of AEDs as the idiopathic nature of PANS precludes specific treatment. Generalized PAS can be particularly refractory to treatment and the prognosis for dogs affected by such is generally poor. Dogs with less severe PANS are more likely to survive but progression to more severe signs has been reported. Overall, if affected dogs survive to discharge, survival for several years is possible, and the majority of neurologic signs manifested as part of PANS appear to resolve.

ACKNOWLEDGMENTS

Author Contributions: Mullins RA, DECVS: Conception, design, article selection, data extraction and assignment of level of evidence, manuscript preparation and review. All other authors provided critical and meaningful reviews of the manuscript and contributed to its scientific content.

The authors would like to thank Drs J. Brad Case, DVM, MS, DACVS (University of Florida, USA); Ameet Singh, BSc, DVM, DVSc, DACVS (University of Guelph, Canada); Kelley M. Thieman Mankin, DVM, MS, DACVS (Texas A&M University, USA); and Anne Kummeling, DVM, PhD, DECVS (Utrecht University, Netherlands) for reviewing the manuscript. Open access funding provided by IReL.

CONFLICT OF INTEREST

The authors declare no conflicts of interest related to this report.


ORCID

Ronan A. Mullins  <https://orcid.org/0000-0003-1159-2382>

Davina M. Anderson  <https://orcid.org/0000-0003-0282-1219>

Hilde de Rooster  <https://orcid.org/0000-0001-8087-256X>

Kathryn M. Pratschke  <https://orcid.org/0000-0002-1468-9967>

Michael S. Tivers  <https://orcid.org/0000-0001-7047-9334>

Robert N. White  <https://orcid.org/0000-0002-3507-278X>

Donald A. Yool  <https://orcid.org/0000-0002-3562-9111>

REFERENCES

- Mathews K, Gofton N. Congenital extrahepatic portosystemic shunt occlusion in the dog: gross observations during surgical correction. *J Am Anim Hosp Assoc*. 1988;24:387-394.
- Hardie EM, Kornegay JN, Cullen JM. Status epilepticus after ligation of portosystemic shunts. *Vet Surg*. 1990;19(6):412-417.
- Hardie E, Kornegay JN, Cullen JM. Successful treatment of status epilepticus following operation for portosystemic shunt. *Vet Surg*. 1990;44:67.
- Matushek K, Bjorling D, Mathews K. Generalized motor seizures after portosystemic shunt ligation in dogs: five cases (1981-1988). *J Am Vet Med Assoc*. 1990;196(12):2014-2017.
- Komtebedde J, Forsyth SF, Breznock EM, Koblik PD. Intrahepatic portosystemic venous anomaly in the dog perioperative management and complications. *Vet Surg*. 1991;20(1):37-42.
- Hottinger HA, Walshaw R, Hauptman JG. Long-term results of complete and partial ligation of congenital portosystemic shunts in dogs. *Vet Surg*. 1995;24(4):331-336.
- Simpson KW, Meyer DJ, Boswood A, White RN, Maskell IE. Iron status and erythrocyte volume in dogs with congenital portosystemic vascular anomalies. *J Vet Intern Med*. 1997;11(1):14-19.

8. Tobias KM, Besser TE. Evaluation of leukocytosis, bacteremia, and portal vein partial oxygen tension in clinically normal dogs and dogs with portosystemic shunts. *J Am Vet Med Assoc.* 1997; 211(6):715-718.
9. White RN, Burton CA, McEvoy FJ. Surgical treatment of intrahepatic portosystemic shunts in 45 dogs. *Vet Rec.* 1998; 142(14):358-365.
10. Youmans KR, Hunt GB. Cellophane banding for the gradual attenuation of single extrahepatic portosystemic shunts in eleven dogs. *Aust Vet J.* 1998;76(8):531-537.
11. Hunt GB, Hughes J. Outcomes after extrahepatic portosystemic shunt ligation in 49 dogs. *Aust Vet J.* 1999;77(5):303-307.
12. Heldmann E, Holt DE, Brockman DJ, Brown DC, Perkowski SZ. Use of propofol to manage seizure activity after surgical treatment of portosystemic shunts. *J Small Anim Pract.* 1999;40(12):590-594.
13. Tisdall PLC, Hunt GB, Youmans KR, Malik R. Neurological dysfunction in dogs following attenuation of congenital extrahepatic portosystemic shunts. *J Small Anim Pract.* 2000;41(12): 539-546.
14. Wolschrijn CF, Mahapokai W, Rothuizen J, Meyer HP, van Sluijs FJ. Gauged attenuation of congenital portosystemic shunts: results in 160 dogs and 15 cats. *Vet Q.* 2000;22(2):94-98.
15. Murphy ST, Ellison GW, Long M, Van Gilder J. A comparison of the ameroid constrictor versus ligation in the surgical management of single extrahepatic portosystemic shunts. *J Am Anim Hosp Assoc.* 2001;37(4):390-396.
16. Yool DA, Kirby BM. Neurological dysfunction in three dogs and one cat following attenuation of intrahepatic portosystemic shunts. *J Small Anim Pract.* 2002;43(4):171-176.
17. Connery NA, McAllister H, Skelly C, Pawson P, Bellenger CR. Cellophane banding of congenital intrahepatic portosystemic shunts in two Irish wolfhounds. *J Small Anim Pract.* 2002; 43(8):345-349.
18. Hurn SD, Edwards GA. Perioperative outcomes after three different single extrahepatic portosystemic shunt attenuation techniques in dogs: partial ligation, complete ligation and ameroid constrictor placement. *Aust Vet J.* 2003;81(11):666-670.
19. Winkler JT, Bohling MW, Tillson DM, Wright JC, Ballagas AJ. Portosystemic shunts: diagnosis, prognosis, and treatment of 64 cases (1993-2002). *J Am Anim Hosp Assoc.* 2003;39(2): 169-185.
20. Kummeling A, Van Sluijs FJ, Rothuizen J. Prognostic implications of the degree of shunt narrowing and of the portal vein diameter in dogs with congenital portosystemic shunts. *Vet Surg.* 2004;33(1):17-24.
21. Hunt GB, Kummeling A, Tisdall PLC, et al. Outcomes of cellophane banding for congenital portosystemic shunts in 106 dogs and 5 cats. *Vet Surg.* 2004;33(1):25-31.
22. Kyles AE, Gregory CR, Adin CA. Re-evaluation of a portocaval venograft without an ameroid constrictor as a method for controlling portal hypertension after occlusion of intrahepatic portocaval shunts in dogs. *Vet Surg.* 2004;33(6):691-698.
23. Mehl ML, Kyles AE, Hardie EM, et al. Evaluation of ameroid ring constrictors for treatment for single extrahepatic portosystemic shunts in dogs: 168 cases (1995-2001). *J Am Vet Med Assoc.* 2005;226(12):2020-2030.
24. Lee KCL, Lipscomb VJ, Lamb CR, Gregory SP, Guitian J, Brockman DJ. Association of portovenographic findings with outcome in dogs receiving surgical treatment for single congenital portosystemic shunts: 45 cases (2000-2004). *J Am Vet Med Assoc.* 2006;229(7):1122-1129.
25. Frankel D, Seim H, MacPhail C, Monnet E. Evaluation of cellophane banding with and without intraoperative attenuation for treatment of congenital extrahepatic portosystemic shunts in dogs. *J Am Vet Med Assoc.* 2006;228(9):1355-1360.
26. Mehl ML, Kyles AE, Case JB, Kass PH, Zwingenberger A, Gregory CR. Surgical management of left-divisional intrahepatic portosystemic shunts: outcome after partial ligation of, or ameroid ring constrictor placement on, the left hepatic vein in twenty-eight dogs (1995-2005). *Vet Surg.* 2007; 36(1):21-30.
27. Landon BP, Abraham LA, Charles JA. Use of transcolonic portal scintigraphy to evaluate efficacy of cellophane banding of congenital extrahepatic portosystemic shunts in 16 dogs. *Aust Vet J.* 2008;86(5):169-179.
28. Worley DR, Holt DE. Clinical outcome of congenital extrahepatic portosystemic shunt attenuation in dogs aged five years and older: 17 cases (1992-2005). *J Am Vet Med Assoc.* 2008; 232(5):722-727.
29. Doran IP, Barr FJ, Hotston Moore A, Knowles TG, Holt PE. Liver size, bodyweight, and tolerance to acute complete occlusion of congenital extrahepatic portosystemic shunts in dogs. *Vet Surg.* 2008;37(7):656-662.
30. Torisu S, Washizu M, Hasegawa D, Orima H. Measurement of brain trace elements in a dog with a portosystemic shunt: relation between hyperintensity on T1-weighted magnetic resonance images in lentiform nuclei and brain trace elements. *J Vet Med Sci.* 2008;70(12):1391-1393.
31. Cariou MP, Lipscomb VJ, Hughes D, Brodbelt D, Brockman DJ. Plasma lactate concentrations and blood gas values in dogs undergoing surgical attenuation of a single congenital portosystemic shunt. *Vet Rec.* 2009;165(8): 226-229.
32. Gommeren K, Claeys S, de Rooster H, Hamaide A, Daminet S. Outcome from status epilepticus after portosystemic shunt attenuation in 3 dogs treated with propofol and phenobarbital. *J Vet Emerg Crit Care.* 2010;20(3):346-351.
33. Seki M, Asano K, Sakai M, et al. Serum hyaluronic acid in dogs with congenital portosystemic shunts. *J Small Anim Pract.* 2010;51(5):260-263.
34. Fryer KJ, Levine JM, Peycke LE, Thompson JA, Cohen ND. Incidence of postoperative seizures with and without levetiracetam pretreatment in dogs undergoing portosystemic shunt attenuation. *J Vet Intern Med.* 2011;25(6):1379-1384.
35. Lee KCL, Winstanley A, House J V, et al. Association between hepatic histopathologic lesions and clinical findings in dogs undergoing surgical attenuation of a congenital portosystemic shunt: 38 cases (2000-2004). *J Am Vet Med Assoc.* 2011;239(5): 638-645.
36. Weisse C, Berent AC, Todd K, Solomon JA, Cope C. Endovascular evaluation and treatment of intrahepatic portosystemic shunts in dogs: 100 cases (2001-2011). *J Am Vet Med Assoc.* 2014;244(1):78-94.
37. Kraun MB, Nelson LL, Hauptman JG, Nelson NC. Analysis of the relationship of extrahepatic portosystemic shunt morphology with clinical variables in dogs: 53 cases (2009-2012). *J Am Vet Med Assoc.* 2014;245(5):540-549.

38. Heidenreich DC, Giordano P, Kirby BM. Successful treatment of refractory seizures with phenobarbital, propofol, and medetomidine following congenital portosystemic shunt ligation in a dog. *J Vet Emerg Crit Care*. 2016;26(6):831-836.
39. Brunson BW, Case JB, Ellison GW, et al. Evaluation of surgical outcome, complications, and mortality in dogs undergoing preoperative computed tomography angiography for diagnosis of an extrahepatic portosystemic shunt: 124 cases (2005-2014). *Can Vet J*. 2016;57(1):59-64.
40. Case JB, Marvel SJ, Stiles MC, et al. Outcomes of cellophane banding or percutaneous transvenous coil embolization of canine intrahepatic portosystemic shunts. *Vet Surg*. 2018;47:O59-O66.
41. Strickland R, Tivers MS, Adamantos SE, Harcourt-Brown TR, Fowkes RC, Lipscomb VJ. Incidence and risk factors for neurological signs after attenuation of single congenital portosystemic shunts in 253 dogs. *Vet Surg*. 2018;47(6):745-755.
42. Van den Bossche L, van Steenbeek FG, Weber MF, et al. Genome-wide based model predicting recovery from portosystemic shunting after liver shunt attenuation in dogs. *J Vet Intern Med*. 2018;32(4):1343-1352.
43. Tivers MS, Lipscomb VJ, Bristow P, Brockman DJ. Intrahepatic congenital portosystemic shunts in dogs: short- and long-term outcome of suture attenuation. *J Small Anim Pract*. 2018;59(4):201-210.
44. Wallace ML, MacPhail CM, Monnet E. Incidence of postoperative neurologic complications in pugs following portosystemic shunt attenuation surgery. *J Am Anim Hosp Assoc*. 2018;54(1):46-49.
45. Traverson M, Lussier B, Huneault L, Gatineau M. Comparative outcomes between ameroid ring constrictor and cellophane banding for treatment of single congenital extrahepatic portosystemic shunts in 49 dogs (1998-2012). *Vet Surg*. 2018;47(2):179-187.
46. Mullins RA, Sanchez Villamil C, de Rooster H, et al. Effect of prophylactic treatment with levetiracetam on the incidence of postattenuation seizures in dogs undergoing surgical management of single congenital extrahepatic portosystemic shunts. *Vet Surg*. 2019;48(2):164-172.
47. Mullins RA, Sanchez Villamil C, Selmic LE, et al. Prognostic factors for short-term survival of dogs that experience postattenuation seizures after surgical correction of single congenital extrahepatic portosystemic shunts: 93 cases (2005-2018). *Vet Surg*. 2020;49(5):958-970.
48. Otomo A, Singh A, Jeong J, et al. Long-term clinical outcomes of dogs with single congenital extrahepatic portosystemic shunts attenuated with thin film banding or ameroid ring constrictors. *Vet Surg*. 2020;49(3):436-444.
49. Vallarino N, Pil S, Devriendt N, et al. Diagnostic value of blood variables following attenuation of congenital extrahepatic portosystemic shunt in dogs. *Vet Rec*. 2020;187(7):48.
50. Matiasovic M, Chanoit GPA, Meakin LB, Tivers MS. Outcomes of dogs treated for extrahepatic congenital portosystemic shunts with thin film banding or ameroid ring constrictor. *Vet Surg*. 2020;49(1):160-171.
51. Aronson LR, Gacad RC, Kaminsky-Russ K, Gregory CR, Mullen KD. Endogenous benzodiazepine activity in the peripheral and portal blood of dogs with congenital portosystemic shunts. *Vet Surg*. 1997;26(3):189-194.
52. Gow AG, Marques AIC, Yool DA, Duncan A, Mellanby RJ. Whole blood manganese concentrations in dogs with congenital portosystemic shunts. *J Vet Intern Med*. 2010;24(1):90-96.
53. Hazell AS, Desjardins P, Butterworth RF. Chronic exposure of rat primary astrocyte cultures to manganese results in increased binding sites for the "peripheral-type" benzodiazepine receptor ligand 3H-PK 11195. *Neurosci Lett*. 1999;271(1):5-8.
54. Torisu S, Washizu M, Hasegawa D, Orima H. Brain magnetic resonance imaging characteristics in dogs and cats with congenital portosystemic shunts. *Vet Radiol Ultrasound*. 2005;46(6):447-451.
55. Tivers MS, Handel I, Gow AG, Lipscomb VJ, Jalan R, Mellanby RJ. Hyperammonemia and systemic inflammatory response syndrome predicts presence of hepatic encephalopathy in dogs with congenital portosystemic shunts. *PLoS One*. 2014;9(1):e82303.
56. Or M, Peremans K, Martlé V, et al. Regional cerebral blood flow assessed by single photon emission computed tomography (SPECT) in dogs with congenital portosystemic shunt and hepatic encephalopathy. *Vet J*. 2017;220:40-42.
57. Holford AL, Tobias KM, Bartges JW, Johnson BM. Adrenal response to adrenocorticotrophic hormone in dogs before and after surgical attenuation of a single congenital portosystemic shunt. *J Vet Intern Med*. 2008;22(4):832-838.
58. Jalan R, Shawcross D, Davies N. The molecular pathogenesis of hepatic encephalopathy. *Int J Biochem Cell Biol*. 2003;35(8):1175-1181.
59. Williams A, Gow A, Kilpatrick S, et al. Astrocyte lesions in cerebral cortex and cerebellum of dogs with congenital ortosystemic shunting. *J Vet Sci*. 2020;21(3):e44.
60. Wallace ML, Ellison GW, Giglio RF, et al. Gradual attenuation of a congenital extrahepatic portosystemic shunt with a self-retaining polyacrylic acid-silicone device in 6 dogs. *Vet Surg*. 2018;47(5):722-728.
61. Moore SA, Muñana KR, Papich MG, Nettifee-Osborne J. Levetiracetam pharmacokinetics in healthy dogs following oral administration of single and multiple doses. *Am J Vet Res*. 2010;71(3):337-341.
62. Moore S, Muñana KR, Papich MG, Nettifee-Osborne JA. The pharmacokinetics of levetiracetam in healthy dogs concurrently receiving phenobarbital. *J Vet Pharmacol Ther*. 2011;34(1):31-34.
63. Muñana KR, Nettifee-Osborne JA, Papich MG. Effect of chronic administration of phenobarbital, or bromide, on pharmacokinetics of levetiracetam in dogs with epilepsy. *J Vet Intern Med*. 2015;29(2):614-619.
64. Berent A, Tobias KM. Hepatic vascular anomalies. In: Johnston SA, Tobias KM, eds. *Veterinary Surgery: Small Animal*. 2nd ed. Elsevier Saunders; 2018:1852-1886.

SUPPORTING INFORMATION

Additional supporting information may be found in the online version of the article at the publisher's website.

How to cite this article: Mullins RA, Escribano Carrera A, Anderson DM, et al. Postattenuation neurologic signs after surgical attenuation of congenital portosystemic shunts in dogs: A review. *Veterinary Surgery*. 2021;1-11. doi: 10.1111/vsu.13729