

What is the optimal management of recurrent non-functioning pituitary adenoma?

ORIGINAL RESEARCH

AUTHORS

Luke Ottewell

University of Bristol

Address for Correspondence:

Luke Ottewell
University of Bristol Medical
School
Queen's Road
Bristol
BS8 1QU

Email: lo16279@bristol.ac.uk

No conflicts of interest to declare.

Accepted for publication: 18.04.21

ABSTRACT

Recurrent non-functioning pituitary adenomas (NFPAs) pose a difficult challenge to neurosurgeons. NFPAs do not secrete hormones and thus symptoms usually manifest later in the disease process when the adenoma has reached a sufficient size as to cause mass effect on neighbouring bodies. Treatment of pituitary adenoma is commonly surgical with a transnasal, transsphenoidal approach. Growth of the NFPA into adjacent structures can add to the challenge of surgical resection and thus resection of NFPAs is sometimes incomplete. This often leads to recurrence and necessitates further treatment. A variety of treatment strategies may be employed to design an optimal treatment algorithm, and often a combination of these may be used depending on the size and location of the adenoma and age of the patient. This paper aims to present the evidence for each treatment strategy and to guide what the optimal treatment of NFPA may be, faced with the variety of outcomes that may arise from initial treatment.

INTRODUCTION

Recurrent non-functioning pituitary adenomas (RNFPAs) pose a difficult challenge to neurosurgeons. NFPAs do not secrete hormones, although they may be immunohistochemically positive, therefore patients usually manifest symptoms later in the disease process when the adenoma has reached a sufficient size as to cause mass effect on neighbouring bodies. (1, 2) Common presentations include headache, visual disturbance from compression of the optic apparatus, hypopituitarism from disturbance of the pituitary stalk, and more rarely cranial nerve compression from invasion into the cavernous sinus.

Treatment of pituitary adenoma is commonly surgical with a transnasal, transsphenoidal approach. Growth of the NFPA into adjacent structures can add to the challenge of surgical resection. Extension into the cavernous sinus may cause the adenoma to envelope the internal carotid artery – for instance. This would present a serious hazard for the surgeon, and thus resection of NFPAs is sometimes incomplete. A study by Lillehei et al. showed that 14% of resections of NFPA were sub-total, with 6% of the total number recurring at 5 years. (3) Another study by Young et al. reported on 100 NFPAs – 90% of which reported gross total resection – but 42% of which showed residual/recurrent tumour at 5 years follow-up. (4) Furthermore, suprasellar extension often presents a challenge as it leaves a portion of adenoma inaccessible from the transsphenoidal corridor. All of these factors make recurrence of the tumour more likely and thus may necessitate further treatment.

A variety of treatment strategies may be employed to design an optimal treatment algorithm, and often a combination of these – including endoscopic resection and radiotherapeutic means – may be used depending on the size and location of the adenoma and age of the patient. This paper aims to present the evidence for each treatment strategy and to guide the optimal treatment of NFPA on a case-to-case basis, including after disease recurrence. Although definite treatment strategies will be discussed, a “watch-and-wait” approach is often taken due to the relatively asymptomatic nature of the early stages of disease. The author of this paper conducted a literature review of all available data until January 2020. More details on the exact methodology of this search can be found as Appendix 1.

BACKGROUND AND HISTOLOGY

Pituitary adenomas are an important and common type of intracranial neoplasm, representing between 10–20% of all cases in adults. (1, 2) Treatment is commonly surgical for non-functioning and functioning adenomas alike, whilst prolactinomas are commonly treated medically. The advancement of the endoscopic technique has shown a strong emphasis put on this method as the mainstay of surgical treatment, although other techniques remain useful in certain situations. Treatment is sometimes accompanied by radiation therapy and in some occasions radiation therapy is the main treatment of choice.

NFPAs represent a group of tumours that do not manifest with endocrine symptoms due to hypersecretion of hormones. However, evidence has shown that the cells that make up these tumours do express, immunohistochemically, anterior pituitary hormones. (5) This evidence has contributed to recent attempts to rename NFPAs to non-functioning pituitary neuroendocrine tumours (NF-PitNETs). (6)

NFPAs can now be further distinguished by their transcription factor profile and by the pituitary hormone that they immunohistochemically express. The term null-cell adenoma has previously been used to refer to NFPAs but, with the use of this new classification, null-cell adenomas hold only a very small and rare profile. Cell lineages include somatotroph, lactotroph, thyrotroph, corticotroph and gonadotroph lineage, each with distinct hormone staining characteristics and transcription factors. Null cell adenomas, therefore, are exclusively those which show neither hormone staining nor transcription factors. Recent evidence has suggested that among NFPAs, gonadotroph adenomas make up 73% of all cases. (7)

A few papers have been published showing treatment results of groups of patients taking into account their immunohistochemical classification. This is an up-and-coming area of research and may improve treatment for NFPAs. (8, 9)

REPEAT SURGICAL RESECTION

Surgical resection is the first-line modality of treatment for NFPA, however, this does not necessarily dictate that it should be so for recurrent cases. With papers reporting recurrence rates between 44–75% at 10 years follow-up (10) it is of utmost importance to determine whether this modality is effective for recurrent NFPA. Advancement of surgical techniques and technology, such as intraoperative MRI and intraoperative identification of the optic nerve, have been shown to improve surgical outcomes. (11) Analysis of recurrence rates identified various factors that showed to have an impact on treatment outcome. Factors that augured a higher chance of recurrence included large tumour remnant and invasion into the adjacent cavernous sinus. On the other hand, good augurs of tumour control were identified to be small tumour remnant and old age. (10)

A study by Cavallo et al. reported on 59 patients who underwent repeat transsphenoidal surgery (TSS) endoscopically for recurrent NFPA. (12) 62% of the cases showed gross total resection on post-operative imaging. The study identified that patients who had previously undergone microsurgical rather than endoscopic TSS were more likely to achieve gross total resection, whereas patients who had already undergone endoscopic TSS portended to lower rates of total resection post-operatively.

Another larger study by Chang et al. reported lower gross total resection rates of 40% but did not distinguish as clearly between microsurgical and endoscopic approaches. (13) It similarly identified suprasellar extension and cavernous sinus invasion to be

a bad prognostic marker for total resection outcomes. This study did, however, highlight a rigorous breakdown of complication rates, with visual deterioration being experienced in 5% of cases, transient diabetes insipidus (DI) in 4.9%, permanent DI in 1.2%, postoperative hematoma in 2.5%, meningitis in 2.5% and perioperative mortality in 1.2%.

Literature has also been published discussing different surgical approaches, be they microscopic or endoscopic. Some surgeons have described approaches, such as interhemispheric or sub frontal, for accessing NFPA that have invaded into adjacent structures. (12, 14) However, the evidence suggests that endoscopic TSS brings shorter hospital stay, less patient discomfort and reduced perioperative morbidity. (15) A study by the University of Virginia group supported this, finding that 70% of patients undergoing microsurgical resection had intraoperative lumbar drain placement, compared to only 1.7% of patients who underwent endoscopic resection. (15)

ADJUVANT RADIOTHERAPY POST-OPERATIVELY

Adjuvant radiotherapy may be used post-operatively, both in the first surgical instance and in recurring cases. The timing of radiotherapy is a highly debated subject. A study in northern Italy studied tumour recurrence or regrowth in 226 patients who had undergone treatment for NFPA. (16) Each patient was followed-up for a minimum of 5 years. Patients were divided into three categories - A: those who showed no radiological signs of tumour residue post-operatively (n=73); B: those who showed signs of postoperative tumour residue but did not undergo radiotherapy (n=77); C: those who showed signs of postoperative tumour residue and underwent radiotherapy. In group A, recurrence occurred in 14/73 patients (19.2%), after a mean period of 7.5 years; group B showed tumour regrowth in 45/77 patients (58.4%) after a mean period of 5.3 years; group C showed tumour regrowth in 14/76 patients (18.4%) after a mean period of 8.1 years. The choice of radiotherapy in this study was stereotactic radiotherapy.

STEREOTACTIC RADIOSURGERY FOR RECURRING NFPA

Stereotactic radiosurgery (SRS) has been abundantly discussed in pituitary literature. The mechanism by which it works is delivering a very high dose of ionising radiation to a highly accurate point. This is highly beneficial as it spares the surrounding structures of radiation. Furthermore, it is usually delivered in a single dose. Notwithstanding this, it can also be delivered in different sessions, called fractionated radiotherapy (XRT). Stereotactic radiosurgery and stereotactic radiotherapy differ in that stereotactic radiosurgery is a single, high dose of radiation, as opposed to stereotactic radiotherapy which uses lower fractionated doses of radiation over several sessions. The term stereotactic refers to the frame and technique used to administer these therapies, wherein the patient's head is clamped into a frame, which in turn is used to standardise coordinates of the patient's brain to be able to map the therapeutic area.

Various factors may lead the clinician and patient towards deciding which type of radiotherapy to undergo. Convenience is a strong factor leading to choose SRS. Location of the adenoma is also a factor which must be strongly considered in making this decision. If the target is between 3-5mm from the optic pathway, SRS may be contraindicated due to the risk of damaging the optic apparatus. Large size of adenoma is also a contraindication for SRS, as it may be too large to irradiate with a single dose. Therefore, appropriate and detailed contouring of the adenoma is of utmost importance. This can adopt the form of stereotactic MRI and/or CT.

There are various mechanisms of delivery of SRS. Gamma-knife (GKS) is a frequently used mechanism that employs radioactive isotope Cobalt-60. Linear accelerators are also widely used to deliver SRS. These accelerate electrons and convert this energy to high-energy X-rays, also called photons. Cyberknife is another mechanism but can deliver both stereotactic and fractionated radiotherapy. It also is a linear accelerator but is much smaller and is mounted on a movable arm. This allows for higher patient comfort, with greater mobility and flexibility of positioning. Finally, there is proton-therapy, which employs high energy protons from a cyclotron or synchrotron. The main benefit of this technique is that it greatly reduces exposure of surrounding tissues to treatment, therefore may be associated with fewer complications and side-effects. Radiosurgery is image-guided and affords sub-millimetre accuracy.

A case-control study by Picozzi et al. divided two sets of patients with recurrent NFPA into: G1 - observation (n=68) and G2 - receive GKS (n=51). (17) This showed that progression-free survival was achieved in 51.1% of patients who were observed for an average of 41.6 months, compared to progression-free survival of 89.8% of those who received GKS and were followed-up for an average of 40.6 months. In a larger study by Sheehan et al. in 2013, 512 patients who had undergone Gamma-knife surgery for recurrent NFPA were studied. (18) They were followed up for 36 months and showed a tumour control rate of 93.4%. Progressive-free survival was 98% (3 years), 95% (5 years), 91% (8 years) and 85% (10 years). It identified that patients with a smaller adenoma volume had a favourable outcome, and conversely suprasellar extension was found to be an unfavourable factor. 21% of patients suffered from hypopituitarism post-operatively, and 9% showed new cranial nerve deficits.

A study by Wilson et al. observed patients who had undergone treatment for recurrent NFPA in the form of SRS, fractionated stereotactic radiation therapy (FSRT) and conformal radiotherapy (CRT). (19) Those who underwent SRS (n=51) showed 100% progressive-free survival at 5 years, compared to those who underwent FRST (n=67) and CRT (n=53), with 93% and 87% progression-free survival respectively. A review by the Congress of Neurological Surgeons (CNS) reviewed all available studies on SRS for NFPA, in which it identified 24 independent studies which showed tumour control from 83% to 100%. (10)

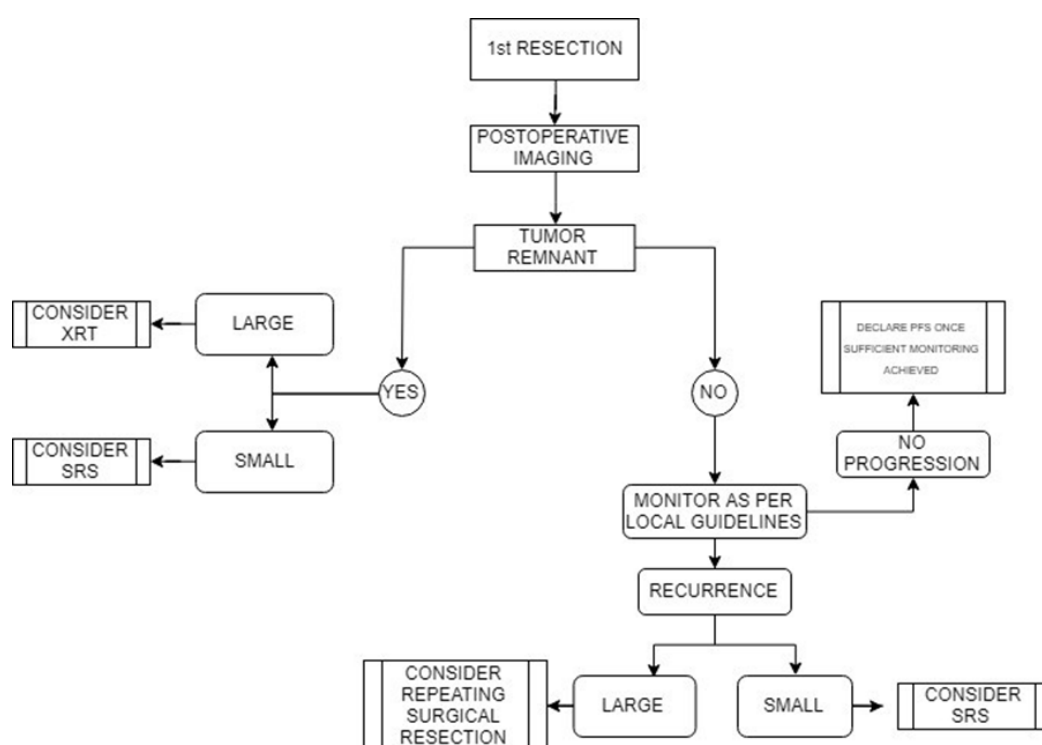
FRACTIONATED RADIATION THERAPY

Conventional radiation therapy (RT) has been used for decades in the treatment of recurrent NFPA and has been the subject of much scientific research. Earlier models of RT used four-field techniques, whereas in the past ten years the emergence of more advanced, three-dimensional conformal RT, as well as intensity-modulated techniques, have predominated. Radiation therapy for NFPA is fractionated, delivering 45-54 Gy in total over 5-6 weeks, five days a week. Each fraction, therefore, approximates to around 1.8-2 Gy per day. Fractionated radiation therapy itself has several subtypes which include conventional fractionated radiation therapy (XRT), intensity-modulated radiation therapy (IMRT) and stereotactic radiation therapy (SRT).

A study by Chang et al. described 663 patients treated with RT for recurrent NFPA. (20) Each one was followed-up for 101 months. Tumour control was achieved in 90.3%, and progression-free survival was achieved in 93%, 87%, 81% at 5, 10 and 15 years respectively. This study also found cavernous sinus invasion and subtotal previous resection to be unfavourable factors. Another study by Losa et al. grouped patients into 3 groups: G1 – showed no tumour on postoperative imaging (n=279), G2 – showed residual tumour on postoperative imaging but did not undergo RT (n=76) and G3 – showed residual tumour and underwent RT (n=81). The study found that progression-free survival was achieved in 87.1% of G1, 39.2% of G2 and 100% of G3. (21)

Figure 1:

Proposed algorithm for the management of recurrent non-functioning pituitary adenomas.



Breen et al. reported on a cohort of 120 patients who had undergone XRT for recurrent NFPA, and progression-free survival was reported to be 87.5%, 77.6% and 64.7% at 10, 20 and 30 years after XRT, accordingly. (22) This large study also described the complications of the procedure and announced 0.8% developed optic and oculomotor neuropathy, whilst 1.7% developed radiation-induced neoplasms. Complications following radiation therapy often manifested as post-operative side-effects, namely nausea and vomiting, which were found to last between 1-2 months. However, the most common side effect of RT was hypopituitarism, described as highly as in 88% of cases in one study by Langsenlehner. (23) On average, tumour control following XRT or SRT was between 74% to 100% in 20 studies available.

SUMMARY AND CONCLUSION

Each treatment modality discussed has a role in the treatment of RNFPA. The indications for each modality are varied and often made on a case-by-case basis, dictated often by the anatomy of the patient and the nature of the tumour. However, a summary of the possible scenarios has been designed to summarise the above points.

Analysis of all available data has been useful to highlight that recurrent NFPA responds to different treatment strategies. Large remaining tumour size and invasion into adjacent structures, such as the cavernous sinus, have been shown to increase the chance of recurrence of NFPA. On the other hand, small tumour remnant size and old age have both been associated with a smaller chance of recurrence. As highlighted before, studies have highlighted that 40-60% of patients undergoing repeat resection for recurrent NFPA achieve Progression-free Survival (PFS). (10-14) Evidence suggests there is a higher chance of achieving PFS via

endoscopic transsphenoidal surgery if the first attempted resection was microsurgical. (12) Conversely, repeating endoscopic transsphenoidal surgery is associated with a lower chance of total resection. Endoscopic transsphenoidal resection for NFPA, however, has lower associated complications and perioperative morbidity. It is also important to highlight the importance of adjuvant perioperative radiation therapy. Adjuvant RT in patients with clear postoperative tumour remnant was shown to decrease tumour recurrence by 40% in one study. (16)

Stereotactic radiosurgery has also been shown to be effective in the treatment of recurrent NFPA. One study saw PFS achieved in almost 90% of patients treated, compared to 50% of the controlled, observed group. (17) It has been shown to be particularly effective in small tumour remnants. Larger tumour size and invasion into the cavernous sinus have been shown to diminish the effectiveness of SRS, on the other hand. Although the risks of radiation to the body in SRS are lesser, they are not non-existent: due to its high intensity of radiation in a specific spot, it is contraindicated if the irradiation aim is close to the optic apparatus. Hypopituitarism has also been described in frequencies of 0-40%. Cranial nerve deficits are rare but must be considered, described in 0-13% of patients in different studies. (10, 17-19)

Finally, conventional radiation therapy has been shown to be highly effective in treating NFPA. In one study, it achieved almost 60% more PFS when given RT after post-operative imaging revealed tumour remnant, compared to those in whom tumour remnant was also detected but were not administered RT. (21) However, as many as 88% of patients have been described to develop postoperative hypopituitarism. It has also been associated with radiation-associated neoplasms, described in 1-2% of all cases. (22) As a closing statement: although above has discussed what is the best treatment method to employ, very often the “watch-and-wait” method is the method elected. The indications for employing this option are varied and non-specific; often it is simply the clinician’s clinical judgement which makes this decision. Evidence of tumour remnant in a very elderly patient would not necessarily require action, which would often bring much more morbidity and worry to the patient than the small tumour remnant could do in the next ten years. Therefore, a case-by-case approach, based on strong dialogue between patient and surgeon is often the most effective treatment algorithm.

Acknowledgements

I would like to sincerely thank Mr Adam Williams for supervising this project, for his input and invaluable teaching on this topic. I would also like to extend a warm thanks to this surgical team, registrar and juniors for their time. A special thanks to the Medical School Education Centre for facilitating their expertise on the topic of literature searches, without whom this paper would have been the lesser.

REFERENCES

1. Dekkers OM, Pereira AM, Romijn JA: Treatment and follow-up of clinically nonfunctioning pituitary macroadenomas. *Journal of Clinical Endocrinology & Metabolism*. 2008;93:3717-26.
doi: 10.1210/jc.2008-0643
PMID: 18682516
2. Vance ML: Treatment of patients with a pituitary adenoma: one clinician's experience. *Neurosurgical Focus*. 2004;16:1-6.
doi: 10.3171/foc.2004.16.4.2
PMID: 15191330
3. Lillehei KO, Kirschman DL, Kleinschmidt-DeMasters BK, et al.: Reassessment of the role of radiation therapy in the treatment of endocrine-inactive pituitary macroadenomas. *Neurosurgery*. 1998;43:432-8.
doi: 10.1097/00006123-199809000-00020
PMID: 9733298
4. Young Jr WF, Scheithauer BW, Kovacs KT, et al.: Gonadotroph adenoma of the pituitary gland: a clinicopathologic analysis of 100 cases. *Mayo Clinic Proceedings*. 1996;71:649-56.
doi: 10.1016/S0025-6196(11)63002-4
PMID: 8656706
5. Rindi G., Klimstra DS, Abedi-Ardekani B, et al.: A common classification framework for neuroendocrine neoplasms: an International Agency for Research on Cancer (IARC) and World Health Organization (WHO) expert consensus proposal. *Modern Pathology*. 2018;31(12):1770.
doi: 10.1038/s41379-018-0110-y
PMID: 30140036 PMCID: PMC6265262
6. Asa SL, Casar-Borota O, Chanson P, et al.: From pituitary adenoma to pituitary neuroendocrine tumor (PitNET): an International Pituitary Pathology Club proposal. *Endocrine Related Cancer*. 2017;24(4):5-8.
doi: 10.1530/ERC-17-0004
PMID: 28264912
7. Nishioka H, Inoshita N, Mete O, et al.: The complementary role of transcription factors in the accurate diagnosis of clinically nonfunctioning pituitary adenomas. *Endocrine pathology*. 2015;26(4):349-55.
doi: 10.1007/s12022-015-9398-z
PMID: 26481628

8. Vieira Neto L, Wildemberg LE, Moraes AB, et al.: Dopamine receptor subtype 2 expression profile in nonfunctioning pituitary adenomas and in vivo response to cabergoline therapy. *Clinical Endocrinology*. 2015;82:739-46.

doi: 10.1111/cen.12684

PMID: 25418156

9. Tampourlou M, Ntali G, Ahmed S, Arlt W, Ayuk J, Byrne JV, et al. Outcome of nonfunctioning pituitary adenomas that regrow after primary treatment: a study from two large UK centers. *The Journal of Clinical Endocrinology and Metabolism*. 2017; 102:1889-97.

doi: 10.1210/jc.2016-4061

PMID: 28323946

10. Sheehan J, Lee C, Bodach ME, Tumialan LM, Oyesiku NM, Patil CG, et al. Congress of neurological surgeons systematic review and evidence-based guideline for the management of patients with residual or recurrent nonfunctioning pituitary adenomas. USA: Congress of Neurological Surgeons; 2016 [accessed August 2019]. Available from: <https://www.cns.org/guidelines/browse-guidelines-detail/7-management-of-patients-with-residual-recurrent-n>.

11. Fahlbusch R, Buchfelder M. Transsphenoidal surgery of parasellar pituitary adenomas. *Acta neurochirurgica*. 1988;92:93-9.

doi: 10.1007/BF01401978

PMID: 3407479

12. Cavallo LM, Solari D, Tasiou A, Esposito F, de Angelis M, D'Enza AI, et al. Endoscopic endonasal transsphenoidal removal of recurrent and regrowing pituitary adenomas: experience on a 59-patient series. *World neurosurgery*. 2013;80:342-50.

doi: 10.1016/j.wneu.2012.10.008

PMID: 23046913

13. Chang EF, Sughrue ME, Zada G, Wilson CB, Blevins Jr LS, Kunwar S. Long term outcome following repeat transsphenoidal surgery for recurrent endocrine-inactive pituitary adenomas. *Pituitary*. 2010; 13:223-9.

doi: 10.1007/s11102-010-0221-z

PMID: 20217484 PMCID: PMC2913003

14. Leung GKK, Law HY, Hung KN, Fan YW, Lui WM. Combined simultaneous transcranial and transsphenoidal resection of large-to-giant pituitary adenomas. *Acta neurochirurgica*. 2011;153:1401-8.

doi: 10.1007/s00701-011-1029-y

PMID: 21533660 PMCID: PMC3111555

15. Dallapiazza R, Bond AE, Grober Y, Louis RG, Payne SC, Oldfield EH, et al. Retrospective analysis of a concurrent series of microscopic versus endoscopic transsphenoidal surgeries for Knosp Grades 0-2 nonfunctioning pituitary

macroadenomas at a single institution. *Journal of neurosurgery*. 2014;511:517.

doi: 10.3171/2014.6.JNS131321

PMID: 24995783

16. Ferrante E, Ferraroni M, Castrignanò T, Menicatti L, Anagni M, Reimondo G, et al. Non-functioning pituitary adenoma database: a useful resource to improve the clinical management of pituitary tumors. *European Journal of Endocrinology*. 2006;155:823-9.

doi: 10.1530/eje.1.02298

PMID: 17132751

17. Picozzi P, Losa M, Mortini P, Valle MA, Franzin A, Attuati L, et al. Radiosurgery and the prevention of regrowth of incompletely removed nonfunctioning pituitary adenomas. *Journal of neurosurgery*. 2005;102:71-4.

doi: 10.3171/jns.2005.102.s_supplement.0071

PMID: 15662784

18. Sheehan JP, Starke RM, Mathieu D, Young B, Sneed PK, Chiang VL, et al. Gamma Knife radiosurgery for the management of nonfunctioning pituitary adenomas: a multicenter study. *Journal of neurosurgery*. 2013;119:446-56.

doi: 10.3171/2013.3.JNS12766 P

MID: 23621595

19. Wilson PJ, De-Loyde KJ, Williams JR, Smee RI. A single centre's experience of stereotactic radiosurgery and radiotherapy for non-functioning pituitary adenomas with the Linear Accelerator (Linac). *Journal of Clinical Neuroscience*. 2012;19:370-4.

doi: 10.1016/j.jocn.2011.07.025

PMID: 22277561

20. Chang EF, Zada G, Kim S, Lamborn KR, Quinones-Hinojosa A, Tyrrell JB, et al. Long-term recurrence and mortality after surgery and adjuvant radiotherapy for nonfunctional pituitary adenomas. *Journal of neurosurgery*. 2008;108:736-45.

doi: 10.3171/JNS/2008/108/4/0736

PMID: 18377253

21. Losa M, Mortini P, Barzaghi R, Ribotto P, Terreni MR, Marzoli SB, et al. Early results of surgery in patients with nonfunctioning pituitary adenoma and analysis of the risk of tumor recurrence. *Journal of neurosurgery*. 2008;108:525-32.

doi: 10.3171/JNS/2008/108/3/0525

PMID: 18312100

22. Breen P, Flickinger JC, Kondziolka D, Martinez AJ. Radiotherapy for nonfunctional pituitary adenoma: analysis of long-term tumor control. *Journal of neurosurgery*. 1998;89:933-8.

doi: 10.3171/jns.1998.89.6.0933

PMID: 9833818

23. Langsenlehner T, Stiegler C, Quehenberger F, Feigl GC, Jakse G, Mokry M, et al. Long-term follow-up of patients with pituitary macroadenomas after postoperative radiation therapy. *Strahlentherapie und Onkologie*. 2007;183:241-7.

doi: 10.1007/s00066-007-1706-1

PMID: 17497095

APPENDIX

The author collaborated with a librarian at the University Hospital Bristol Education Centre to conduct the literature search. The author and librarian searched PubMed using previously published search strategies to concrete the relevant literature. Below is the employed search strategy:

1. Pituitary Neoplasms [Mesh] OR Adenoma [Mesh] OR Adenoma, Chromophobe [Mesh]
2. Microadenoma*[Title/Abstract] OR adenoma*[Title/Abstract] OR macroadenoma*[Title/Abstract] OR incidentaloma*[Title/Abstract] OR chromophobe*[Title/Abstract] OR transsphenoidal*[Title/Abstract])
3. Ppituitary[Title/Abstract] OR hypophyse*[Title/Abstract] OR sellar[Title/Abstract] OR transsphenoidal[Title/Abstract])
4. #1 OR (#2 AND #3)
5. Residual[Title/Abstract] OR recurr*[Title/Abstract])
6. #4 AND #5
7. NOT Comment[pt] NOT Letter[pt] Limit to English, Humans, publication date to 01/01/2020



The **British Student Doctor** is an open access journal, which means that all content is available without charge to the user or his/her institution. You are allowed to read, download, copy, distribute, print, search, or link to the full texts of the articles in this journal without asking prior permission from either the publisher or the author.

bsdj.org.uk



[/thebsdj](https://www.facebook.com/thebsdj)



[@thebsdj](https://twitter.com/thebsdj)



[@thebsdj](https://www.instagram.com/thebsdj)

Journal DOI

[10.18573/issn.2514-3174](https://doi.org/10.18573/issn.2514-3174)

Issue DOI

[10.18573/bsdj.v5i3](https://doi.org/10.18573/bsdj.v5i3)



The **British Student Doctor** is published by **The Foundation for Medical Publishing**, a charitable incorporated organisation registered in England and Wales (Charity No. 1189006), and a subsidiary of **The Academy of Medical Educators**.

This journal is licensed under a Creative Commons Attribution-NonCommercial-NoDerivatives 4.0 International License. The copyright of all articles belongs to **The Foundation for Medical Publishing**, and a citation should be made when any article is quoted, used or referred to in another work.



Cardiff University Press
Gwasg Prifysgol Caerdydd

The **British Student Doctor** is an imprint of Cardiff University Press, an innovative open-access publisher of academic research, where 'open-access' means free for both readers and writers.

cardiffuniversitypress.org