


## RESEARCH ARTICLE

# Measurement of femoral axial offset

Shohei Matsubayashi<sup>1</sup>  | Yuusaku Isobe<sup>1</sup> | Ko Chiba<sup>1</sup> | Ritsu Tsujimoto<sup>1</sup> | Makoto Osaki<sup>1</sup> | Takeshi Imamura<sup>2</sup> | Toshiyuki Tsurumoto<sup>2</sup>

<sup>1</sup>Department of Orthopedic Surgery, Graduate School of Biomedical Sciences, Nagasaki University, Nagasaki, Japan

<sup>2</sup>Department of Macroscopic Anatomy, Nagasaki University Graduate School of Biomedical Sciences, Nagasaki, Japan

## Correspondence

Shohei Matsubayashi, Department of Orthopedic Surgery, Graduate School of Biomedical Sciences, Nagasaki University, Nagasaki, Japan.

Email: bayazarov@gmail.com

## Abstract

Purpose to examine the accuracy and reproducibility of the femoral axial offset measured from the retrocondylar plane by computed tomography (CT). Bone specimens of the femur of 15 males and 15 females were analyzed. CT imaging was performed and data of the coordinates were collected (center of femoral head, center of an ellipse around greater trochanter, center of an ellipse around the base of femoral neck, posterior edge of great trochanter, and both posterior condyles). The angle between the line connecting center of the femoral head and center of an ellipse around greater trochanter and the line connecting both posterior condyles was set as anteversion 1. The angle between the line connecting the center of femoral head and center of an ellipse around base of the femoral neck and the line connecting both posterior condyles was set as anteversion 2. The femoral axial offset was measured from the retrocondylar plane. Measurements were performed three times on the same subject, and intrarater reliability (ICC) was determined. In addition, interrater reliability (ICC) was determined by comparing data from three raters. The mean value for anteversion 1 was 20.1° for males and 22.7° for females. The values for anteversion 2 were 16.0° and 19.9° for males and females, respectively. Offset was 34.0 and 33.4 mm in males and females, respectively. Intrarater ICC and interrater ICC exceeded 0.81 for both methods, suggesting that the method of measurement was reliable. Accuracy and reproducibility of the measurement of femoral axial offset from the retrocondylar plane were high.

## KEYWORDS

bone, hip

## 1 | INTRODUCTION

It is not clear why femoral anteversion is expressed as an angle. In external rotation femoral osteotomy, the external rotation angle of the hip increases while the internal rotation angle decreases. In internal rotation femoral osteotomy, the internal rotation angle of the hip increases while the external rotation angle decreases. Thus, with

respect to perception, it is easier to understand femoral anteversion when it is expressed as an angle. However, cases where the predicted hip rotation angle cannot be obtained, despite proper osteotomy having been performed, are often experienced in clinical practice.

When only rotation femoral osteotomy is performed, it is easy to evaluate femoral anteversion after surgery. However, when rotation

This is an open access article under the terms of the Creative Commons Attribution-NonCommercial-NoDerivs License, which permits use and distribution in any medium, provided the original work is properly cited, the use is non-commercial and no modifications or adaptations are made.

© 2020 The Authors. *Journal of Orthopaedic Research*® published by Wiley Periodicals LLC on behalf of Orthopaedic Research Society

and flexion/extension femoral osteotomy is performed, it is difficult to evaluate femoral anteversion after surgery. Therefore, we considered a method that can evaluate femoral anteversion even when flexion/extension femoral osteotomy is added to rotation osteotomy.

There are many methods for measuring femoral anteversion. Two-dimensional (2D) measurement methods using computed tomography (CT)<sup>1-5</sup> and 3D measurement methods<sup>6</sup> are available. The reproducibility of the measurements recorded with the respective measurement methods is reported to be high.<sup>6,7</sup> However, there is no specific method for measuring femoral anteversion as no method has been proven to be conclusively superior to date. It is difficult to define femoral anteversion because femoral torsion in 3D is being measured in 2D, and there is no femoral head center in extension of the longitudinal axis of the neck of the femur.<sup>8</sup> There are concerns regarding whether measurement of femoral anteversion by an angle is the correct approach. We have measured femoral anteversion as an axial offset from the retrocondylar plane and have reported our findings here.

## 2 | AIM

To examine accuracy and reproducibility of the femoral axial offset measured from the retrocondylar plane by CT.

## 3 | SUBJECTS

The right femoral bone specimens of 15 males and 15 females with a mean age of 61.3 years (20–79 years) are stored at the Department of Macroscopic Anatomy, Nagasaki University Graduate School of Biomedical Sciences.

All procedures performed in this study were in accordance with the ethical standards of the Ethics Committee of Nagasaki University Graduate School of Biomedical Sciences (approval number: 15033076) and of the 1964 Declaration of Helsinki and its later amendments or comparable ethical standards.

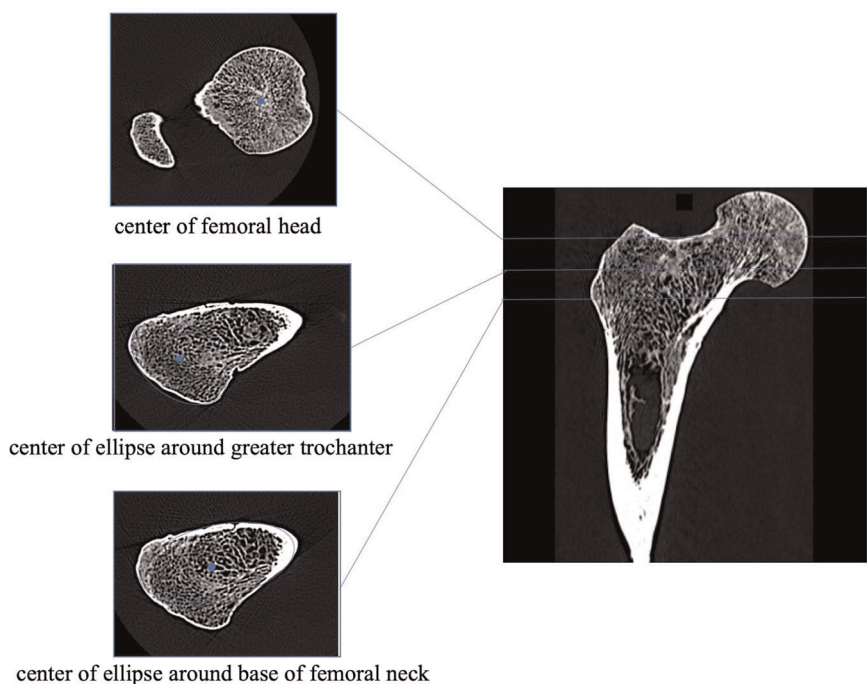
## 4 | METHODS

Imaging was performed using a Toshiba Activision 16<sup>®</sup>CT. The specimens were obtained with their longitudinal axis along the CT bench for scanning. The scans were all reformatted to transverse slices with a slice distance of 0.5 mm and a slice thickness of 0.5 mm. The matrix was 512 × 512 pixels. The coordinates were measured for the DICOM data using YAMAKI DICOM Tools ver1.1.5.0 (Department of Diagnostic Imaging and Nuclear Medicine, Graduate School of Medicine Kyoto University, Kyoto, Japan) and EV Insite S 3.2.1.3 (Public and social system solution Provider, Tokyo, Japan).

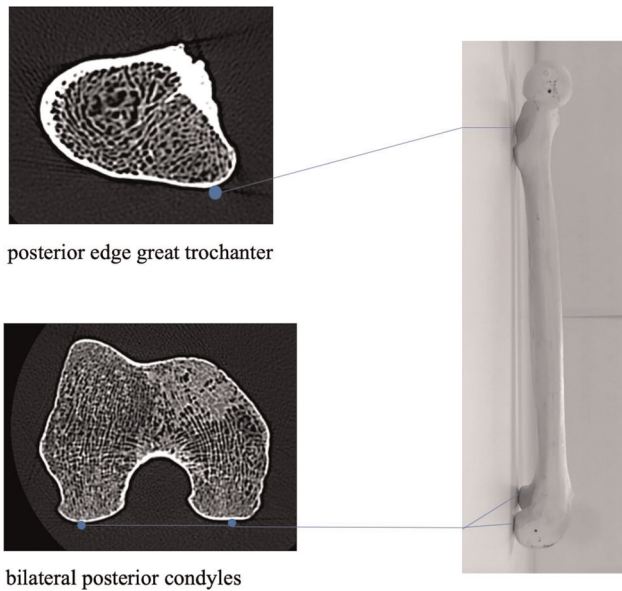
### 4.1 | Parameters of femoral torsion and offset

We determined (1) the center of the widest femoral head diameter as the center of the femoral head (Figure 1); (2) the center of an ellipse around the greater trochanter on a transverse slice located between the tip of the greater trochanter and the minor trochanter (Figure 1); (3) the center of an ellipse around the base of the femoral neck on a transverse slice (Figure 1); and (4) the posterior edge of the great trochanter and the bilateral posterior condyles (Figure 2).

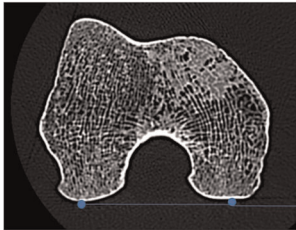
The angle between the line connecting the center of the femoral head and the center of an ellipse around the greater trochanter and



**FIGURE 1** The coordinates of the center of the femoral head, the center of an ellipse around the greater trochanter, and the center of an ellipse around the base of the femoral neck [Color figure can be viewed at [wileyonlinelibrary.com](http://wileyonlinelibrary.com)]

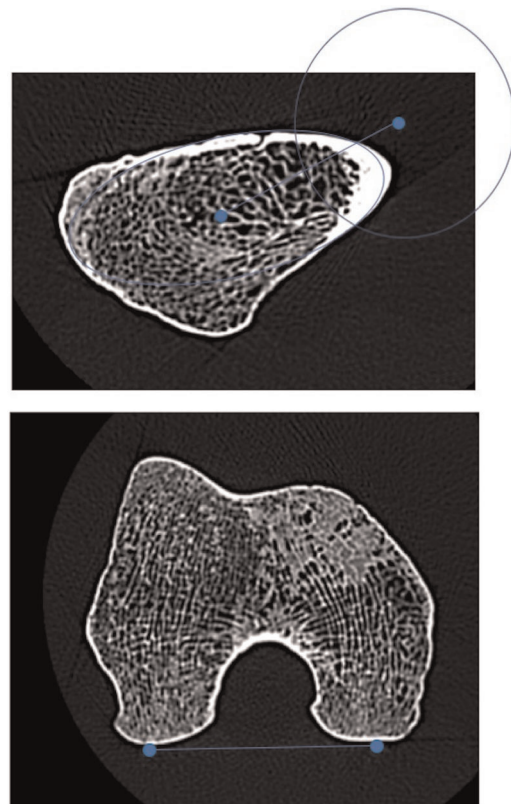


posterior edge great trochanter

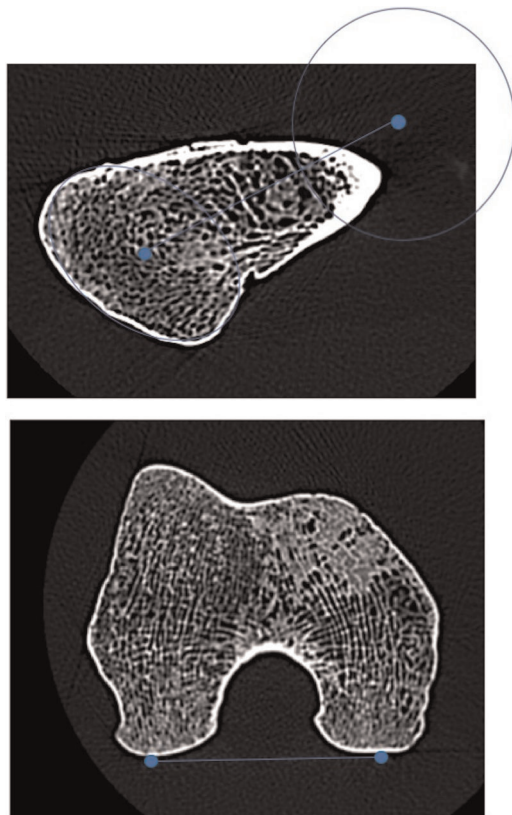


bilateral posterior condyles

**FIGURE 2** The coordinates of the posterior edge of the great trochanter and the bilateral posterior condyles [Color figure can be viewed at [wileyonlinelibrary.com](http://wileyonlinelibrary.com)]



**FIGURE 4** The angle between the line connecting the center of the femoral head and the center of an ellipse around the base of the femoral neck made and the line connecting both the posterior condyles was defined as anteversion 2 [Color figure can be viewed at [wileyonlinelibrary.com](http://wileyonlinelibrary.com)]



**FIGURE 3** The angle between the line connecting the center of the femoral head and the center of an ellipse around the greater trochanter and the line connecting both the posterior condyles was defined as anteversion 1 [Color figure can be viewed at [wileyonlinelibrary.com](http://wileyonlinelibrary.com)]

the line connecting both the posterior condyles was defined as anteversion 1 (Figure 3).<sup>1</sup> The angle between the line connecting the center of the femoral head and the center of an ellipse around the base of the femoral neck made and the line connecting both the posterior condyles was defined as anteversion 2 (Figure 4).<sup>2</sup>

The retrocondylar plane consists of the posterior edge of the great trochanter and the two posterior condyles. The retrocondylar plane corresponds to the tabletop plane on which the femur is placed, so it is also called the tabletop plane (Figure 5).<sup>9</sup> The shortest distance of the center of the femoral head from the retrocondylar plane was defined as the femoral axial offset (Figure 5).

The coordinates of the site closest to the neck and the site closest to the intercondylar area were determined and the two distances defined as the femur length (Figure 6).

Data of the respective coordinates obtained was inputted into a Microsoft® Excel for Mac ver16.16.9 so that the respective angles and distances could be calculated automatically. The formula is as follows.

Center of the femoral head x coordinate:  $H_x$

Center of the femoral head y coordinate:  $H_y$

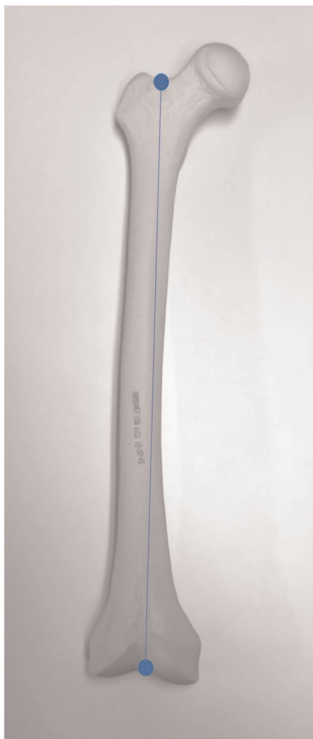Center of the femoral head z coordinate:  $H_z$

Center of an ellipse around the greater trochanter x coordinate:  $G_x$

**FIGURE 5** The shortest distance of the center of the femoral head from the retrocondylar plane was defined as the femoral axial offset [Color figure can be viewed at [wileyonlinelibrary.com](http://wileyonlinelibrary.com)]



Center of an ellipse around the greater trochanter y coordinate: Gy  
 Center of an ellipse around the base of the femoral neck x coordinate: Nx  
 Center of an ellipse around the base of the femoral neck y coordinate: Ny  
 Posterior edge of the great trochanter x coordinate: Px  
 Posterior edge of the great trochanter y coordinate: Py  
 Posterior edge of the great trochanter z coordinate: Pz  
 Medial posterior condyles x coordinate: Mx  
 Medial posterior condyles y coordinate: My  
 Medial posterior condyles z coordinate: Mz  
 Lateral posterior condyles x coordinate: Lx  
 Lateral posterior condyles y coordinate: Ly  
 Lateral posterior condyles z coordinate: Lz



**FIGURE 6** The coordinates of the site closest to the neck and the site closest to the intercondylar area were determined and the two distances defined as the femur length [Color figure can be viewed at [wileyonlinelibrary.com](http://wileyonlinelibrary.com)]

Anteversion 1

$$= \arccosine \frac{(Gx - Hx) \times (Lx - Mx) + (Gy - Hy) \times (Ly - My)}{\sqrt{(Gx - Hx)^2 + (Gy - Hy)^2} \times \sqrt{(Lx - Mx)^2 + (Ly - My)^2}} \times 180^\circ/\pi.$$

Anteversion 2

$$= \arccosine \frac{(Nx - Hx) \times (Lx - Mx) + (Ny - Hy) \times (Ly - My)}{\sqrt{(Nx - Hx)^2 + (Ny - Hy)^2} \times \sqrt{(Lx - Mx)^2 + (Ly - My)^2}} \times 180^\circ/\pi.$$

Femoral axial offset

$$= 1\text{pixel length} \times \frac{|Hx - A \times Hy - B \times Hz + c|}{\sqrt{A^2 + B^2 + 1}},$$

$$A = \frac{(Lz - Mz) \times Px + (Pz - Lz) \times Mx + (Mz - Pz) \times Lx}{(Lz - Mz) \times Py + (Pz - Lz) \times My + (Mz - Pz) \times Ly},$$

$$B = \frac{(Ly - My) \times Px + (Py - Ly) \times Mx + (My - Py) \times Lx}{(Ly - My) \times Pz + (Py - Ly) \times Mz + (My - Py) \times Lz},$$

$$C = -Px + A \times Py + B \times Pz.$$

## 4.2 | Statistical analysis

To determine the intra-rater errors, three measurements were performed over a period of at least 1 week by an orthopedic surgeon (Shohei Matsubayahi), who had more than 10 years of experience. To determine the inter-rater errors, two orthopedic surgeons (Shohei Matsubayahi and Takeshi Imamura) with more than 10 years of experience, and a medical student (Yuusaku Isobe) performed the measurements. All the observers were initially instructed in CT measurement technique on different single-femur CT Scans in advance, before the data were recorded. For the statistical analyses, IBM SPSS Statics Version 21.0 (IBM Corporation) was used. Intra- and Inter-rater agreement was graded according to Landis and Koch,<sup>10</sup> who characterized values <0 as indicating no agreement, 0–0.21 as slight, 0.21–0.40 as fair, 0.41–0.60 as moderate, 0.61–0.80 as substantial, and 0.81–1 as almost perfect. In addition, a regression analysis was performed for anteversion 1 and offset/length, and

**TABLE 1** Average value

Anteversion 1	
M	20.1° ± 7.8°
F	22.7° ± 5.0°
Anteversion 2	
M	16.0° ± 8.0°
F	19.9° ± 5.4°
Offset	
M	34.0 ± 5.3 mm
F	33.4 ± 3.8 mm

anteversion 2 and offset/length, and the correlation coefficient was determined. For the statistical analyses, Microsoft® Excel for Mac ver16.16.9 and JMP Pro, Version 12. (SAS Institute Inc) were used. A  $p < .01$  was considered a significant difference.

## 5 | RESULTS

The mean value for the anteversion 1 angle was 20.1° ± 7.8° for males, and 22.7° ± 5.0° for females. The values for the anteversion 2 angle were 16.0° ± 8.0° and 19.9° ± 5.4° for males and females, respectively. Offset was 34.0 ± 5.3 mm and 33.4 ± 3.8 mm in males and females, respectively (Table 1). Intra-rater ICC and inter-rater ICC exceeded 0.81 in both methods, suggesting that the method of measurement was reliable (Tables 2 and 3).

In the regression analysis, the correlation coefficient for anteversion 1 and offset/length, and that for anteversion 2 and offset/length exceeded 0.81 for both males and females, showing a strong positive correlation (Figures 7-10).

## 6 | DISCUSSION

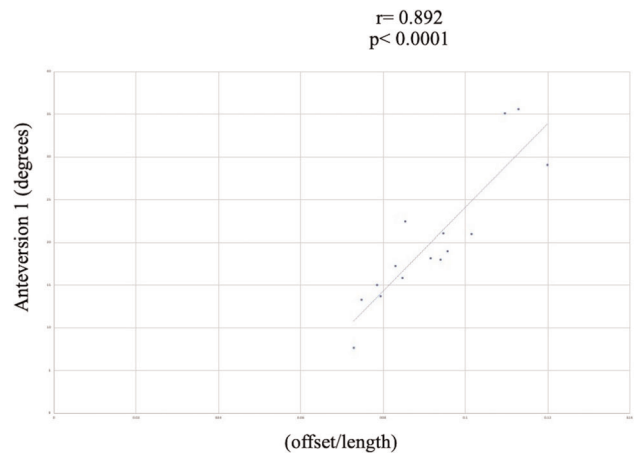
When we performed flexion and internal rotation femoral osteotomy, we experienced a case wherein the internal rotation angle of the hip improved more than that expected before surgery. We performed 30° flexion and 30° internal rotation osteotomy,

**TABLE 2** Intraclass correlation coefficient

	Anteversion 1	Anteversion 2	Offset
M	0.969	0.960	0.950
F	0.969	0.954	0.976

**TABLE 3** Interclass correlation coefficient

	Anteversion 1	Anteversion 2	Offset
M	0.962	0.840	0.944
F	0.969	0.954	0.948

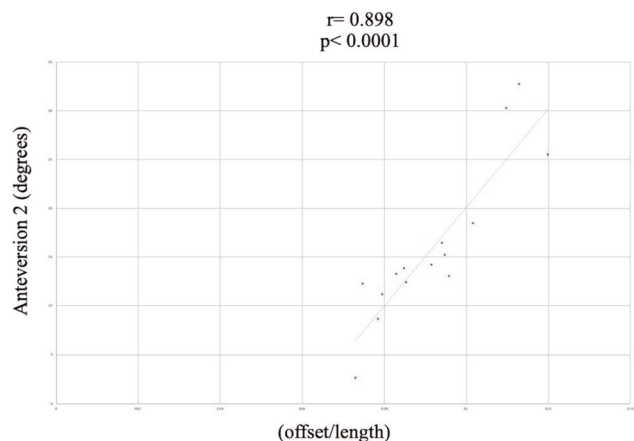


**FIGURE 7** Correlation between anteversion 1 and offset/length in men

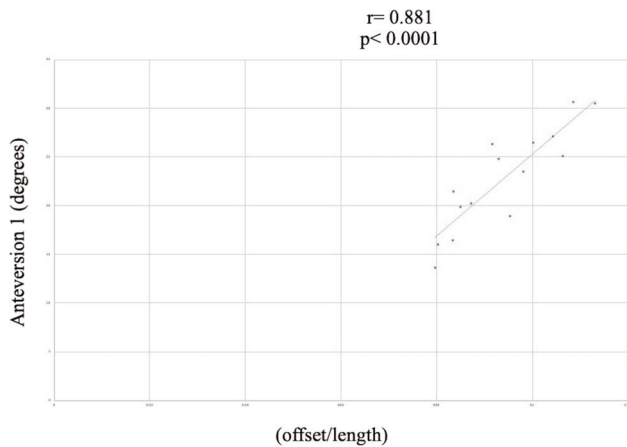
which resulted in 60° improvement in the patient's hip internal rotation.<sup>11</sup> When observed from a position close to the femur, flexion osteotomy and internal rotational osteotomy are similar from the viewpoint of the axial offset of the retrocondylar plane. Osteotomies of the femur include flexion/extension, internal/external rotation, and abduction/adduction osteotomies. But some of them are compatible or incompatible combinations. However, when we look at it from the retrocondylar plane, we can understand how compatible or incompatible combinations they are.

In a conventional method, femoral offset is measured using the front of a simple X-ray, and there is a relationship between femoral offset and range of abduction.<sup>12</sup> Here, we evaluated whether femoral axial offset measured from the retrocondylar plane can be measured accurately; we also analyzed the reproducibility of the measurement method.

There are many methods for measuring femoral anteversion using CT.<sup>1-6</sup> The reproducibility of the various measurement methods is reported to be high.<sup>6,7</sup> If there is a good measurement method, then this measurement method should gradually become the primary measurement method. The difficulty in measuring femoral



**FIGURE 8** Correlation between anteversion 2 and offset/length in men

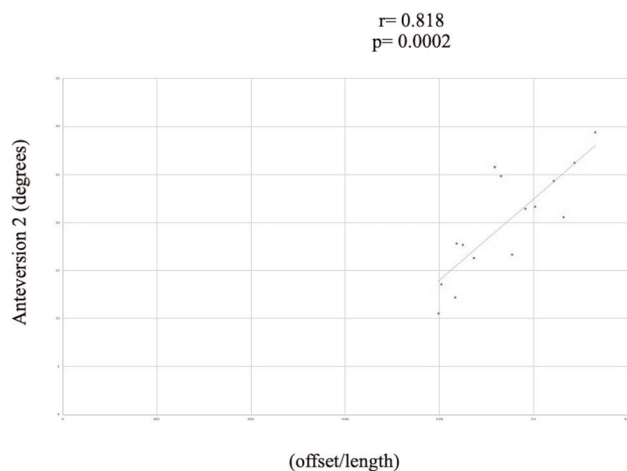


**FIGURE 9** Correlation between anteverision 1 and offset/length in women

anteverision is due to the segmental torsion of the femur.<sup>13</sup> Moreover, femoral torsion in 3D is being measured in 2D at one site. As there is no femoral head center in extension of the longitudinal axis of the neck of the femur,<sup>8</sup> it is difficult to define anteverision.

We observed accuracy and reproducibility of the femoral axial offset that we measured from the retrocondylar plane, indicating that the method was not inferior to the conventional methods for measuring femoral anteverision. Moreover, a high correlation between this method and the conventional methods for measuring femoral anteverision was observed; thus, we were successful in expressing the femoral anteverision angle as distance. We believe the usefulness of this method because it is easier than the conventional method, and the measurement results are more stable. A future study could analyze the association between the femoral axial offset measured from the retrocondylar plane and hip range of motion.

This time, we used bone specimens rather than data from clinical practice. Because in clinical practice, the patients' lower limb positions are not constant when taking CT. In bone



**FIGURE 10** Correlation between anteverision 2 and offset/length in women

specimens, the position of femurs can be kept constant when taking CT. Therefore, it is easy to set the retrocondylar plane in bone specimen. We thought that it is important to establish the method in bone specimen at first. Next, we would like to establish a method using data from clinical practice to obtain the mean offset in the normal population. Furthermore, we want to be able to reproduce before and after the osteotomy during the surgery.

One of the limitations of this study is that it is difficult to mark the center of the femoral head in hips with femoral head deformity, so the femoral axial offset might not reflect femoral anteverision by the shift of the center of the femoral head. Therefore, we should continue to study cases with femoral head deformity.

## 7 | CONCLUSION

The accuracy and repeatability of the method where the femoral axial offset is measured from the retrocondylar plane were high.

### AUTHOR CONTRIBUTIONS

*Data collection:* Yuusaku Isobe, Ko Chiba, Ritsu Tsujimoto, and Takeshi Imamura. *Interpretation:* Makoto Osaki. *Study concept:* Toshiyuki Tsurumoto.

### ORCID

Shohei Matsubayashi  <https://orcid.org/0000-0003-2929-4594>

### REFERENCES

- Tomczak R, Günther K, Pfeifer T, et al. The measurement of the femoral torsion angle in children by NMR tomography compared to CT and ultrasound. *Rofo*. 1995;162:224-228.
- Murphy SB, Simon SR, Kijewski PK, Wilkinson RH, Griscom NT. Femoral anteverision. *J Bone Joint Surg Am*. 1987;69:1169-1176.
- Yoshioka Y, Cooke TD. Femoral anteverision: assessment based on function axes. *J Orthop Res*. 1987;5:86-91.
- Hernandez RJ, Tachdjian MO, Poznanski AK, Dias LS. CT determination of femoral torsion. *AJR Am J Roentgenol*. 1981;137:97-101.
- Jarrett DY, Oliveria AM, Zou KH, Snyder BD, Kleinman PK. Axial oblique CT to assess femoral anteverision. *AJR Am J Roentgenol*. 2010;194:1230-1233.
- Byun HY, Shin H, Lee ES, Kong MS, Lee SH, Lee CH. The availability of radiological measurement of femoral anteverision angle: three-dimensional computed tomography reconstruction. *Ann Rehabil Med*. 2016;40:237-243.
- Kaiser P, Attal R, Kammerer M, et al. Significant differences in femoral torsion values depending on the CT measurement technique. *Arch Orthop Trauma Surg*. 2016;136:1259-1264.
- Kingsley PC, Olmsted KL. A study to determine the angle of anteverision of the neck of the femur. *J Bone Joint Surg Am*. 1948;30:745-751.
- Masaki T, Takahashi S, Hidetoshi H, Nobuhiko S. Pelvic and femoral coordinates and implant alignment representations in THA. In: Nobuhiko S, ed. *Computer Assisted Orthopaedic Surgery for Hip and Knee*. Singapore: Springer; 2018:75-88.
- Landis JR, Koch GC. The measurement of observer agreement for categorical data. *Biometrics*. 1977;33:159-174.
- Shohei M, Ko C, Ritsu T, Makoto O, Akifusa W. Femoral osteotomy to improve range of motion in residual deformity of Perthes disease: a case report. *Ann Med Surg*. 2020;55:5-8.

12. McGroarty BJ, Morrey BF, Cahalan TD, An KN, Cabanela ME. Effect of femoral offset on range of motion and abductor muscle strength after total hip arthroplasty. *J Bone Joint Surg Br.* 1995;77:865-869.
13. Ferlic PW, Runer A, Seeber C, Thöni M, Seitzinger G, Liebensteiner MC. Segmental torsion assessment is a reliable method for in-depth analysis of femoral alignment in Computer Tomography. *Int Orthop.* 2018;42:1227-1231.

**How to cite this article:** Matsubayashi S, Isobe Y, Chiba K, et al. Measurement of Femoral Axial Offset. *J Orthop Res.* 2021;39:1383-1389. <https://doi.org/10.1002/jor.24843>