

Reappraisal of the Cerebral Blood Flow Measured Using ¹²³I-I-iodoamphetamine Single-photon Emission Computed Tomography in Normal Subjects and Patients with Alzheimer's Disease and Dementia with Lewy Bodies

Makiko SETO¹, Naomi FUKUSHIMA¹, Takayuki YUASA¹, Yoko NAKAO¹, Katsuhiro ICHINOSE¹, Itsuro TOMITA¹, Hideyo SATOH¹, Akira SATOH¹, Makoto OCHI², Mitsuhiro TSUJIHATA¹

¹ Section of Neurology, Nagasaki Kita Hospital, 800 Motomuragou, Togitsuchou, Nishisonogigun, Nagasaki 851-2103, Japan

² Section of Radiology, Nagasaki Kita Hospital, 800 Motomuragou, Togitsuchou, Nishisonogigun, Nagasaki 851-2103, Japan

Purpose: Our aim was to re-evaluate the usefulness of perfusion single-photon emission computed tomography (SPECT) for the diagnosis of AD and DLB.

Methods: A total of 1,232 patients, including 180 cognitively normal subjects (NSs), 148 patients with amnesic mild cognitive impairment (aMCI), 802 patients with AD and 102 patients with dementia with Lewy bodies (DLB) were enrolled. A voxel-based stereotactic extraction estimation analysis was used to assess hypoperfusion areas using the cut-off value of 20% for the "extent %" and >2 hypoperfused lesions.

Results: The top 10 areas with hypoperfusion in AD were the angular gyrus, supramarginal gyrus, precuneus, superior occipital gyrus, inferior parietal lobule, middle temporal gyrus, superior parietal lobule, inferior temporal gyrus, superior temporal gyrus, and posterior cingulate, while DLB had 6 areas in common with AD. The respective sensitivity and specificity for differentiating AD from NSs were 84.2% and 78.9% for 50-59 years old, and 91.8% and 70.0% for 60-69 years old, but those values decreased from 70 years old. The respective sensitivity and specificity in DLB patients were 100% and 75.6% for 50-69 years old, 84.6% and 70.1% for 70-79 years old and 81.4% and 77.1% for 80-89 years old. In aMCI patients, the 1-year change in the MMSE scores was -2.38 ± 2.02 (n=16) in patients with abnormal SPECT images and -0.67 ± 1.81 (n=18) in those with normal SPECT images (P<0.02).

Conclusions: Our study confirms that perfusion SPECT is still a valid alternative for the diagnosis of AD and DLB when fluorodeoxyglucose-PET is unavailable.

ACTA MEDICA NAGASAKIENSIA 64: 91–100, 2021

Key words: IMP-SPECT, Alzheimer's disease, Dementia with Lewy bodies, amnesic mild cognitive impairment, preferred hypoperfusion areas, ¹⁸F-FDG PET

Introduction

Alzheimer's disease (AD) is the most common form of dementia in the elderly and it is characterized by progressive impairment in multiple cognitive domains of sufficient severity to interfere with individuals' daily living activities. Four articles in the *Journal of Alzheimer's & Dementia* in 2011¹⁻⁴ described new criteria for AD dementia and mild cognitive

impairment (MCI) due to the AD pathophysiological process (MCI due to AD) as well as their underlying rationale. These new criteria emphasize that the AD pathophysiological process starts years and perhaps decades prior to clinical symptoms, and that biomarkers can be used to detect amyloid beta (A β) deposition and the effects of neurodegeneration in the brain. These biomarkers include *in vivo* findings of brain imaging with positron emission tomography (PET) and

Address correspondence: Mitsuhiro Tsujihata, MD.

Nagasaki Kita Hospital, 800 Motomuragou, Togitsuchou, Nishisonogigun, Nagasaki 851-2103, Japan

Tel: +81-95-886-8700, Fax: +81-95-886-8701, E-mail: kita_m_tsuji@mx22.tiki.ne.jp

Received October 7, 2020; Accepted November 10, 2020

magnetic resonance imaging (MRI), imaging of amyloid plaques and biochemical assays of $A\beta$ 1-42, $A\beta$ 1-40, total tau and phosphorylated tau (p-tau) in the cerebrospinal fluid (CSF). However, these markers are not available at general hospitals.

In the present study, we investigated the effect of aging on the cerebral blood flow (CBF) measured using N-isopropyl-p-[(123I)]iodoamphetamine (^{123}I -IMP) single-photon emission computed tomography (SPECT) in cognitively normal subjects (NSs) and patients with AD or DLB and determined the preferred areas of hypoperfusion in these diseases. Finally, we discussed the utility of SPECT for the diagnosis of AD, aMCI and DLB.

Methods and Materials

Methods

The SPECT device used in this study was an Infinia Hawkeye 4, General Electronic Company, U.S.A, which had a rotating two-headed gamma camera with a fan beam collimator (64x64). The regional cerebral blood flow (rCBF) changes were acquired for 20 minutes, starting 30 minutes after the administration of 111 MBq of ^{123}I -IMP.

The easy Z-score Imaging System (eZIS)⁵⁾, and Voxel-based Stereotactic Extraction Estimation (vbSEE)⁶⁾ were used in this study for the quantitative assessment of brain SPECT images. We used the parameter “extent %” with the vbSEE software program, the extent of an abnormal region in each segment (proportion of the coordinates with a Z-value that exceeds the threshold value, among all coordinates within a segment).

We examined 2 indicators of decreased levels (20% and 30% decrease) of the “extent %” in the level 3 of vbSEE software program to decide which “extent %” is appropriate for assessing hypoperfusion for a comparison between NSs and diseased patients.

Materials

We established a “forgetfulness outpatient clinic” in our hospital on May 1, 2000. Thereafter, the hospital was reconstructed, and the medical care was restarted on October 1, 2007, at which point the SPECT device was changed to an Infinia Hawkeye 4, General Electronic Company, USA. For this reason, we recruited subjects based on their medical records starting from October 1, 2007, until December 31, 2017. The number of patients who underwent the mini-mental examination test (MMSE) during this period was 8,566, among whom 4,850

were new patients. We conducted SPECT examination in 2,412 of the new patients.

A total of 1,232 patients were ultimately enrolled in this study, including 180 NSs, 148 patients with aMCI, 802 patients with AD, and 102 patients with DLB.

NSs and AD patients were divided into 4 groups according to age (50-59, 60-69, 70-79 and 80-89 years old), while aMCI and DLB patients were divided into 3 groups according to age (50-69, 70-79, and 80-89 years old) because of small number of patients who were 50-59 years old.

The clinical diagnosis of probable AD was made according to the National Institute of Neurological and Communicative Disorders and Stroke-Alzheimer’s Disease and Related Disorders Association (NINCDS-ADRDA) criteria⁷⁾. aMCI was diagnosed according to the criteria of Petersen et al.⁸⁾. Probable DLB was diagnosed according to the criteria of McKeith et al.^{9,10)}.

The following subjects were excluded from the study: patients with AD who had MMSE scores of <14/30 and were associated with widespread leucoaraiosis, cerebral infarction, cerebral hemorrhaging and subarachnoid hemorrhaging; patients with non-amnesic MCI; patients with DLB who had MMSE scores of <14/30 and were associated with cerebral vascular diseases; patients with neurodegenerative diseases, such as multiple system atrophy, progressive supranuclear palsy and corticobasal syndrome; and patients with normal pressure hydrocephalus, severe diabetes mellitus and heart diseases.

Statistical analyses

We used the IBM-SPSS v.24, (U.S.A) and StatMate v.5. (Atms, Tokyo, Japan) software programs for the data analyses. Descriptive data are reported as mean and Standard Deviation (SD) or as number and percentage. Differences between each disease were assessed with a one way ANOVA, followed by the Tukey’s test for pairwise comparison when ANOVA showed a significant difference.

To estimate the predicative ability, the sensitivity and specificity of the different items were calculated.

Results

Subjects enrolled in this study

The demographic data of NSs patients with AD, aMCI and DLB are listed in Table 1. As shown in these tables, most patients in our “forgetfulness outpatient clinic” were over 70 years old.

Table 1. Demographic data of enrolled subjects

	Age	Number of subjects	Sex M/F	MMSE scores mean \pm SD
NS	50-59	38	7/31	29.6 \pm 0.7
	60-69	40	11/29	29.3 \pm 0.7
	50-69*	78	18/60	29.4 \pm 0.7
	70-79	67	25/42	28.9 \pm 1.0
	80-89	35	17/18	28.7 \pm 1.0
	Total	180	60/120	
AD	50-59	19	9/10	21.8 \pm 3.0
	60-69	73	22/51	22.3 \pm 3.4
	70-79	317	106/211	22.0 \pm 3.5
	80-89	393	105/288	21.8 \pm 3.5
	Total	802	242/560	
aMCI	50-69	18	6/12	27.6 \pm 1.2
	70-79	77	28/49	27.5 \pm 1.2
	80-89	53	20/33	27.3 \pm 1.2
	Total	148	54/94	
DLB	50-69	7	3/4	23.2 \pm 5.7
	70-79	52	30/22	24.1 \pm 3.2
	80-89	43	18/25	23.3 \pm 3.9
	Total	102	50/52	

* For comparison with aMCI and DLB patients

Determination of the preferred areas of hypoperfusion in AD patients

We determined the preferred areas of hypoperfusion by analyzing the “extent %” in AD patients 50-69 years old, and selected the top 10 areas expressing the average “extent %” value (Table 2) presented in descending order: the angular gyrus, supramarginal gyrus, precuneus, superior occipital gyrus, inferior parietal lobule, middle temporal gyrus, superior parietal lobule, inferior temporal gyrus, superior temporal gyrus and posterior cingulate.

Table 2. Frequent areas of hypoperfusion in AD patients (age 50-69)

Brain areas	Average Extent %
Angular Gyrus	48.41
Supramarginal Gyrus	38.57
Precuneus	30.60
Superior Occipital Gyrus	29.21
Inferior Parietal Lobule	27.50
Middle Temporal Gyrus	26.95
Superior Parietal Lobule	24.88
Inferior Temporal Gyrus	21.94
Superior Temporal Gyrus	19.97
Posterior Cingulate	19.43

Determination of the cut-off value in NSs and the sensitivity, specificity and efficacy in AD patients

We determined the preferred areas of hypoperfusion in NSs corresponding to the preferred areas obtained in AD patients according to the ages in order to determine whether an “extent %” of 20% or 30% or 1 or >2 lesions of hypoperfusion was most suitable as the cut-off value (Table 3, 4). The number of AD patients showing hypoperfusion and the sensitivity, specificity and efficacy at each cut-off value compared with the age- and area-matched NSs were shown in Table 3. The sensitivity was lower while the specificity was higher with an “extent %” of 30% than with 20% and >2 areas of hypoperfusion than with 1 for differentiating AD from NSs (Table 3). We therefore ultimately adopted an “extent %” of 20% and 2> hypoperfusion areas as the cut-off value in this quantitative analysis of SPECT images, as the respective sensitivity and specificity for differentiating AD patients from NSs were 84.2% and 78.9% for 50-59 years old, 91.8% and 70.0% for 60-69 years old, 76.0% and 75.6% for 70-79 years old and 53.2% and 71.4% for 80-89 years old. These results indicate that the sensitivity decreases with aging.

The frequency of hypoperfusion areas in NSs using these cut-off values was 21.1% for 50-59 years old, 32.5% for 60-69

Table 3. Number of cases showing hypoperfusion areas in AD patients & sensitivity, specificity & efficacy in each cut-off value compared with age- and area-matched normal subjects

Ages	No of cases	Cut-off value 20%	No of cases	Sensitivity	Specificity	Cut-off value 30%	No of cases	Sensitivity	Specificity
50-59	19	over 1area	19	100.0%	65.8%	over 1area	18	94.7%	81.6%
		over 2area	16	84.2%	78.9%	over 2area	15	78.9%	94.6%
60-69	73	over 1area	70	95.9%	50.0%	over 1area	65	89.0%	70.0%
		over 2area	67	91.8%	70.0%	over 2area	62	84.9%	87.5%
70-79	317	over 1area	271	85.5%	59.0%	over 1area	234	73.1%	61.2%
		over 2area	241	76.0%	75.6%	over 2area	198	62.5%	85.1%
80-89	393	over 1area	266	67.7%	60.0%	over 1area	208	52.9%	68.6%
		over 2area	209	53.2%	71.4%	over 2area	139	35.4%	85.7%

Table 4. Number of cases showing hypoperfusion areas in normal subjects age- and areas-matched to AD

Ages	No of subjects	Cut-off 20%	No of subjects	Cut-off 30%	No of subjects
50-59	38	over 1area	13	over 1area	7
		over 2area	8	over 2area	2
60-69	40	over 1area	19	over 1area	12
		over 2area	13	over 2area	5
50-69	78	over 1area	32	over 1area	18
		over 2area	21	over 2area	6
70-79	67	over 1area	32	over 1area	26
		over 2area	21	over 2area	10
80-89	35	over 1area	14	over 1area	11
		over 2area	10	over 2area	5

years old, 31.3% for 70-79 years old and 28.6% for 80-89 years old, showing no significant difference among age groups.

Determination of the preferred areas of hypoperfusion in DLB patients

We determined the preferred areas of hypoperfusion by analyzing the "extent %" in 102 patients with probable DLB and selected the 10 main areas expressing the average "extent %" value (Table 5), presented in descending order: the angular gyrus, superior occipital gyrus, inferior occipital gyrus, middle occipital gyrus, supramarginal gyrus, cuneus, middle temporal gyrus, inferior temporal gyrus, precuneus, and lingual gyrus. The respective sensitivity and specificity in DLB patients compared with age- and hypoperfusion area-matched NSs were 100% and 75.6% for 50-69 years old, 84.6% and 70.1% for 70-79 years old and 81.4% and 77.1% for 80-89 years old (Table 6). The cut-off value obtained in the AD patients was used to calculate the sensitivity and specificity in DLB patients.

In contrast to our findings in AD patients, the sensitivity in DLB patients did not decrease with age.

The sensitivity and specificity in aMCI patients

The respective sensitivity and specificity in aMCI patients compared with age- and hypoperfusion area-matched NSs were 88.9% and 75.6% for 50-69 years old, 57.1% and 68.7% for 70-79 years old and 30.2% and 71.4% for 80-89 years old (Table 6). The sensitivity in aMCI patients was

Table 5. Preferred areas of hypoperfusion in DLB patients

Brain areas	Average extent %
Angular Gyrus	40.44
Superior Occipital Gyrus	35.75
Inferior Occipital Gyrus	27.43
Middle Occipital Gyrus	27.26
Supramarginal Gyrus	24.26
Cuneus	23.98
Middle Temporal Gyrus	23.87
Inferior Temporal Gyrus	22.06
Precuneus	20.34
Lingual Gyrus	20.09

Table 6. Sensitivity and specificity in aMCI, AD, and DLB patients compared with age- and hypoperfusion area-matched normal subjects

Disease	Age	No of cases	sensitivity	specificity
MCI	50-69	18	88.9%	75.6%
	70-79	77	57.1%	68.7%
	80-89	53	30.2%	71.4%
AD	50-59	19	84.2%	78.9%
	60-69	73	91.8%	70.0%
	70-79	317	76.0%	75.6%
	80-89	393	53.2%	71.4%
DLB	50-69	7	100%	75.6%
	70-79	52	84.6%	70.1%
	80-89	43	81.4%	77.1%

considerably lower than in AD patients > 70 years old.

The comparison of the preferred areas of hypoperfusion in AD and DLB patients

The top 10 areas of hypoperfusion in AD and DLB were shown based on the degree of hypoperfusion (Figure 1). Although there was a difference in the degree of hypoperfusion, 6 of the top 10 areas with hypoperfusion showed a common

decrease in AD and DLB patients. Hypoperfusion in the superior and inferior parietal lobules, precuneus and posterior cingulate suggests a greater likelihood of AD, while that in the middle and inferior occipital gyri, cuneus, and lingual gyrus suggests a greater likelihood of DLB.

We counted the total number of hypoperfusion areas (maximum number is 20) observed in the top 10 areas of hypoperfusion with an “extent %” over 20%, regardless of the “extent %” in AD and DLB patients (Fig. 2 and 3).

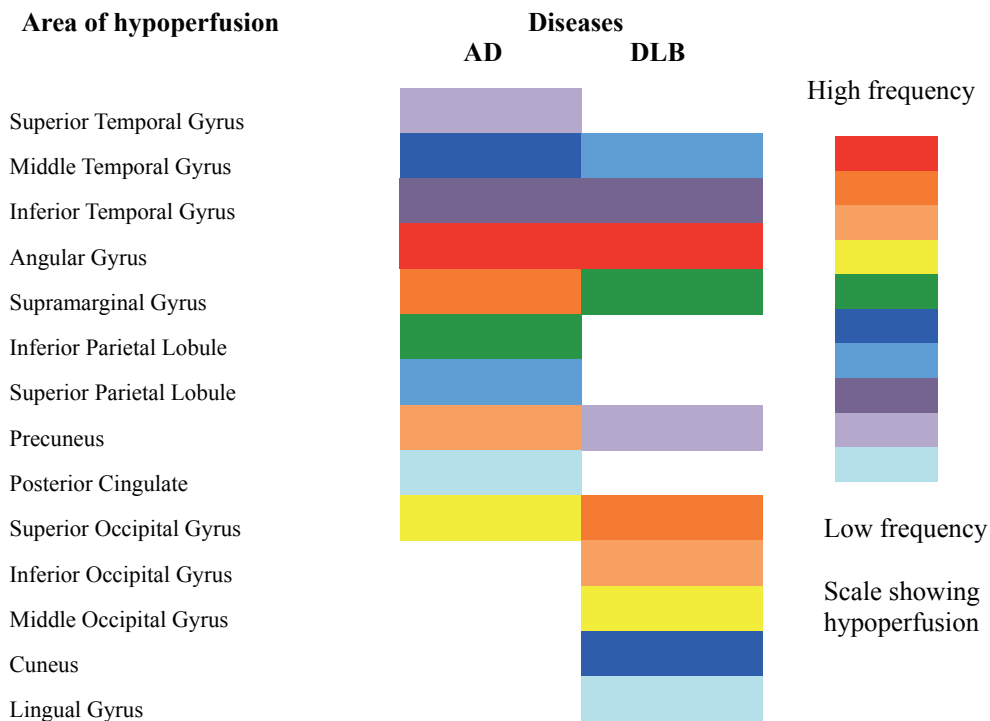


Figure 1. The top 10 areas of hypoperfusion in AD patients and DLB patients. Six of the top 10 hypoperfusion areas showed a common decrease in AD and DLB patients. Hypoperfusion in the superior and inferior parietal lobules, precuneus, and posterior cingulate suggests a greater likelihood of AD, while that in the middle and inferior occipital gyri, cuneus and lingual gyrus suggests a greater likelihood of DLB.

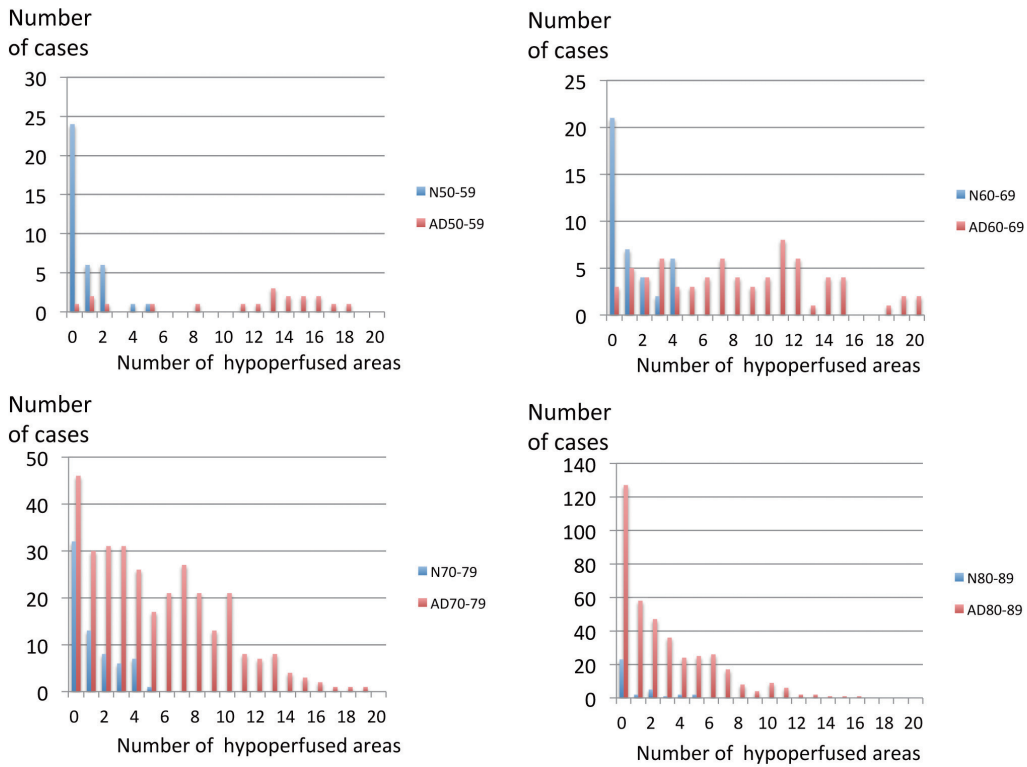


Fig. 2

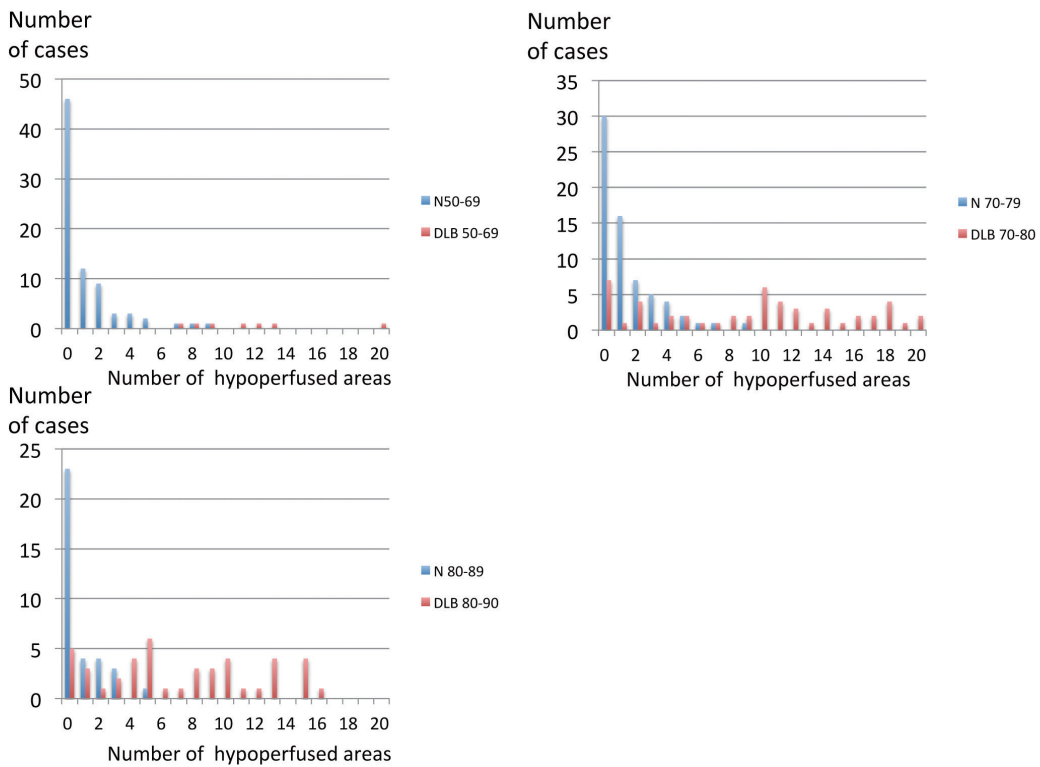


Fig. 3

Figure 2. and 3. The distribution of the total number of hypoperfusion areas in AD (Fig.2) and DLB (Fig.3). AD showed a decrease in the high frequency total number of hypoperfusion in older groups, While no such findings were observed in DLB. N:Normal subjects, AD: Alzheimer’s disease, DLB: dementia with Lewy bodies

The distribution of these number in AD patients showed a decrease of high frequency number of hypoperfusion in older age groups, while such findings were not observed in DLB patients.

Effects of hypoperfusion of SPECT images on progression of aMCI and AD

In aMCI patients, while the number of cases was small, the 1-year change in the MMSE was -2.38 ± 2.02 (n=16) in

patients with abnormal SPECT images, and -0.67 ± 1.81 (n=18) in those with normal SPECT images ($P < 0.02$, Mann-Whitney test). Eight of 16 patients with abnormal SPECT images eventually developed AD, while 2 of 18 with normal SPECT images eventually developed AD. Although only a small number of cases could be followed, the MMSE scores decreased over time in all AD patients regardless of the normality of their SPECT findings, but the progression in those with normal findings was one year slower than in those with abnormal findings (Fig. 4).

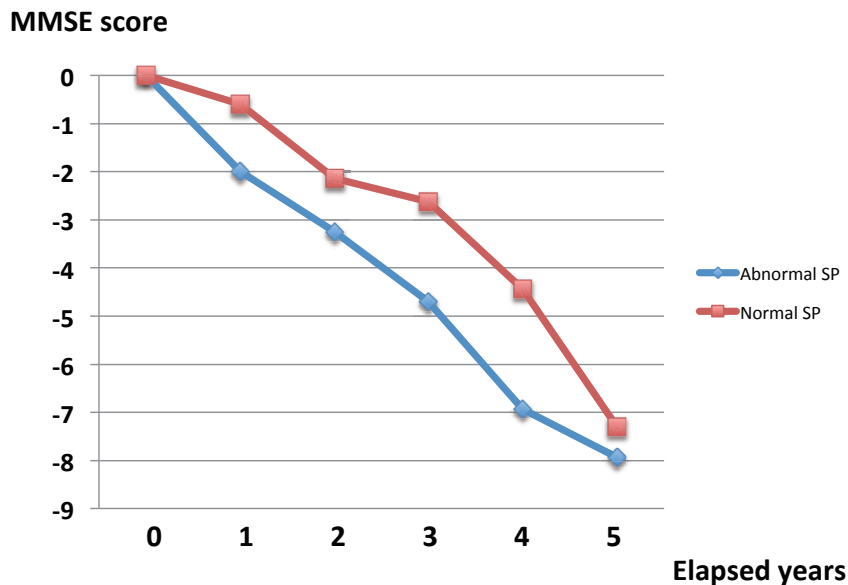


Figure 4. Effects of hypoperfusion of SPECT images on progression of AD. The MMSE scores decreased with the passage of time in both AD patients with abnormal SPECT findings as well as in those with normal SPECT findings, although the progression in the latter was about one year slower than that in the former. SP: SPECT

Discussion

Recently, there have been developments in brain imaging techniques for detecting the core histological features of Alzheimer disease, i.e. amyloid plaques and neurofibrillary tangles. However, the utility of these techniques is still being investigated.

Functional imaging methods, such as ^{18}F -fluorodeoxyglucose [^{18}F -FDG]- PET and perfusion (hexamethylpropyleneamine oxime [HMPAO]) SPECT are advocated as useful for clarifying the diagnosis of dementia when doubt remains. Although specific imaging ligands for amyloid are becoming available, the mainstay of functional brain imaging for the differential diagnosis of dementia will remain ^{18}F -FDG-PET and blood flow SPECT even in general hospitals.

Aging effects of hypoperfusion in NSs

When analyzing the rCBF in patients with neurodegenerative diseases, we need to pay attention to age-related changes in the rCBF. There have been many reports describing the age-related changes in the rCBF in normal subjects, although the main sites of a reduced rCBF have differed among studies. Indeed, several reports described the anterior cingulate as the main site within which the rCBF is reduced with normal aging¹¹⁻¹⁵, while others failed to demonstrate any marked reduction in the rCBF in this area^{16, 17}. Mozley et.al reported that the reduction in the rCBF was negligible in subjects >40 years of age¹⁸. These discrepancies may be attributable to differences in the criteria used to select subjects and the diversity of the image analysis methods.

In the present study, we first determined the preferred

areas of hypoperfusion in AD and DLB patients. Although the degree of hypoperfusion differed, 6 of the 10 main areas of hypoperfusion showed a common decrease in AD and DLB patients. Hypoperfusion in the superior and inferior parietal lobules, precuneus and posterior cingulate suggests a greater likelihood of AD, while that in the middle and inferior occipital gyri, cuneus and lingual gyrus suggests a greater likelihood of DLB.

Based on these results, the frequency of hypoperfusion in NSs corresponding to the preferred areas of hypoperfusion for AD and DLB was investigated. Our findings indicated no marked difference in the degree of hypoperfusion with age in NSs.

Sensitivity and specificity of SPECT imaging for diagnosing dementia

Studies of the accuracy of SPECT for diagnosing AD reported sensitivities of 65%-85% and specificities of 72%-87%¹⁹). Studies for ¹⁸F-FDG PET generally reported higher accuracy, with sensitivities of 75%-99% and specificities of 71%-93% for AD²⁰). O'Brien et al.²¹) reported that when performing a visual rating, the key imaging features were a reduced uptake in the precuneus and lateral parietal lobes in both AD and DLB, the relative preservation of the posterior cingulate in DLB, and a more extensive occipital loss in DLB, with a reduced uptake in the temporal and frontal lobe being more likely in AD than DLB. The consensus diagnosis with ¹⁸F-FDG PET was superior to that with SPECT for both dementia vs. no-dementia and AD vs. DLB comparisons. The sensitivity and specificity for dementia/no-dementia was 85% and 90%, respectively, for ¹⁸F-FDG PET and 71% and 70%, respectively, for SPECT. The authors recommended that ¹⁸F-FDG PET should be performed instead of perfusion SPECT for the differential diagnosis of degenerative dementia if functional imaging was indicated. There have been no reports on the age-related incidence of hypoperfusion on SPECT images in AD patients.

In the present study, the respective sensitivity and specificity for differentiating AD from NSs were 84.2% and 78.9% for 50-59 years old, 91.8% and 70.0% for 60-69 years old, 76.0% and 75.6% for 70-79 years old and 53.2% and 71.4% for 80-89 years old. These results indicate that sensitivity decreases with aging. The results in aMCI were the same as those in AD; however, in DLB patients, no marked decrease in the sensitivity with aging was observed. While this degree of diagnostic accuracy might still be clinically helpful when comparing dementia and no-dementia patients, the accuracy for differentiating AD from DLB was disappointingly poor¹³).

Our finding that 6 of the 10 main areas of hypoperfusion showed a common decrease in AD and DLB patients indicates that clear discrimination between AD and DLB is difficult.

To this end, cardiac MIBG scintigraphy is much more useful than SPECT²²).

The present study showed that for differentiating AD patients from NSs, SPECT findings were very useful, particularly, among patients <69 years old. Why the sensitivity in aged AD patients, particularly those over 80 years old, was decreased is not clear. The mechanism involving a decrease of rCBF in aged person described in the previous reports is not considered to be aging effects.

Argyrophilic grain disease (AGD) is said to be the second-most common neurodegenerative disease that causes dementia in the elderly after AD²³⁻²⁵). Neuropathologic changes due to AGD may be found in isolation or in association with other neurodegenerative disorders, such as AD, Pick's disease, progressive supranuclear palsy (PSP), corticobasal degeneration (CBD), Parkinson's disease, TDP-43 proteinopathies, DLB and multiple system atrophy. Braak et al. reported that patients 81-85 years old had the highest frequency of AGD (40/125 cases), whereas only 5 patients <60 years old were found to have argyrophilic grains on a post-mortem examination²⁴). To date, no study has been able to demonstrate a distinct clinical syndrome associated with AGD. The diagnosis is exclusively based on postmortem findings and no reports on SPECT findings have been published.

Senile dementia of the neurofibrillary tangle (SD-NFT) type is a subset of dementia that primarily occurs in the oldest old patients^{26,27}). Although SD-NFT is not considered very rare in senile dementia patients, most SD-NFT cases are probably clinically misdiagnosed as AD in the absence of a post-mortem pathological investigation.

These two diseases are clinically impossible to definitely diagnose. We were therefore unable to exclude the possibility that these diseases were present in the aged group of AD patients in our study, which might have reduced the sensitivity in that population.

Preferred areas of hypoperfusion among disease

The pattern of SPECT hypoperfusion and PET hypometabolism usually seen AD patients involves the anterior medial temporal lobes, the posterior cingulate and posterior temporoparietal cortex²⁸⁻³⁰). Some neuroimaging features of DLB have been proposed to enhance the diagnostic accuracy. Indeed, occipital hypometabolism on ¹⁸F-FDG-PET images is a useful biomarker for differentiating DLB from AD^{31,32}).

In the present study, we determined the top 10 preferred

areas of hypoperfusion using the vbSEE software program. Despite a marked difference in the hypoperfusion degree, 6 of the top 10 hypoperfusion areas showed a common decrease in AD and DLB patients. Hypoperfusion in the superior and inferior parietal lobules, precuneus and posterior cingulate suggests a greater likelihood of AD, while that in the middle and inferior occipital gyri, cuneus and lingual gyrus suggests a greater likelihood of DLB.

The pathological hallmarks of DLB are the presence of Lewy bodies and Lewy neurites, but many cases also display an AD pathology postmortem^{33,34}. However, the importance of concurrent AD pathology in DLB, at what point during the disease it occurs and its relationships to the clinical presentations are unclear³⁵. Considering the previous reports that AD pathology occurs in many cases of DLB, it seems natural for the areas of hypoperfusion to overlap between AD and DLB cases. The cingulate island sign (CIS) on FDG-PET and brain perfusion SPECT was recently proposed as a neuroimaging feature of DLB. This term references the sparing of the posterior cingulate cortex relative to the precuneus plus cuneus and this sign is extremely specific for an accurate diagnosis of DLB^{36,37}. The CIS is influenced by concomitant AD-type neurofibrillary tangle (NFT) pathology and gradually disappears as DLB progresses³⁸. In the present study, the decreased perfusion in the posterior cingulate in DLB was ranked 16th indicating that posterior cingulate hypoperfusion is not an important finding in the diagnosis of DLB.

Prediction of conversion from aMCI to AD

The concept of MCI is now widely accepted and continues to receive substantial attention in the literature, as it represents a possible treatment target for AD. Its predictive power is reflected in annual conversion rates of up to 15% from MCI to AD, compared to conversion rates of 1%-2% from normal aging to AD^{39,8}. SPECT has been reported to be valuable for predicting the progression from MCI to AD-dementia⁴⁰⁻⁴³. However, differences in the methods of analyzing SPECT images among groups have hindered the comparison of our results with those of previous reports. Our study clearly showed that 50% of aMCI patients with abnormal SPECT findings showed rapid regression of the cognitive function compared to those with normal findings. Identifying such at-risk patients at an early time point would enable early intervention and a timely start of treatment, possibly preventing disease progression altogether.

Conclusion

A quantitative SPECT image analysis showed sensitivity and specificity equivalent to those of FDG-PET in AD patients 50-69 years old, suggesting its utility for making an AD diagnosis. A quantitative SPECT image analysis was also shown to be a useful auxiliary diagnostic technique for diagnosing DLB.

Six of the top 10 preferred areas of hypoperfusion were shared between AD and DLB. Hypoperfusion in the superior and inferior parietal lobules, precuneus and posterior cingulate suggests a greater likelihood of AD, while that in the middle and inferior occipital gyri, cuneus and lingual gyrus suggests a greater likelihood of DLB. Although FDG-PET performs better than perfusion SPECT, our study confirms the utility of perfusion SPECT as a valid alternative when FDG-PET is unavailable.

References

- 1) Jack CR Jr, Albert M, Knopman D, et al. Introduction to the recommendations from the National Institute on Aging-Alzheimer's Association workgroups on diagnostic guidelines for Alzheimer's disease. *Alzheimers Dement* 7:257-62, 2011.
- 2) Sperling RA, Aisen PS, Beckett LA, et al. Toward defining the preclinical stages of Alzheimer's disease: recommendations from the National Institute on Aging-Alzheimer's Association workgroups on diagnostic guidelines for Alzheimer's disease. *Alzheimers Dement* 7:280-92, 2011.
- 3) Albert M, DeKosky ST, Dickson D, et al. The diagnosis of mild cognitive impairment due to Alzheimer's disease: report of the National Institute on Aging and the Alzheimer's Association workgroup. *Alzheimers Dement* 7:270-9, 2011.
- 4) McKhann GM, Knopman DS, Chertkow H, et al. The diagnosis of dementia due to Alzheimer's disease: recommendations from the National Institute on Aging and the Alzheimer's Association workgroup. *Alzheimers Dement* 7:263-9, 2011.
- 5) Matsuda H. "Role of neuroimaging in Alzheimer's disease, with emphasis on brain perfusion SPECT," *J Nucl Med* 48:1289-1300, 2007.
- 6) Mizumura S, Kumita S, Cho K, et al. "Development of quantitative analysis method for stereotactic brain image: assessment of reduced accumulation in extent and severity using anatomical segmentation", *Ann Nucl Med* 17:289-295, 2003.
- 7) McKhann G, Drachman D, Folstein M, Katzman R, Price D, Stadlan EM. Clinical diagnosis of Alzheimer's disease: report of the NINCDS-ADRDA Work Group under the auspices of Department of Health and Human Services Task Force on Alzheimer's Disease. *Neurology* 34:939-44, 1984.
- 8) Petersen RC, Smith GE, Waring SC, Ivnik RJ, Tangalos EG, Kokman E. Mild Cognitive Impairment; Clinical characterization and outcome. *Arch Neurol* 56 303-308, 1999.
- 9) McKeith IG, Dickson DW, Lowe J, et al. Diagnosis and management of dementia with Lewy bodies: third report of the DLB Consortium. *Neurology* 65:1863-72, 2005.
- 10) McKeith IG, Boeve BF, Dickson DW, et al. Diagnosis and management of dementia with Lewy bodies: Fourth consensus report of the DLB Consortium. *Neurology* 89:88-100, 2017.
- 11) Takahashi K, Yamaguchi S, Kobayashi S, Yamamoto Y. Effects of Aging on Regional Cerebral Blood Flow Assessed By Using Technetium Tc

- 99mHexamethylpropyleneamine Oxime Single-Photon Emission Tomography with 3D Stereotactic Surface Projection Analysis. *AJNR* 26:2005-2009, 2005.
- 12) Nakano S, Asada T, Matsuda H, Uno M, Takasaki M. Effects of healthy aging on the regional cerebral blood flow measurements using Tc-ECD SPECT assessed with statistical parametric mapping. *Nippon Ronen Igakkai Zasshi* 37:49-55, 2000.
 - 13) Van Laere K, Versijpt J, Audenaert K, et al. Tc-ECD brain perfusion SPET: variability, asymmetry and effects of age and gender in healthy adults. *Eur J Nucl Med* 28:873-887, 2001.
 - 14) Tanaka F, Vines D, Tsuchida T, Freedman M, Ichise M. Normal patterns on Tc-ECD brain SPECT scans in adults. *J Nucl Med* 41:1456-1464, 2000.
 - 15) Martin AJ, Friston KJ, Colebatch JG, Frackowiak RSJ. Decreases in regional cerebral blood flow with normal aging. *J Cereb Blood Flow Metab* 11:684-689, 1991.
 - 16) Pagani M, Salmaso D, Jonsson C, et al. Regional cerebral blood flow as assessed by principal component analysis and Tc-HMPAO SPET in healthy subjects at rest: normal distribution and effect of age and gender. *Eur J Nucl Med* 29:67-75, 2002.
 - 17) Krausz Y, Bonne O, Gorfine M, Karger H, Lerer B, Chisin R. Age-related changes in brain perfusion of normal subjects detected by Tc-HMPAO SPECT. *Neuroradiology* 40:428-434, 1998.
 - 18) Mozley PD, Sadek AM, Alavi A, et al. Effects of aging on the cerebral distribution of technetium-99m hexamethylpropylene amine oxime in healthy humans. *Eur J Nucl Med* 24:754-761, 1997.
 - 19) Dougall NJ, Bruggink S, Ebmeier K. Systematic review of the diagnostic accuracy of 99mTc-HMPAO-SPECT in dementia. *Am J Geriatr Psychiatry* 12:554-570, 2004.
 - 20) Silverman DH, Small GW, Chang CY, et al. Positron emission tomography in evaluation of dementia: regional brain metabolism and long-term outcome. *JAMA* 286:2120-2127, 2001.
 - 21) O'Brien JT, Firbank MJ, Davison C, et al. ¹⁸F-FDG PET and Perfusion SPECT in the Diagnosis of Alzheimer and Lewy Body Dementias. *J Nucl Med* 55:12 1959-1965, 2014.
 - 22) Seto M, Nakata R, Yuasa T, et al. Diagnostic value of 123-I-MIBG cardiac scintigraphy for the prediction of conversion from idiopathic REM sleep behavior disorder to dementia with Lewy bodies, and the differential diagnosis of neurodegenerative diseases. *Alzheimers Dis Dement* 1:47-55, 2017. [ISSN2578-6490]
 - 23) Sumit D, Abdullah I. Review paper. Argyrophilic grain disease: a clinicopathological review of an overlooked tauopathy. *Folia Neuropathol* 56:277-283, 2018.
 - 24) Braak H, Braak E. Argyrophilic grain disease: frequency of occurrence in different age categories and neuropathological diagnostic criteria. *J Neural Transm* 105:801-819, 1998.
 - 25) Saito Y, Nakahara K, Yamanouchi H, Murayama S. Severe involvement of ambient gyrus in dementia with grains. *J Neuropathol Exp Neurol* 61:9:789-796, 2002.
 - 26) Yamada M, Itoh Y, Otomo E, Suematsu N, Matsushita M. Dementia of the Alzheimer type and related dementias in the aged: DAT subgroups and senile dementia of the neurofibrillary tangle type. *Neuropathol* 16:89-98, 1996.
 - 27) Jellinger KA, Attems J. Neurofibrillary tangle-predominant dementia: comparison with classical Alzheimer disease. *Acta Neuropathol* 113:107-117, 2007.
 - 28) Kogure D, Matsuda H, Ohnishi T, Kumihiro T, Uno M, Takasaki M. Longitudinal evaluation of early Alzheimer disease using brain perfusion SPECT. *J Nucl Med* 41, 1155-1162, 2000.
 - 29) Bradley KM, O'Sullivan VT, Soper ND, et al. Cerebral perfusion SPET correlated with Braak pathological stage in Alzheimer's disease. *Brain* 125, 1772-1781, 2002.
 - 30) Femminella GD, Thayanandan T, Calsolaro V, et al. Imaging and Molecular Mechanisms of Alzheimer's Disease: A Review. *Int J Mol Sci online* 9:3702, 2018.
 - 31) Ishii K, Imamura T, Sasaki M, et al. Regional cerebral glucose metabolism in dementia with Lewy bodies and Alzheimer's disease. *Neurology* 51:125-30, 1998.
 - 32) Minoshima S, Foster NL, Sima AA, et al. Alzheimer's disease versus dementia with Lewy bodies: cerebral metabolic distinction with autopsy confirmation. *Ann Neurol* 50:358-65, 2001.
 - 33) Nedelska Z, Ferman TJ, Boeve BF, et al. Pattern of brain atrophy rates in autopsy-confirmed dementia with Lewy bodies. *Neurobiol Aging* 36:452-461, 2015.
 - 34) Ballard C, Ziabreva I, Perry R, et al. Differences in neuropathologic characteristics across the Lewy body dementia spectrum. *Neurology* 67:1931-1934, 2006.
 - 35) Donaghy P, Thomas AJ, O'Brien JT. Amyloid PET imaging in Lewy body disorders. *Am J Geriatr Psychiatry* 23:23-37, 2015.
 - 36) Lim SM, Katsifis A, Villemagne VL, et al. The ¹⁸F-FDG PET cingulate island sign and comparison to 123I-beta-CIT SPECT for diagnosis of dementia with Lewy bodies. *J Nucl Med* 50:1638-45, 2009.
 - 37) Imabayashi E, Yokoyama K, Tsukamoto T, et al. The cingulate island sign within early Alzheimer's disease-specific hypoperfusion volumes of interest is useful for differentiating Alzheimer's disease from dementia with Lewy bodies. *EJNMMI Res* 6:67, 2016.
 - 38) Iizuka T, Iizuka R, Kameyama M. Cingulate island sign temporally changes in dementia with Lewy bodies. *Sci Rep* 7:14745, 2017. Online.
 - 39) DeCarli C. Mild cognitive impairment: prevalence, prognosis, aetiology, and treatment. *Lancet Neurol* 2:15-21, 2003.
 - 40) Borroni B, Perani D, Broli M, et al. Pre-Clinical diagnosis of Alzheimer disease combining platelet amyloid precursor protein ratio and rCBF spect analysis. *J Neurology* 252:1359-1362, 2005.
 - 41) Hirao K, Ohnishi T, Hirata Y, et al. The prediction of rapid conversion to Alzheimer's disease in mild cognitive impairment using regional cerebral blood flow SPECT. *NeuroImage* 28: 1014-1021, 2005.
 - 42) Park KW, Yoon HJ, Kang DY, Kim BC, Kim S, Kim JW. Regional cerebral blood flow differences in patients with mild cognitive impairment between those who did and did not develop Alzheimer's disease. *Psychiatry Res* 203:201-206, 2012.
 - 43) Sanchez-Catasus CA, Stormezand GN, van Laar PJ, De Deyn PP, Sanchez MA, Dierckx RA. FDG-PET for Prediction of AD Dementia in Mild Cognitive Impairment. A Review of the State of the Art with Particular Emphasis on the Comparison with Other Neuroimaging Modalities (MRI and Perfusion SPECT). *Curr Alzheimer Res* 14:127-142, 2017.