

## A Comparative Study of Liver Cell Regenerative Activity between Primary Biliary Cirrhosis, Alcoholic Cirrhosis, Hepatic Cirrhosis, and Hepatocellular Carcinoma using Figure Analysis

Sheikh Mizanur RAHMAN, Hideyo ITAKURA, and Akira MOTODA

*Department of Pathology, Institute of Tropical Medicine, Nagasaki University,  
1-12-4 Sakamoto, Nagasaki 852, Japan*

**Abstract:** Liver cell regeneration which is a prominent pathological feature in cirrhosis of the liver was examined histopathologically and by figure analysis using image analyser. Liver cell regenerative changes in liver biopsies of primary biliary cirrhosis (PBC), alcoholic cirrhosis, hepatic cirrhosis, and hepatocellular carcinoma (HCC) were compared. In PBC, regenerative features of liver cells were mild in degree. In alcoholic cirrhosis, regenerative liver cells were less prominent than in hepatic cirrhosis. In hepatic cirrhosis, regenerative liver cell nodules were well developed, showing remarkable pleomorphism of liver cell nuclei and expansive arrangement of liver cell cords. Cellular and structural atypia were observed in some parts of regenerative nodules. These results suggest that a possibility of occurring HCC is much more prominent in hepatic cirrhosis than in PBC or alcoholic cirrhosis, because development of liver cell regeneration is most remarkable in hepatic cirrhosis.

**Key words:** Primary biliary cirrhosis, Alcoholic cirrhosis, Hepatic cirrhosis, Hepatocellular carcinoma, Liver cell regeneration, Figure analysis

### INTRODUCTION

Progressive destruction and reconstruction of hepatic lobular architecture are characteristic and fundamental features of some chronic liver diseases, especially cirrhosis of the liver. The patterns of restored architecture of liver cell cords are different from disease to disease. However, morphologic data of these facts has not so far been convincingly demonstrated.

Although there have been some works on quantitative morphology of human livers, the present article is a preliminary attempt to provide technical basis on which to introduce a computerized assessment of liver cell cord arrangement.

In our series of works (Motoda, 1992), we have put special attention to liver parenchymal changes seen in PBC, alcoholic cirrhosis, and hepatic cirrhosis with or without HCC, and tried to show objectively the differences in the morphology between above men-

tioned liver diseases. Liver cell regeneration which is a prominent pathological feature in cirrhosis of the liver was compared histopathologically and pleomorphism of liver cell nuclei by figure analysis using image analyser.

## MATERIALS AND METHODS

### *Light microscopy:*

Tissue sections were stained with hematoxylin and eosin, azan staining, orcein method, periodic acid Schiff reaction, silver impregnation, and mucicarmine. Liver biopsy cases of PBC (11 cases), alcoholic cirrhosis (14 cases), hepatic cirrhosis (13 cases), and HCC (10 cases) were reviewed. The diagnosis of each sample was histologically confirmed by a team of clinical doctors and at least three pathologists.

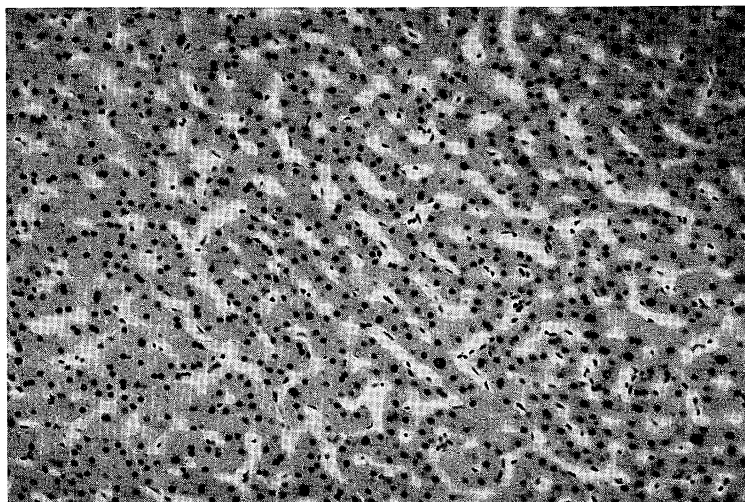
### *Figure analysis:*

Morphometric study of liver cell distribution in regenerative nodules was performed by using CB TASPER image analyser (Nachet Vision, 1986 a, b) composed of 1) TV camera: HV-730-M2-H1, 2) Nachet Vision image processor: Nachet-1500, 3) microcomputer Apple IIe. For measurement of regenerative features of liver cells we used the nuclear pleomorphism in the selected window areas ( $1,080 \times 870 \mu\text{m}$ ).

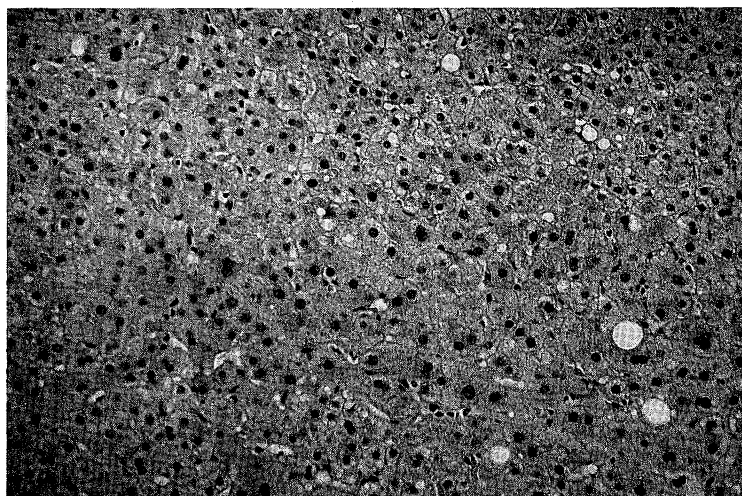
## RESULTS

Histologically liver cell shows formation of regenerative nodules in case of cirrhosis of the liver. Distortion of liver cells and reconstruction with fibrosis and pseudolobule formation were also observed. The lesions were diffuse in the whole liver. In PBC, regenerative features of liver cells at any stage of the disease were mild in degree (Fig. 1). In alcoholic cirrhosis, regenerative activity of liver cells was more prominent than in PBC (Fig. 2). In hepatic cirrhosis, regenerative nodules were more developed, showing expansive arrangement of liver cell cords. Cellular and structural atypia were observed in some parts of regenerative nodules (Fig. 3). In HCC, liver cell cords also show expansive arrangement (Fig. 4).


Granulometry of each disease by figure analysis is shown in Fig. 5 – Fig. 8. In granulometry of size of nuclei of PBC, pleomorphism is less remarkable than in alcoholic cirrhosis, hepatic cirrhosis and HCC (Fig. 5). In alcoholic cirrhosis, pleomorphism is more remarkable than in PBC, but less remarkable than in hepatic cirrhosis (Fig. 6). In hepatic cirrhosis, pleomorphism is most remarkable than in PBC, alcoholic cirrhosis and HCC (Fig. 7). In HCC, pleomorphism is remarkable than in PBC, but less remarkable than in hepatic cirrhosis. Pleomorphism is almost same as in alcoholic cirrhosis. Only the size of nuclei is slightly larger than in alcoholic cirrhosis (Fig. 8).



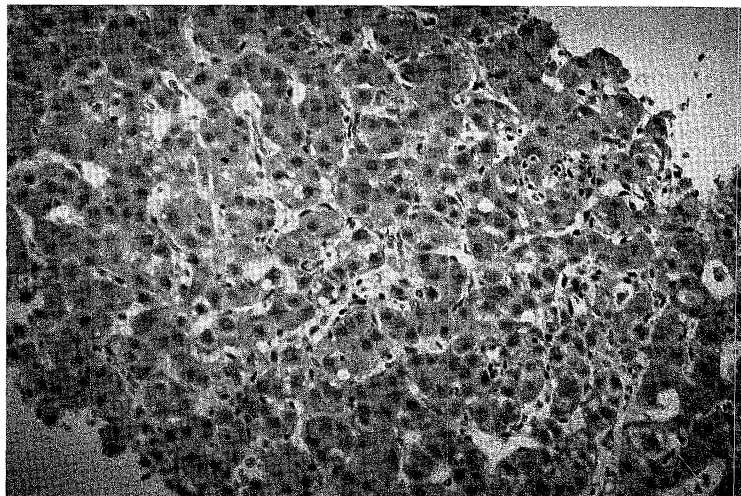
**Fig. 1.** Histological appearance of almost normal area of PBC. Liver cell cords are slightly atrophic (H & E  $\times 100$ ).



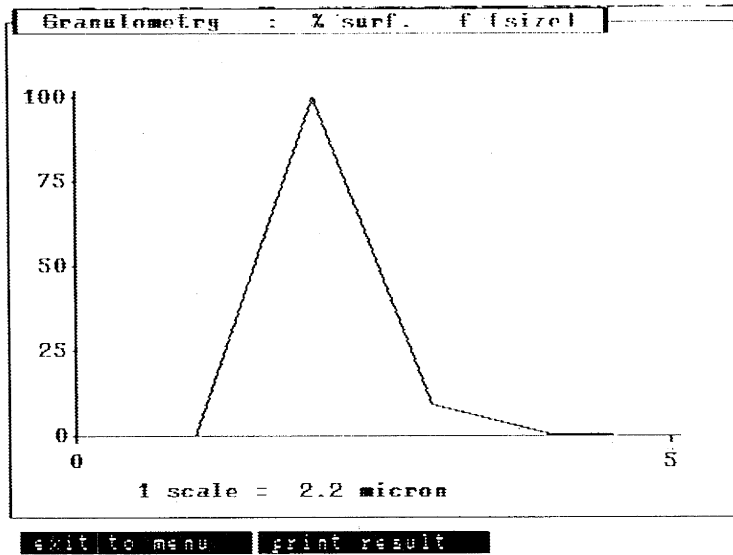
**Fig. 2.** Histological appearance of alcoholic cirrhosis. Regenerative activity of liver cells is more prominent than PBC (H & E  $\times 100$ ).



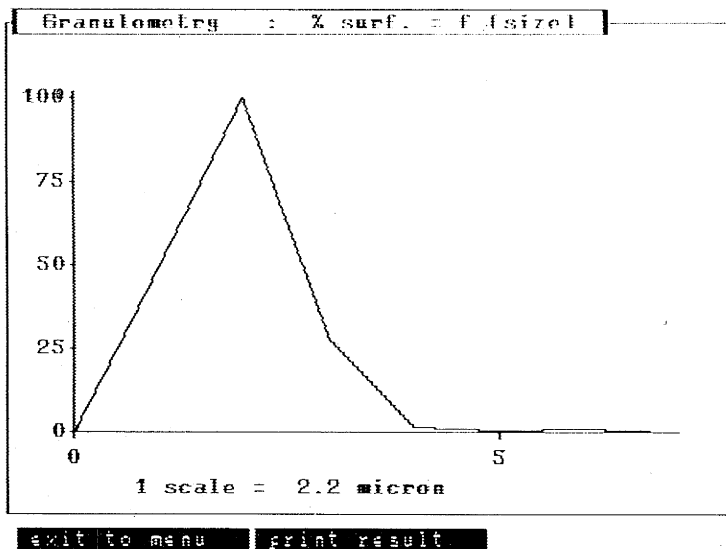
**Fig. 3.** Histological appearance of hepatic cirrhosis. Regenerative nodules are more developed than PBC, alcoholic cirrhosis and HCC (H & E  $\times 100$ ).



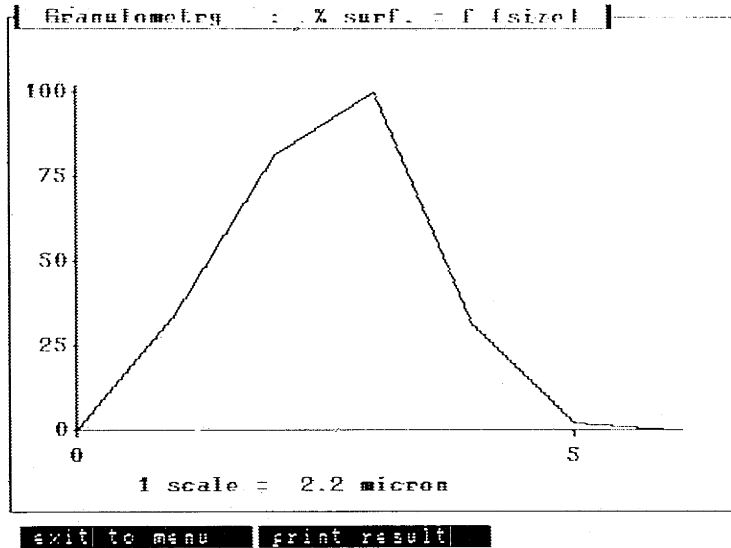
**Fig. 4.** Histological appearance of HCC. Liver cell cords show expansive arrangement (H & E  $\times 100$ ).



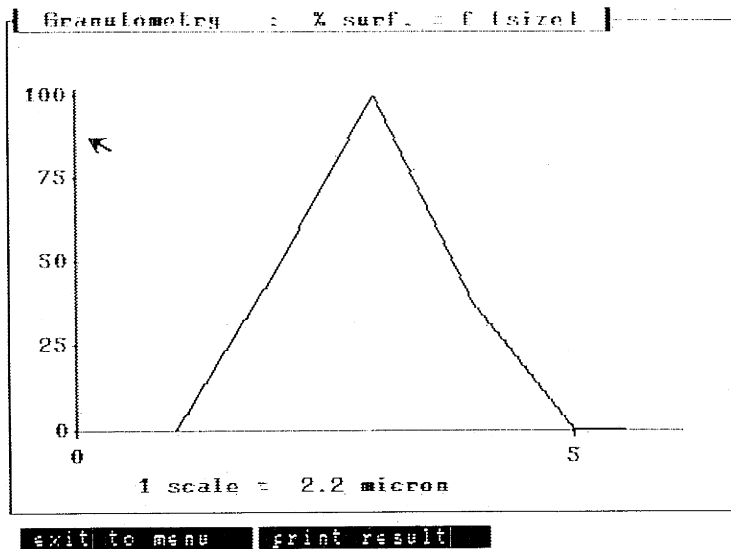
**Fig. 5.** Granulometry of size of nuclei of PBC. Pleomorphism of liver cell nuclei is less remarkable than alcoholic cirrhosis (Fig. 6), hepatic cirrhosis (Fig. 7) or HCC (Fig. 8). Scales show percentage and size of nuclei in the selected area. 1 scale=2.2 micron.



**Fig. 6.** Granulometry of size of nuclei of alcoholic cirrhosis. Pleomorphism of liver cell nuclei is remarkable than PBC (Fig.5), but less remarkable than hepatic cirrhosis (Fig. 7). Scales show percentage and size of the nuclei in the selected area. 1 scale=2.2 micron.



**Fig. 7.** Granulometry of size of nuclei of hepatic cirrhosis. Pleomorphism of liver cell nuclei is most remarkable than alcoholic cirrhosis (Fig. 6), PBC (Fig. 5) or HCC (Fig. 8). Scales show percentage and size of the nuclei in the selected area. 1 scale=2.2 micron.



**Fig. 8.** Granulometry of size of nuclei of HCC. Pleomorphism of liver cell nuclei is remarkable than PBC (Fig. 5), but less remarkable than hepatic cirrhosis (Fig. 7). Pleomorphism is almost same as alcoholic cirrhosis (Fig. 6), but the size of nuclei is slightly larger than alcoholic cirrhosis. Scales show percentage and size of the nuclei in the selected area. 1 scale=2.2 micron.

## DISCUSSION

The mechanisms of cirrhosis are considered as follows: due to long standing irritation to the liver, parenchymal cells become degenerative and necrotic, and remaining liver cells yield regenerative change for repairing. Parenchymal lesions (liver cell degeneration, necrosis, and regeneration) and mesenchymal reaction (inflammatory exudate and proliferation of collagen fibers) occur in parallel.

The morphologic definition of cirrhosis of the liver includes, a) presence of fibrous septa which link portal areas with centrilobular areas of the liver, b) nodular transformation of the parenchyma, and c) diffuse reconstruction of hepatic lobules.

Regenerative activity and nodular formation of parenchyma of liver cells are mainly seen in chronic liver diseases, especially in cirrhosis of the liver and also seen in some cases of acute, subacute and fulminant hepatitis.

In this study we observed the regenerative features of liver cells based on arrangement of liver cell cords and pleomorphism of liver cell nuclei histologically and by figure analysis. Although we have not done statistical analysis on the morphological factors of liver materials, we picked up the most representative parts from each disease. Nuclear pleomorphism with expansive arrangement of liver cell cords may be considered as one of the makers of regenerative activity in liver diseases. Different data among above mentioned liver diseases are probably showing different degrees of regenerative activity of liver cells (Betta *et al.*, 1993; Chiba and Takahashi, 1994 a, b).

The relationship between regenerative activity of liver cells and occurrence of HCC has been considered, because most remarkable degree of liver cell nuclear pleomorphism was seen in hepatitic cirrhosis and HCC. The reasons are as follows: 1) in PBC, there are very few necrosis of liver cells and the liver cell regeneration is not clear and very minimal atypism of liver cells is seen; 2) in alcoholic cirrhosis, less atypism is seen than in hepatitic cirrhosis; 3) in hepatitic cirrhosis, marked regenerative activity of liver cells frequently shows atypism. In fact occurrence of HCC is much higher in hepatitic cirrhosis.

The relationship between liver cell regeneration and fibrosis should be analysed in further studies.

These results suggest that in the aspects of morphology, a possibility of occurrence of HCC is high in hepatitic cirrhosis than in any other type of cirrhosis, because of its high regenerative parenchymal activity. Also etiological factors of liver diseases are more important in the development of liver cell regeneration.

## REFERENCES

- 1) Betta, P.G., Robutti, F., Fruttaldo, L., Pavesi, M., Pastormerlo M. & Tallarida F. (1993): Morphometric assessment of nucleolar activity in liver cells during the evolutive pathway of chronic hepatitis C to cirrhosis. *Pathologica*. 85: 31–36.
- 2) Chiba, R. & Takahashi, T. (1994 a): Quantitative morphology of human cirrhotic livers. Part I: Parameter expression of pattern as a basis for computerized classification. *Pathol. Int.* 44: 662–671.
- 3) Chiba, R. & Takahashi, T. (1994 b): Quantitative morphology of human cirrhotic livers. Part II: The statistically adequate morphological classification of liver cirrhosis. Multivariate analysis from quantified data of form. *Pathol. Int.* 44: 672–681.
- 4) Motoda A. (1992): Liver cell regeneration in cirrhosis of the liver: figure analysis of arrangement of liver cell cords. *Nagasaki Igakkai Zasshi.*, 67 (1) 1–8 (in Japanese with English abstract).
- 5) Nacet Vision (1986a): Image processor NACHET 1500. Technical data sheet 7.2A, Paris.
- 6) Nacet Vision (1986b): LUCIE, Technical data sheet 10.2A, Paris.