

## Case Report

# Primary Hepatic Carcinoid Tumor Presenting Carcinoid Syndrome and Carcinoid Heart Disease

Seiya SUSUMU,<sup>1</sup> Shigetoshi MATSUO,<sup>1</sup> Takashi AZUMA,<sup>1</sup> Shirou OBATA,<sup>2</sup> Naoyoshi OHNO,<sup>3</sup> Tomayoshi HAYASHI<sup>4</sup>

<sup>1</sup>Departments of Surgery, Nagasaki Prefectural Shimabara Hospital, Nagasaki, Japan

<sup>2</sup>Department of Radiology, Nagasaki Prefectural Shimabara Hospital, Nagasaki, Japan

<sup>3</sup>Department of Internal Medicine, Nagasaki Prefectural Shimabara Hospital, Nagasaki, Japan

<sup>4</sup>Department of Pathology, Nagasaki Prefectural Shimabara Hospital, Nagasaki, Japan

A 49-year-old man was admitted to our hospital complaining of a large hepatic tumor with edema in the lower extremities. The patient had suffered from hypertension and bronchial asthma in his twenties and from cutaneous flushing in the face in his thirties. Echocardiography revealed tricuspid valve regurgitation and marked dilatation of the right ventricle. In an exploratory laparotomy, a 15 cm-size hepatic tumor was located in the right lobe with multiple satellite lesions in both lobes of the liver. Peritoneal disseminations were present. The tumor was histologically and immunohistochemically diagnosed to be a carcinoid tumor. The levels of serum serotonin and urinary 5-hydroxyindoleacetic acid (5-HIAA) were found to be significantly high. Imaging modalities and intraoperative findings showed no evidence of any tumors elsewhere. These findings led us to the diagnosis of a primary hepatic carcinoid tumor with carcinoid syndrome and carcinoid heart disease. The patient has been treated with hepatic artery embolization, oral chemotherapy and octreotide acetate. After six months of such treatment, the hepatic tumor has decreased slightly in size, and the levels of serum serotonin and urinary 5-HIAA have dropped.

ACTA MEDICA NAGASAKIENSIA 51: 125 - 128, 2006

**Keywords:** Carcinoid tumor; Liver; Primary

## Introduction

Physicians usually wonder whether hepatic carcinoid tumors are primary or secondary, because they have been seldom discovered.<sup>1</sup> Yao and Vauthey<sup>2</sup> stated that they were hesitant to designate the primary site of a carcinoid tumor as the liver because it is not uncommon that small occult primary carcinoid tumor is associated with extensive hepatic involvement. However, if the primary lesions are not identified elsewhere at the time of their discovery, we have to diagnose primary hepatic carcinoid tumor (PHCT).

Even in patient with PHCT, the frequency of carcinoid syndrome reported has been unexpectedly low.<sup>3</sup> Carcinoid heart disease is a serious condition in patient with carcinoid tumor and may be a direct cause of death.<sup>4,5</sup> We herein present a case of PHCT with carcinoid syndrome and carcinoid heart disease that was treated with hepatic artery embolization (HAE) and octreotide acetate.

## Case report

A 49-year-old man was admitted in April 2005 to Nagasaki prefectural Shimabara Hospital complaining of a large hepatic mass with edema in both lower extremities. His history included hypertension, bronchial asthma and cutaneous flushing of the face, all of which had occurred in his twenties or thirties. On admission, physical examination revealed sporadic cutaneous flushing of the face. The abdominal mass was not palpable. The results of complete blood counts were within normal limits. Blood chemistries and serum electrolytes were also in normal range except for a slight elevation of lactate dehydrogenase—285 IU/L (normal range: 119-229 IU/L). Viral information showed no evidence of hepatitis B or C. Tumor markers such as carcinoembryonic antigen, cancer antigen 19-9,  $\alpha$ -fetoprotein and protein induced by vitamin K deficiency or antagonist-II were within normal limits.

**Address correspondence:** Seiya Susumu, M.D., Department of Surgery, Nagasaki Prefectural Shimabara Hospital, 7895 Shimokawajiri, Shimabara, Nagasaki 855-0861 JAPAN

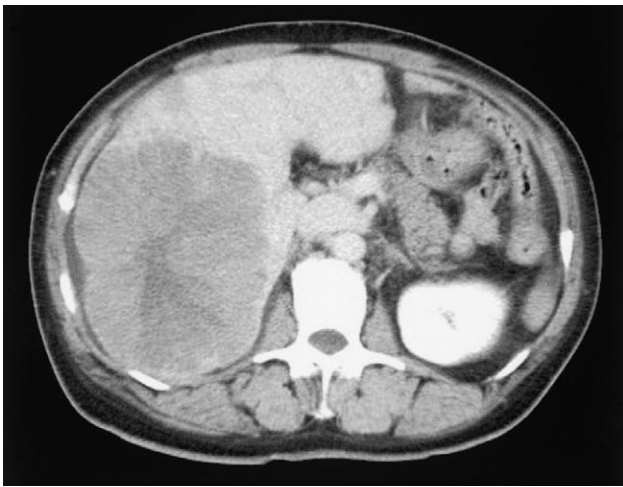
TEL: +81-(0)957-63-1145, FAX: +81-(0)957-63-4864, E-mail: susumu\_gi@mac.com

Received April 6, 2006; Accepted November 27, 2006

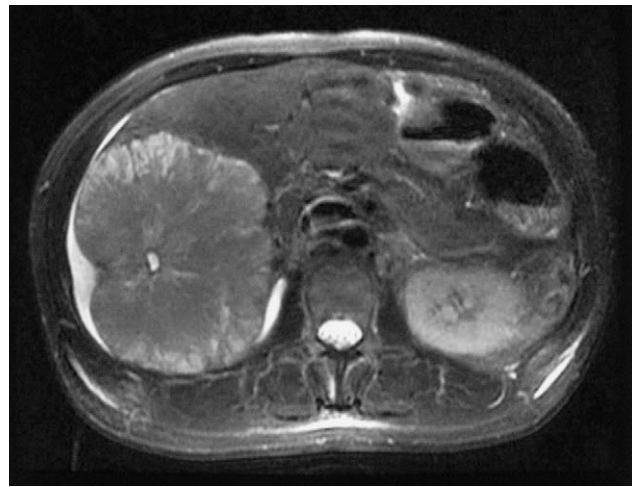Ultrasonography revealed a large hyperechoic mass with heterogeneity in the right lobe of the liver. Computed tomography (CT) demonstrated a lobulated mass in the right lobe of the liver with enhancement in the peripheral area of the tumor that reached 15 cm in diameter. An irregular non-enhanced zone was visible in the central area (Figure 1). Magnetic resonance imaging (MRI) showed a mass with low signal intensity and partly high signal intensity on T1-weighted images (WI) and with high signal intensity and very high signal intensity in the center of the tumor on T2-WI (Figure 2). Gastrofiberscopy and colonofiberscopy showed no evidence of tumor. Chest and brain CT also revealed no tumor. Hepatic angiography

with delayed enhancement demonstrated tiny and fine vessels in the tumor. Echocardiography showed severe tricuspid valve regurgitation and marked dilatation of the right ventricle (Figure 3). The inferior vena cava was also dilated to 19 mm in diameter.

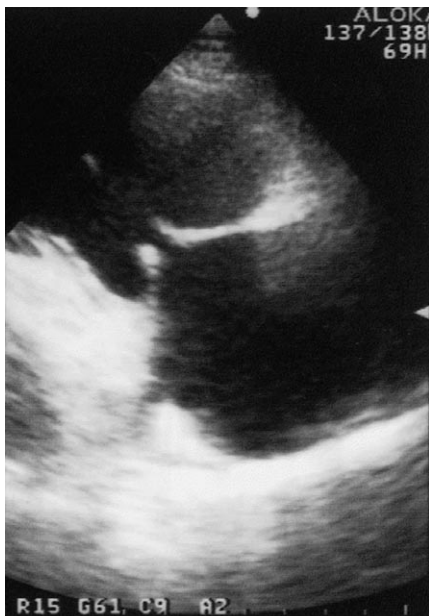With the diagnosis of hepatocellular carcinoma—not related to viral hepatitis—an exploratory laparotomy was performed in May 2005. In surgery a main hepatic tumor, measuring 20 cm in diameter, was found in the right lobe of the liver, and numerous small tumors of whitish yellow color, measuring 2 mm to 2 cm in size, were located in both lobes of the liver (Figure 4 A) Peritoneal disseminations were also found.



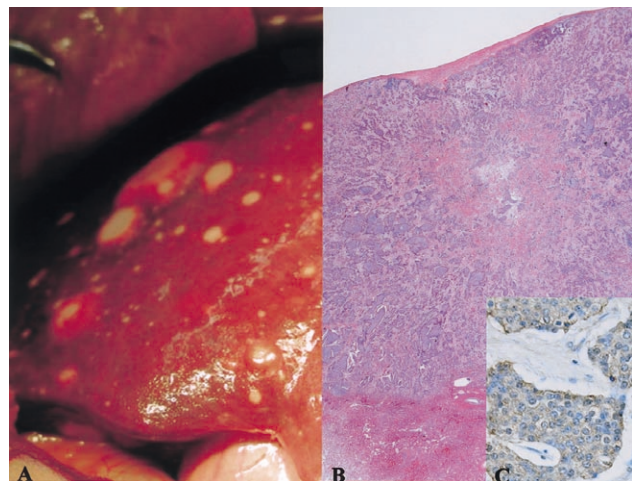
**Figure 1.** CT at venous phase demonstrating a lobulated mass with enhancement of the peripheral area of the tumor and an irregular non-enhanced zone in the central area.



**Figure 2.** MRI showing a mass with high signal intensity on T2-weighted images.

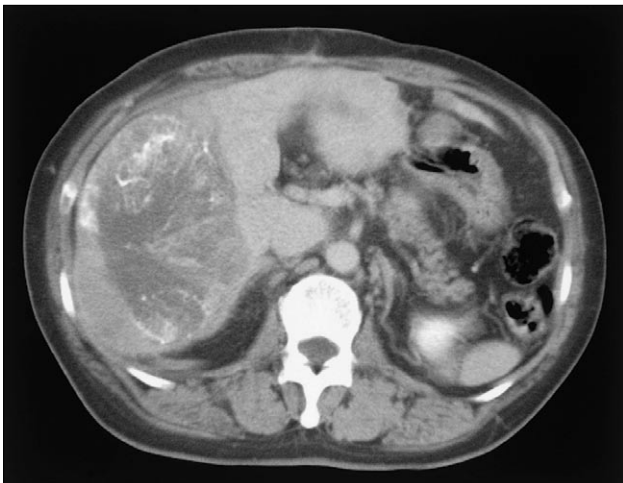


**Figure 3.** Echocardiography showing severe tricuspid valve regurgitation and marked dilatation of the right ventricle (TRPG=49.2 mmHg).



**Figure 4.** A. Numerous small tumors are visible in both lobes of the liver. B. Biopsy specimens histologically revealing proliferation of the oval-shaped cells, surrounded by fibrous stroma, mainly of nest-like trabecular pattern and partly of rosetta-like glandular pattern. C. Tumor cells showing positive staining for chromogranin A.

Hepatic resection was not considered to be a possible cure. Biopsy specimens from the liver tumor histologically revealed proliferation of oval-shaped cells, surrounded by fibrous stroma, mainly of nest-like trabecular pattern and partly of rosetta-like glandular pattern (Figure 4 B). The tumor cells immunohistochemically showed positive staining for chromogranin A and synaptophysin (Figure 4 C). On the basis of these findings, the tumor was considered most likely to be carcinoid tumor. Postoperative endocrinological studies were as follows: serum serotonin (5-hydroxytryptamine, 5-HT)—1184 ng/mL (normal range: 57-230 ng/mL); plasma 5-hydroxyindoleacetic acid (5-HIAA)—405.7 ng/mL (1.8-6.1 ng/mL); urinary 5-HIAA—203.1 ng/mL (1.0-6.0 ng/mL); plasma adrenocorticotropic hormone—21.9 pg/mL (7.4-55.7 pg/mL). The present case was finally diagnosed to be PHCT with carcinoid syndrome and carcinoid heart disease. Oral chemotherapy and octreotide acetate therapy started after HAE. In clinical settings, the schedule was S-1 (TS-1) of 100 mg/body weight (day 1-28, orally) followed by a 2-week drug-free period and octreotide acetate (Sandostatin LAR) of 20 mg/body weight (every 4 weeks, intramuscularly). After six months of the treatment, the large hepatic tumor decreased slightly in size (Figure 5), and 5-HT and 5-HIAA were of 589 ng/mL and 81.2 ng/mL, respectively.



**Figure 5.** CT showing a large hepatic tumor slightly decreased in size 6 months after HAE.

## Discussion

Out of 13,715 carcinoid tumors in 1950-1999, the Surveillance, Epidemiology, and End Results (SEER) Program of the National Cancer Institute registered 45 as PHCTs (0.41%).<sup>1</sup> However, Sano et al.<sup>6</sup> verifying 30 cases reported as PHCTs in the English literature, found only 8 true. They pointed out that long-term follow-up is required to exclude occult extrahepatic primaries because carcinoid tumors show slow progressive growth. For this reason, a long follow-up will be needed to confirm that our case is of true PHCT.

Regarding carcinoid syndromes, most typical clinical manifestations

include diarrhea and cutaneous flushing. 5-HT and other products secreted in the portal vein from carcinoid tumor are metabolized and inactive in the liver, but when the presence of liver metastases becomes known or when the primary lesions are found in the bronchus or the ovary, then carcinoid syndrome becomes evident.<sup>7</sup> According to an analysis of 11,842 reported cases of carcinoid tumor including neuroendocrine tumors, the carcinoid syndrome occurred in 7.7% of all cases.<sup>8</sup> Even in cases of PHCTs, only 5% (2 of 41 cases with detailed description of symptoms) suffered from typical carcinoid syndrome.<sup>3</sup> Considering that cutaneous flushing has been present in our patient since his thirties, we suggest that the hepatic carcinoid tumor occurred at that time.

Carcinoid heart disease is a frequent complication of the carcinoid syndrome, usually presenting as right-sided valvular heart disease. Serotonin excretion plays a role in the development of carcinoid heart disease (CHD), but the exact pathogenesis is not known.<sup>12</sup>

It has been reported that the incidence of carcinoid heart disease in patients with primary or metastatic carcinoid tumors ranges from 20% to 70%.<sup>9-12</sup> Quaedvlieg et al.<sup>12</sup> also reported that the appearance of carcinoid heart disease seems to have no relation to the duration of the disease and the size of the tumor. The replacement of affected valve is the best treatment for carcinoid valvular disease.<sup>10</sup> If possible in the present case, tricuspid valve replacement should have been performed because the severe tricuspid valve regurgitation and right-sided heart failure with edema in the lower extremities showed no change as of March 7, 2006.

We did not perform a hepatic resection for our case because peritoneal dissemination and multiple hepatic tumors were found in surgery. Hepatic resection, if possible, is generally regarded as the most effective treatment for PHCT. The median survival time and the 10-year survival rate are reported to be 44.7 months and 68%, respectively, for hepatic resected patients.<sup>3,14</sup> On the other hand, HAE and hepatic artery chemoembolization (HACE) are options for patients with PHCT or with metastatic hepatic carcinoid tumor. For the latter group of patients, the median overall survival time is reported to be 31 months.<sup>15</sup> Patients treated with HACE, compared to those treated with HAE, survived longer (31.5 months vs. 18.2 months) and improved response (50% vs. 25%), although the difference was not statistically significant.<sup>16</sup>

In conclusion, our case is considered to be PHCT at present, but a long-term follow-up is needed. HAE may potentially be an effective treatment for patients with unresectable liver carcinoid tumors.

## References

1. Modlin IM, Lye KD, Kidd M. A 5-decade analysis of 13,715 carcinoid tumors. *Cancer* 97: 934-959, 2003
2. Yao JC, Vauthey JN. Primary and metastatic hepatic carcinoid: Is there an algorithm? *Ann Surg Oncol* 10: 1133-1135, 2003
3. Iwao M, Nakamuta M, Enjoji M et al. Primary hepatic carcinoid tumor: case report and review of 53 cases. *Med Sci Monit* 7: 746-750, 2001
4. Roberts WC, Sjoerdsma A. The cardiac disease associated with the carcinoid syndrome (carcinoid heart disease). *Am J Med* 36: 5-34, 1964
5. Pellikka PA, Tajik AJ, Khandheria BK et al. Carcinoid heart disease: clinical and echocardiographic spectrum in 74 patients. *Circulation* 87: 1188-1196, 1993

6. Sano K, Kosuge T, Yamamoto J et al. Primary hepatic carcinoid tumors confirmed with long-term follow-up after resection. *Hepatogastroenterology* 46: 2547-2550, 1999
7. Van der lely AJ, de Herder WW. Carcinoid syndrome: diagnosis and medical management. *Arq Bras Endocrinol Metabol* 49: 850-860, 2005
8. Soga J. Carcinoid and their variant endocrinomas. An analysis of 11842 reported cases. *J Exp Clin Cancer Res* 22: 517-530, 2003
9. Tomebrandt K, Eskilsson J, Nobin A. Heart involvement in metastatic carcinoid disease. *Clin Cardiol* 9: 13-19, 1986
10. Connolly HM. Carcinoid heart disease: medical and surgical considerations. *Cancer Control* 8: 454-460, 2001
11. Quaedvlieg PF, Lamers CB, Taal BG. Carcinoid heart disease: an update. *Scand J Gastroenterol Suppl* 236: 66-71, 2002
12. Zuetenhorst JM, Bonfrer JM, Korse CM, Bakkec R, van Tinteren H, Taal BG. Carcinoid heart disease: The role of urinary 5-hydroxyindoleacetic acid excretion and plasma levels of atrial natriuretic peptide, transforming growth factor- $\beta$  and fibroblast growth factor. *Cancer* 97: 1609-1615, 2003
13. Modlin IM, Kidd M, Latich I, Zikusoka MN, Shapiro MD. Current status of gastrointestinal carcinoids. *Gastroenterology* 128: 1717-1751, 2005
14. Knox CD, Anderson CD, Lamps LW, Adkins RB, Pinson CW. Long-term survival after resection for primary hepatic carcinoid tumor. *Ann Surg Oncol* 10: 1171-1175, 2003
15. Gupta S, Yao JC, Ahrar K et al. Hepatic artery embolization and chemoembolization for treatment of patients with metastatic carcinoid tumors: the M.D.Anderson experience. *Cancer J* 9: 261-267, 2003
16. Gupta S, Johnson MM, Murthy R et al. Hepatic arterial embolization and chemoembolization for the treatment of patients with metastatic neuroendocrine tumors: variables affecting response rates and survival. *Cancer* 104: 1590-1602, 2005