

Usefulness of Transdermal Glyceryl Trinitrate for Radial Arterial Spasm on Arteriovenous Hemodialysis Fistula Operation in Uremic Patients

Sadamu HIRASHIMA,^{1,2} Mitsuru NOGUCHI,¹ Yoshio HORITA,³ Manabu MATSUO,¹ Masato TADOKORO,³ Kouichi TAURA,³ Hiroshi KANETAKE¹

¹Department of Urology, Nagasaki University Graduate School of Biomedical Sciences, Nagasaki, Japan

²Department of Urology, Nagasaki Municipal Medical Center, Nagasaki, Japan

³Department of Internal Medicine, Nagasaki Municipal Medical Center, Nagasaki, Japan

Vasospasm sometimes disturbs successful blood access for hemodialysis, and prevention of vasospasm is desirable when constructing arteriovenous fistulae. We first investigated vasospasm of the radial artery in this operation and analyzed factors associated with this phenomenon in 20 patients with end-stage renal disease. Alteration of blood flow in the radial artery was evaluated in them, and intima-media thickness (IMT), endothelial function index (EFI) and laboratory data were analyzed. Vasospasm occurred in 9 of 20 cases (45.0%) at 5 min after anastomosis, and displayed a marginally significant correlation ($r=0.31$, $p=0.081$) with EFI. We then conducted a randomized study of 84 patients with end-stage renal disease to examine the effects of administering transdermal glyceryl trinitrate (GTN) in this operation. EFI was significantly correlated with IMT ($r=-0.45$, $p<0.001$). At 5 min after anastomosis, vasospasm occurred in 12 (28.6%) of 42 patients who were administered GTN, while it occurred in 20 (47.6%) of 42 patients without GTN administration (controls); the difference was marginally significant ($p=0.072$). In patients with $IMT \leq 1.1$, alteration of diameter (5 min/1 min after anastomosis) was significantly reduced compared with controls ($p=0.032$). These data suggest that IMT could offer a predictor of vasospasm occurrence during arteriovenous fistula operations. Use of pre-operative transdermal GTN may be effective in preventing vasospasm during such surgery.

ACTA MEDICA NAGASAKIENSIA 50: 23 - 28, 2005

Keywords: Arteriovenous hemodialysis fistula; Intima-media thickness; Vasospasm; Endothelial function; Glyceryl trinitrate

Introduction

Vascular access is an integral and crucial aspect of hemodialysis treatments provided for patients with end-stage renal disease (ESRD). Autogenous radiocephalic arteriovenous fistula (AVF) has been regarded as the primary and best choice for vascular access in hemodialysis patients. The Brescia-Cimino AVF offers a low rate of complications and a high patency rate.¹ Successful construction of this type of AVF usually depends on the quality and diameter of the radial artery and cephalic vein at the wrist level. Despite the presence of an excellent artery and vein, surgeons often encounter intra- and post-operative arterial spasm in patients undergoing construction of an internal AVF. Vasospasm in patients undergoing AVF construction is relatively common, and may cause insufficient arterial blood flow through the anastomosed vein immediately after anastomosis, affect-

ing patency and maturation of the dialysis fistula at an early phase. Although the exact mechanisms underlying vasospasm and suitable methods of prevention are unknown, perioperative spasm has generally been attributed to exposure to hypoxemia and endothelial injury.²⁻⁴

Regarding the diagnosis and prevention of vasospasm in patients undergoing surgery for AVF, Owada et al.⁵ reported diagnosis of vasospasm using ultrasonic Doppler flowmetry, and examined the prophylactic effects of nicardipine. However, to the best of our knowledge, relatively few studies of vasospasm have been conducted in patients undergoing construction of AVF, and no investigations have described associations between radial arterial spasm in a newly constructed AVF and endothelium-dependent and -independent function.

The present study aimed: (1) to evaluate peri- and postoperative

Address correspondence: Sadamu Hirashima, M.D., Department of Urology, Oomura Municipal Hospital, 133-22, Kogashima-machi, Oomura, Nagasaki 856-0817 JAPAN

TEL: +81-(0)957-52-2161, FAX: +81-(0)957-52-7607, E-mail: kappamn8@k3.dion.ne.jp

Received January 31, 2005; Accepted February 7, 2005

hemodynamic changes (diameter of radial artery) in newly constructed AVF (Study I); and (2) to investigate the peri- and postoperative hemodynamic effects on newly constructed AVF of administering transdermal glyceryl trinitrate (GTN) in a randomized study, and identify relationship between vasospasm during construction of AVF and atherosclerosis in patients with ESRD; atherosclerosis was evaluated by endothelial function and intima-media thickness (IMT) (Study II). Study protocols were approved by the Nagasaki Municipal Medical Center Research Ethics Committee, and all subjects provided written informed consent.

Subjects and Methods

Patients

Study I

Between August and December 2001, 52 patients with chronic renal failure underwent AVF formation at the Renal Unit of Nagasaki Municipal Medical Center, and 31 of them underwent autogenous radiocephalic wrist access. We excluded patients who exhibited systemic immunological disease as the etiology of renal insufficiency, any peripheral vascular disease, severe concomitant disease affecting cardiovascular status or history of continuous administration of nitrates. Ultimately, among those eligible patients, 20 patients (12 men and 8 women) agreed to participate in Study I. Mean (standard deviation (SD)) age of subjects was 57.4 (10.6) years. Underlying pathologies in these patients with renal insufficiency comprised: hypertensive nephrosclerosis (n=7); diabetic nephropathy (n=7); and chronic glomerulonephritis (n=6). Regular medications were stopped for 7 days preoperatively, and subjects were asked to omit anticoagulant drugs for 7 days preoperatively and 3 days postoperatively. Hemodynamic measurements, IMT and endothelial function index (EFI) were performed. Blood samples were taken in the fasting state, and body mass index (BMI) was calculated as body weight (kg)/(height (m)).²

Study II

Between January 2002 and August 2003, 186 AVF operations were performed at Nagasaki Municipal Medical Center. Of these, 105 patients underwent autogenous radiocephalic wrist access, among whom 84 patients with ESRD (45 men and 39 women) were enrolled in Study II. Pathology underlying chronic renal failure comprised: hypertensive nephrosclerosis (n=33); diabetic nephropathy (n=28); chronic glomerulonephritis (n=17); polycystic kidney disease (n=3); and undetermined cause (n=3). Exclusion criteria and preoperative preparations were the same as in Study I. Preoperatively, the 84 patients were randomly allocated into Study and Control groups. In the Study group (n=42), a 25mg per 24 hours a GTN adhesive patch (Nitroderm TTS, Novartis, Basel, Switzerland) delivering 25 mg of GTN over 24 h was applied to the front chest skin prior to 2 h preoperatively. The Control group (n=42) received no medication preoperatively.

Assessment of conduit artery endothelial function

Endothelium-dependent vasodilation was determined by recording dilator response in the brachial artery to increased blood flow generated during reactive hyperemia of the downstream forearm. Endothelium-independent vasodilation was assessed by measuring dilator response in the brachial artery to a submaximal dose of GTN (0.3 mg sublingually). Endothelium-dependent and -independent vasodilation were expressed as percentage flow-mediated vasodilation (%FMD), indicating percentage increases in brachial artery diameter during reactive hyperemia, and percentage GTN-induced dilation (%GTN), respectively. Endothelial function index (EFI) was calculated as the ratio of %FMD to %GTN.

Subjects were investigated in a supine position in a temperature-controlled laboratory (23-26 °C). The brachial artery of the arm to be operated on was scanned in longitudinal section 5-15 cm above the elbow using a 10.0-MHz linear array transducer (Model SSD-4000, Aloka, Tokyo, Japan). Depth and gain settings were set to optimize images of the lumen-arterial wall interface, and operating parameters were not changed during the study. When a satisfactory transducer position was found, the position was marked on the skin, and the arm remained in the same position throughout the study. All ultrasound scans were recorded on magneto-optical disk for offline analysis. Baseline recording of arterial diameter was performed.

Endothelium-dependent vasodilation was measured first. Increased flow was then induced by inflation of a pneumatic tourniquet placed around the forearm (distal to the scanned part of the artery) to a pressure of 300 mmHg for 5 min, followed by release. Subsequent scans were taken continuously at 40-180 s after cuff deflation. A repeated blood flow recording was also included for the first 15 s after cuff release. Endothelium-independent dilatation of the brachial artery was subsequently assessed 20 min after the endothelium-dependent dilatation test. Brachial artery diameter at 5 min after nitrate administration was used to calculate the proportional increase from baseline. During assessment of endothelial function, no patients displayed any adverse reactions to GTN, including headache, nausea or hypotension. Analysis was performed by an experienced vascular technician blinded to the laboratory data of study subjects.

Common carotid artery measurements

IMT of the common carotid artery (CCA) was measured preoperatively using high-resolution B-mode ultrasonography (with a 7.5-MHz mechanical sector transducer). Patients were examined in the supine position. Both longitudinal and cross-sectional images were viewed. Longitudinal views were obtained at 3 angles: anterior oblique; lateral; and posterior oblique. All ultrasonographic assessments of carotid arteries were made by 1 physician blinded to the clinical conditions of patients. Distance from the lumen-intima interface to the collagen-containing upper layer of the tunica adventitia (distance between 2 echogenic lines separated by hypochoic or

anechoic space) as described by Pignoli et al.⁶ was used to determine IMT. The basic techniques reported by Handa et al.⁷ and Suzuki et al.⁸ were utilized. Measurements were made bilaterally at 10, 20 and 30 mm proximal to the bifurcation on anterior oblique, lateral and posterior oblique longitudinal views. Internal and external carotid arteries were not examined, as these were not accessible in all patients. Only the far wall was used. Mean values were calculated from 18 total measurements and used as IMT of the CCA.

Operative procedure and hemodynamic measurements

With the patient under local anesthesia, a longitudinal incision between the radial artery and cephalic vein was made. After mobilization, the cephalic vein was dilated using heparinized saline solution (10 units/mL), and anastomosis from the side of radial artery to the side of the radial cephalic vein was created using a running 7-0 polypropylene (Prolene) suture was created for all patients by the same surgeon. The sensory branch of the radial nerve was carefully avoided. A 10.0-MHz ultrasonic probe (Model UST-5546, Aloka, Tokyo, Japan) was fixed transcutaneously above the radial artery, 2 cm proximal to the site of anastomosis,⁵ and radial artery diameter was measured transcutaneously before and at 1, 5, 15, 30, 60 and 120 min after anastomosis. Diameter of the radial artery was measured 3 times using the same method, and the mean was used for results. Blood pressure was measured before anastomosis surgery and throughout the study.

A small number of studies into vasospasm have focused on treatment of medium and large vessel.⁹ Coon et al.¹⁰ reported that calcium channel blocker inhibited vasospasm of the CCA induced by mechanical flow-limitation in a primate model. In that study, cross-sectional area of the CCA during spasm decreased $31.6 \pm 1.9\%$, indicating a 17.3% reduction in blood flow. Arterial blood flow was calculated using the formula of Kasulke,¹¹ as follows:

$$\text{blood flow (mL/min)} = 0.6 \times v \times \pi r^2,$$

where v is velocity (cm/s) and r is arterial internal radius (mm). Vasospasm was thus defined in the present study as a reduction in diameter of the radial artery after anastomosis of $>20\%$.

Statistical analysis

Data were summarized as mean \pm standard deviation (SD). Influence of factors on vasospasm was examined by correlation between respective factors and the ratio of two measurements of diameter of the radial artery made at 1 min and 5 min after anastomosis. Clinical characteristics, blood chemistry and vascular study results were compared between Control and Study groups using Mann-Whitney U -test. The ratio of two measurements of diameter of the radial artery made at 1 min and 5 min after anastomosis was also compared between Control and Study groups using Mann-Whitney U -test after classifying subjects into two groups by IMT. Dynamics of radial artery diameter after anastomosis relative to the pre-operative measurements (called "standardized radial artery diameter" for short) was analyzed using t -test; the significance level of each test was set at

0.0085 by Bonferroni inequality to keep the overall significance level at 0.05.

Results

Study I

Dynamics of normalized radial artery diameter in the 20 patients of Study I is shown in Figure 1. Diameter of the radial artery was significantly ($p < 0.0001$) increased at 1 min after anastomosis, then significantly ($p < 0.0001$) decreased at 5 min after anastomosis. It approached the pre-operative measurements at 15 min after anastomosis and kept close to the pre-operative measurements through 120 min after anastomosis. Vasospasm occurred in 9 of 20 patients (45.0%) by 5 min after anastomosis. The correlations between respective factors shown in Table 1 and the ratio of two measurements of diameter of the radial artery made at 1 min and 5 min after anastomosis varied from -0.26 to 0.31 and none was significant ($p > 0.122$) except for EFI, which showed a marginally significant correlation ($r = 0.31$, $p = 0.081$).

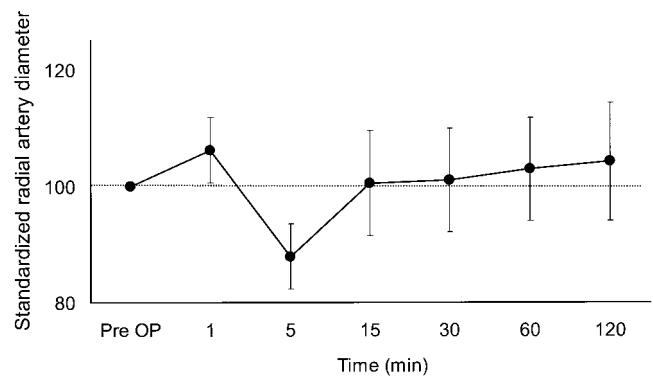


Figure 1. Dynamics of standardized radial artery diameter after anastomosis in 20 patients. Diameter of the radial artery was significantly ($p < 0.0001$) increased at 1 min after anastomosis, then significantly ($p < 0.0001$) decreased at 5 min after anastomosis.

Study II

No significant difference was observed in clinical characteristics, results of blood biochemistry analysis or results of vascular study between Control and Study groups except for HDL cholesterol and triglycerides (Table 1). EFI and baseline diameter of the radial arterial displayed no significant differences between Control and Study groups.

Change in radial artery diameter by AVF operation in Control and Study groups

Diameter of the radial artery was significantly ($p < 0.0001$) increased at 1 min after anastomosis compared with baseline in both the Study and Control groups (Figure 2). Standardized radial artery

Table 1. Clinical characteristics, blood chemistry and vascular study results in Control group and Study group

Parameters	Control group n = 42	Study group n = 42	p-value
Clinical characteristics			
Gender(male/female)	23/19	22/20	0.827
Age (years)	58.2 ± 11.5	60.8 ± 11.8	0.213
BMI (kg/m ²)	22.2 ± 3.9	21.3 ± 3.0	0.150
SBP (mmHg)	147.0 ± 30.3	151.6 ± 21.3	0.694
DBP (mmHg)	76.4 ± 12.4	73.4 ± 15.1	0.393
Blood chemistry			
Hemoglobin (g/dL)	10.9 ± 12.8	10.4 ± 12.0	0.303
Total cholesterol (mg/dL)	178.6 ± 55.7	174.1 ± 39.9	0.123
HDL cholesterol (mg/dL)	43.0 ± 11.3	40.6 ± 14.0	0.035
Triglycerides (mg/dL)	135.0 ± 57.2	137.8 ± 48.9	0.032
Blood urea nitrogen (mg/dL)	83.1 ± 67.6	85.2 ± 67.7	0.362
Serum creatinine (mg/dL)	8.8 ± 3.5	8.7 ± 1.9	0.217
Ca × P (mg ² /dL ²)	44.5 ± 12.7	49.1 ± 14.5	0.171
Intact parathyroid hormone (pg/mL)	187.1 ± 101.5	210.4 ± 150.2	0.293
C-reactive protein (mg/dL)	1.1 ± 0.9	1.2 ± 2.4	0.364
Vascular study			
Radial artery diameter (mm)	3.2 ± 0.8	3.3 ± 1.0	0.415
IMT (mm):Carotid artery	1.1 ± 0.2	1.1 ± 0.2	0.757
EFI	76.8 ± 22.7	79.2 ± 28.2	0.886

Note: BMI=body mass index; SBP=systolic blood pressure; DBP=diastolic blood pressure; IMT=intima-media thickness; EFI=endothelial function index

diameter reached 107.6 ± 8.2 in the Study group and 107.2 ± 6.6 in the Control group at 1 min after anastomosis. At 5 min after anastomosis, standardized radial artery diameter was significantly decreased both in the Study group (97.0 ± 4.9 , $p=0.0003$) and in the Control group (86.2 ± 5.6 , $p<0.0001$); at this time point, the standardized radial artery diameter was significantly larger in the Study group than in the Control group ($p<0.0001$). At 15 min after anastomosis and thereafter, mean of the standardized diameter of the radial artery stayed above the baseline in both groups, indicating that vasospasm had disappeared; the difference between the mean and baseline was significant in Study group at 30, 60 and 120 min after anastomosis ($p=0.0003$, $p<0.0001$ and $p<0.0004$, respectively), while it was not significant in Control group at either of these time points. Vasospasm occurred in 12 (28.6%) of 42 patients in the Study group and 20 (47.6%) of 42 patients in the Control group at 5 min after anastomosis; the difference was marginally significant ($p=0.0723$).

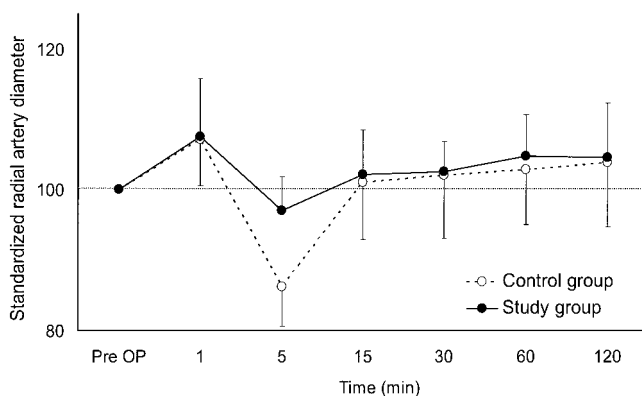


Figure 2. Dynamics of standardized radial artery diameter after anastomosis in 42 patients of Study and Control groups, respectively. Dynamics both in Study group and in Control group was similar to that shown in Figure 1. At 5 min after anastomosis, the standardized radial artery diameter was significantly larger in the Study group (97.0 ± 4.9) compared to the Control group (86.2 ± 5.6) ($p<0.0001$).

Correlation between IMT and EFI in ERDS patients

Vasospasm is considered to be associated with arterial wall compliance. Patients with chronic renal failure tend to display arteriosclerosis, and a disruption of the balance between Ca and P due to vitamin D3 deficiency. We therefore analyzed relationship between EFI and IMT in 84 patients with ERDS.

EFI displayed a significant correlation with IMT in ERDS patients ($r=-0.45$, $p<0.0001$) (Figure 3), so arterial sclerosis is predictably associated with reduced endothelial function.

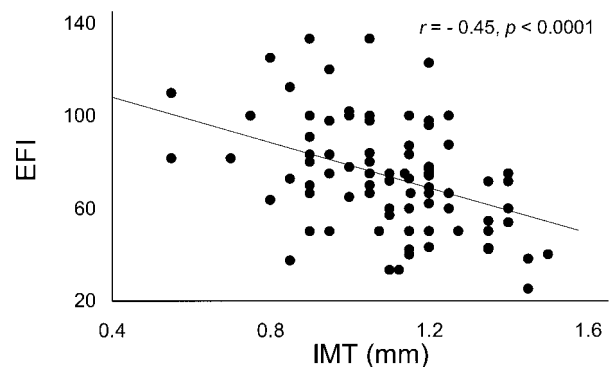


Figure 3. Scatter plots of intima-media thickness (IMT) and endothelial function index (EFI) in 84 patients with end-stage renal disease.

Effects of GTN adhesive patch

Median IMT in the 84 ERDS patients was 1.1 ± 0.2 mm (range, 0.55-1.5 mm). Kawamori et al. reported an IMT in Japanese healthy volunteers of <1.1 mm.¹² Furthermore, the 2002 Guidelines of the Japan Academy of Neurosonology announced that a maximum IMT >1.1 mm is in the abnormal range. Patients were thus divided into 2 groups: $IMT \leq 1.1$; and $IMT > 1.1$. Effects of the GTN adhesive patch on prevention of vasospasm were investigated (Figure 4). In patients with $IMT \leq 1.1$, the ratio of diameter at 5 min after

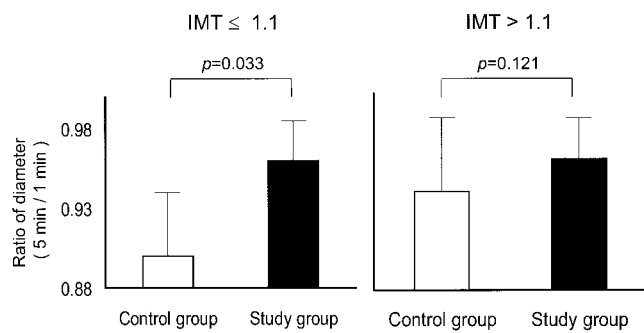


Figure 4. Effects of GTN adhesive patch on ratio of diameter (5 min/1 min after anastomosis) in subjects displaying $IMT \leq 1.1$ or > 1.1 .

anastomosis to diameter at 1 min after anastomosis was significantly higher (0.96 ± 0.05) in the Study group than in the Control group (0.90 ± 0.08) ($p=0.033$). In patients with $IMT > 1.1$, no significant difference in this ratio was identified between Study group (0.96 ± 0.05) and Control group (0.94 ± 0.09) ($p=0.121$).

Discussion

Peri- or postoperative vasospasm represents one of the greatest problems limiting the maintenance of blood flow through an AVF. Incidence of vasospasm in the radial artery in patients undergoing AVF surgery was reported by Anderson et al.¹³ as approximately 50% (measuring blood flow of the cephalic vein), and by Owada et al.⁵ as 33% (measuring blood flow of the radial artery). In the present study, vasospasm occurred in 45% of patients and was improved at 15 min after anastomosis in Study I. Uremic patients with newly constructed AVF displayed significant hemodynamic instability during the early postoperative period. However, most vessels recovered fully by the following day and flow was greatly increased compared with intraoperative values in the majority of cases. Sizes of the radial artery and cephalic vein, as determined by either ultrasonography or clinical assessment, display no correlations with the outcome of AVF constructions.¹⁴ Spasm of the radial artery generated peri- and postoperatively is thus thought to be greatly involved in success of AVF.

An interesting finding in Study I was that EFI represents an independent correlate of the incidence of vasospasm in multivariate analysis. Some pharmacological agents have been evaluated for the ability to increase blood flow through the AVF in the early postoperative period. For example, prostaglandin E1 is useful for preventing arterial vasospasm.¹⁵ However, cost-performance evaluation is unlikely to look favorably on this method. Papaverine and phenoxybenzamine are other arterial vasodilators that can be used to protect against vasospastic decreases in blood flow during the early postoperative period.¹⁶ Intravenous nicardipine administration to decrease radial artery spasm may have some beneficial effects, but can also cause serious hypotension.⁵ GTN represents a superior vasodilator, and is more effective in preventing vasospasm than Diltiazem according

to recent evidence.¹⁷ In addition, GTN displays antiaggregation effects that are of benefit in access surgery.

In this study, frequency of vasospasm diminished to 28.6% (12/42) from 47.6% (20/42) using transdermal GTN in patients undergoing AVF construction. The results show that transdermal GTN is effective in preventing radial arterial spasm in the newly constructed AVF. Atherosclerotic cardiovascular disease is a significant cause of morbidity and mortality for patients with ERDS. Marked increases in coronary heart disease and death rates have been reported in hemodialysis patients compared to age-matched individuals from the general population, in addition to significant increases compared with non-uremic populations with hyperlipidemia and hypertension.¹⁷

Evidence exists that increases in IMT at the carotid artery are linked to risk factors such as hypertension, hyperlipidemia, diabetes mellitus, hemodynamic overload, anemia and increased oxidative stress.^{18,19} ERDS is undoubtedly associated with a higher prevalence of several traditional and uremia-related risk factors for atherogenesis. The introduction of high-resolution ultrasonography has provided a reliable, reproducible and non-invasive method for detecting and monitoring the progression of subclinical atherosclerosis. Transdermal GTN may be of great value as a prophylactic agent for use in preventing vasospasm after creating an AVF in patients with $IMT \leq 1.1$, but may be of little use for those with $IMT > 1.1$. If the degree of atherosclerosis is minor, spasm of the radial artery during AVF construction may be preventable using transdermal GTN. To the best of our knowledge, no previous studies have demonstrated any association between increased IMT of the CCA and spasm of the radial artery with a newly constructed AVF. Administration of transdermal GTN is practical and simple, and appears to be very safe, as no patients in the study reported any untoward effects. The biggest disadvantage of GTN is the development of tolerance. According to previous reports, vessels of the arm do not show the same level of tolerance as coronary vessels.²⁰ Although patients were excluded from the present study if continuous administration of nitrates had been used, patients under continuous administration of nitrates may be able to participate in such investigations. Moreover, spasm of the radial artery during AVF construction may be decreased in patients under continuous administration of nitrates.

In conclusion, measurement of IMT in the carotid artery may offer a useful, noninvasive screening method in patients to prevent radial arterial spasm in a newly constructed AVF. For patients with $IMT < 1.1$ mm, administration of transdermal GTN may prove particularly useful in preventing radial arterial spasm in AVF operations.

References

1. ClarkeBrescia M, Cimino J, Appel K, Hurwich B. Chronic hemodialysis using venipuncture and a surgically created arteriovenous fistula. *New Engl J Med* 275: 1089-1092, 1966
2. Angelini GD, Christie MI, Bryan M et al. Surgical preparation impairs release of endothelium-derived relaxing factor from human saphenous vein. *Ann Thorac Surg* 48: 417-420, 1989

3. Lin PJ, Pearson PJ, Schaff HV. Endothelium-dependent contraction and relaxation of the human and canine internal mammary artery: Studies on bypass graft vasospasm. *Surgery* 110: 127-135, 1991
4. Kuo J, Ramstead K, Salih V et al. Effect of vascular clamp on endothelial integrity of the internal mammary artery. *Ann Thorac Surg* 55: 923-926, 1993
5. Owada A, Saito H, Mochizuki T et al. Radial arterial spasm in uremic patients undergoing construction of arteriovenous hemodialysis fistulas: diagnosis and prophylaxis with intravenous nicardipine. *Nephron* 64: 501-504, 1993
6. Pignoli P, Tremoli E, Poli A et al. Intimal plus medial thickness of the arterial wall: A direct measurement with ultrasound imaging. *Circulation* 74: 1399-1406, 1986
7. Handa N, Matsumoto M, Maeda H et al. Ultrasonic evaluation of early carotid atherosclerosis. *Stroke* 21: 1567-1572, 1990
8. Suzuki M, Shinozaki K, Kanazawa A et al. Insulin resistance as an independent risk factor for carotid wall thickening. *Hypertension* 28: 593-598, 1996
9. He GW, Fan KY, Chiu SW et al. Injection of vasodilators into arterial grafts through cardiac catheter to relieve spasm. *Ann Thorac Surg* 69: 625-628, 2000
10. Coon AL, Colby GP, Mack WJ et al. Treatment of mechanically-induced vasospasm of the carotid artery in a primate using intra-arterial verapamil: a technical case report. *BMC Cardiovasc Disord* 21: 4-11, 2004
11. Safar ME, Peronneau PA, Levenson JA et al. Pulsed Doppler: diameter, blood flow velocity and volumic flow of the brachial artery in sustained essential hypertension. *Circulation* 63: 393-400, 1981
12. Kawamori R, Yamasaki Y, Matsushima H et al. Prevalence of carotid atherosclerosis in diabetic patients. Ultrasound high-resolution B-mode imaging on carotid arteries. *Diabetes Care* 15: 1290-1294, 1992
13. Anderson CB, Etheredge EE, Harter HR et al. Local blood flow characteristics of arteriovenous fistulas in the forearm for dialysis. *Surg Gynecol Obstet* 144: 531-533, 1977
14. Wong V, Ward R, Taylor J et al. Factors associated with early failure of arteriovenous fistulae for haemodialysis access. *Eur J Vasc Endovasc Surg* 12: 207-213, 1996
15. Owada A, Saito H, Nagai T et al. Prophylactic use of intravenous prostaglandin E1 for radial arterial spasm in uremic patients undergoing construction of arteriovenous hemodialysis fistulas. *Int J Artif Organs* 17: 511-514, 1994
16. Dipp MA, Nye PC, Taggart DP. Phenoxybenzamine is more effective and less harmful than papaverine in the prevention of radial artery vasospasm. *Cardiothorac Surg* 19: 482-486, 2001
17. Ma KW, Greene EL, Raij L. Cardiovascular risk factors in chronic renal failure and hemodialysis populations. *Am J Kidney Dis* 19: 505-513, 1992
18. Bots ML, Hofman A, Grobbee DE. Common carotid intima-media thickness and lower extremity arterial atherosclerosis. *Arterioscler Thromb* 14: 1885-1891, 1994
19. Hulthe J, Wikstrand J, Emanuelsson H et al. Atherosclerotic changes in the carotid artery bulb as measured by B-mode ultrasound are associated with the extent of coronary atherosclerosis. *Stroke* 8: 1189-1194, 1997
20. Cheesman AR, Benjamin N. Lack of tolerance in forearm blood vessels in man to glyceryl trinitrate. *Br J Clin Pharmacol* 37: 441-444, 1994