

## Carpal Tunnel Syndrome Caused by Scaphoid Non-Union

Takashi OKUBO, Kotaro IMAMURA<sup>†</sup>, Takehisa TSUNEOKA and Katsuro IWASAKI<sup>†</sup>

Department of Orthopaedic Surgery, Shimabara Onsen Hospital, NAGASAKI, JAPAN

<sup>†</sup> Department of Orthopaedic Surgery, Nagasaki University, School of Medicine, NAGASAKI, JAPAN

Correspondence: Dr. Kotaro Imamura

Department of Orthopaedic Surgery Nagasaki University, School of Medicine, 7-1 Sakamoto-machi, Nagasaki 852, Japan  
Telephone :0958-47-2111, Ext 2944      Telefax :0958-43-5991

**A 57-year-old male with carpal tunnel syndrome following the scaphoid non-union with dorsal intercalated segmental instability is described. It was considered that the dorsiflexed and palmarly dislocated lunate led the friction of the flexor tendons and tenosynovitis and resulted in carpal tunnel syndrome.**

### Introduction

Although any condition, which narrows the carpal tunnel, can be a contributory factor to the development of carpal tunnel syndrome (CTS), the most frequent cause is idiopathic synovitis.

In this paper, we present a case of CTS resulting from the scaphoid non-union with dorsiflexed intercalated segmental instability (DISI).

### Case report

A 57-year-old farmer noticed the paresthesia of the thumb, index, middle and ring finger of his right hand after repeated professional use of the hand in 1988. In November 1990, the paresthesia of his right hand became worse and a soft mass was noticed on the palmar aspect of the wrist. He visited our hospital on 14th January 1991. On physical examination, there was thenar muscle atrophy and sensory disturbance of the thumb, index, middle and ring finger of his right hand. Phalen's test was positive. Tinel's sign was positive over the entrance of the carpal tunnel. The soft mass was palpable on the palmar aspect of the right wrist with mild tenderness. The grasping power of his right hand was 30kg and that of his left hand was 40kg. The angle of palmar flexion of the right wrist was 50 degrees and that of dorsiflexion was 60 degrees.

In electromyographic study, the terminal latency of the right median nerve could not be measured because of non-response.

Radiographic examination revealed the psuedoarthrosis

of the scaphoid, which might have been caused by the striking of his right hand thirty years ago (Fig.1-a). The tomogram showed the existence of dorsal intercalated segmental instability (DISI), in which the radiolunate angle was 40 degrees dorsiflexed with slight palmar subluxation of the lunate (Fig.1-b). Surgical procedure was carried out on January 16, 1991. By releasing the carpal tunnel, significant tenosynovitis of the flexor

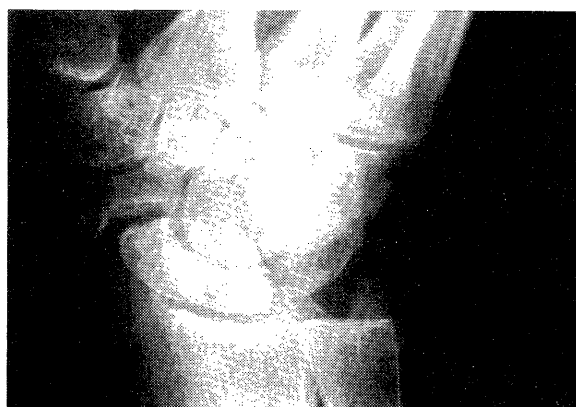

Fig.1-a ; Radiograph showing the established pseudoarthrosis of the scaphoid.

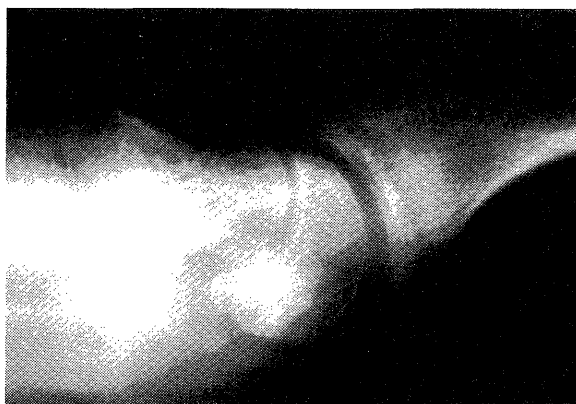
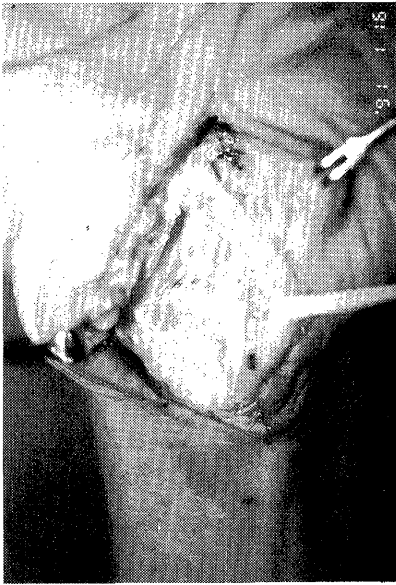
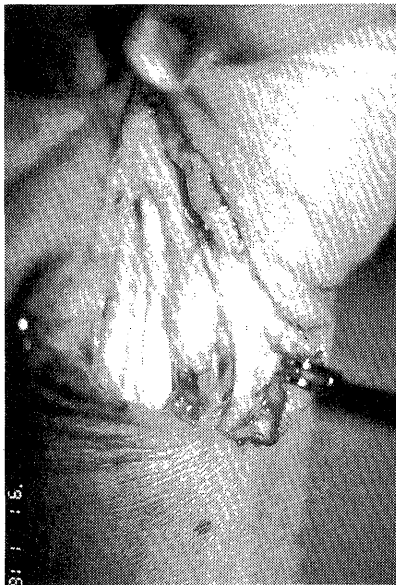

Fig.1-b ; The lateral view of the tomograph showing the existence of DISI deformity.

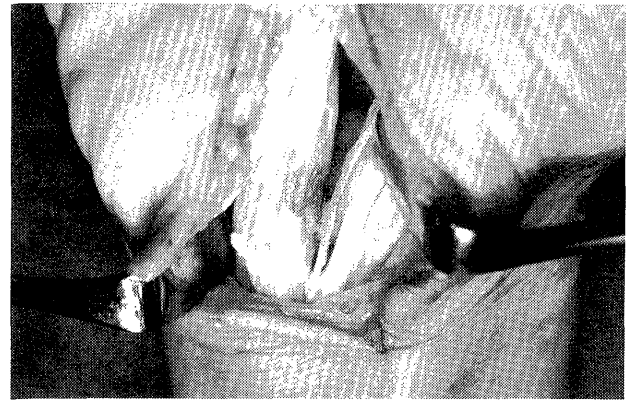


**Fig.2-a** ; There was significant synovitis of the flexor tendons within the carpal tunnel.

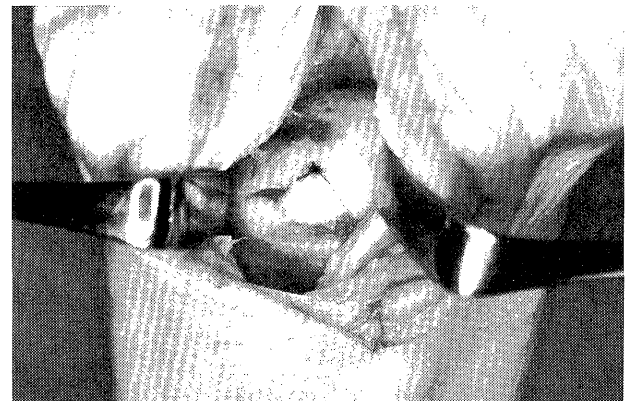

**Fig.2-b** ; Median nerve pressed at the mid-portion of the carpal tunnel.

tendons in the carpal tunnel was observed (Fig.2-a). In the central portion of the carpal tunnel, the median nerve was found flattened with redness and pseudoneuroma formation was seen at its proximal end (Fig.2-b). The soft mass which was palpated preoperatively on the palmar aspect of the wrist originated in hypertrophic synovium from tenosynovitis. The synovectomy revealed the narrowed and finely split flexor tendons (Fig.2-c). The lunate slid out just below the carpal tunnel with dorsiflexion and retreated into the place with the palmar flexion of the wrist (Fig.2-d). At this operation, only the release of the carpal tunnel and synovectomy were done because the



**Fig.2-c** ; The attrition of the flexor tendons.



**Fig.2-d** ; The lunate which slid out into the carpal tunnel.

patient was in a hurry to start his work. Five months after the operation, the paraesthesia of his hand disappeared, and the electromyographic study showed the improvement of the terminal latency of the median motor nerve to 7.0 msec.

The second operation was carried out on July 10, 1991. A displaced proximal fragment of the scaphoid and the lunate were reduced by pressing down dorsally and was fixed to the distal end of radius with the Kirschner wire for correcting the DISI deformity. The pseudoarthrosis of the scaphoid was treated by Kirschner wire fixation with corticocancellous bone grafting from the ilium (Fig.3-a). Four months after the second operation, bone union was achieved uneventfully (Fig.3-b). DISI deformity was improved with the lunate in 20 degrees dorsiflexion (Fig.3-c).

Seven months later, he had no pain or numbness in the wrist and hand. He was resuming his own work without any restriction. The palmar flexion angle of the right wrist was 45 degrees and the dorsiflexion was 70 degrees. The grasping power of the right hand was 25kg, and of the left hand 36kg. The atrophy of the thenar muscle was still present with slight improvement. Opposition and opposition of the thumb was complete. The terminal latency of median motor nerve was 6.4 msec.

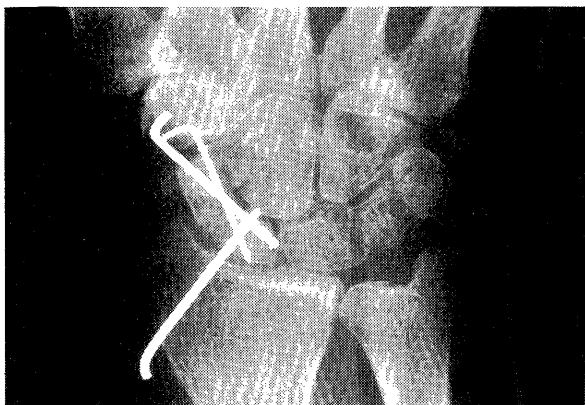


Fig.3-a ; Bone grafting from the ilium and Kirschner wire fixation were carried out.

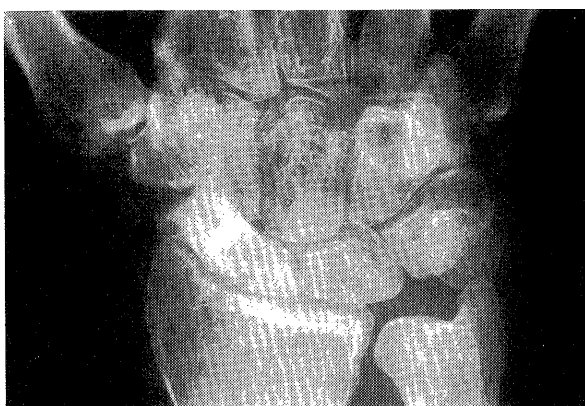


Fig.3-b ; Bone union was achieved four months after bone grafting.

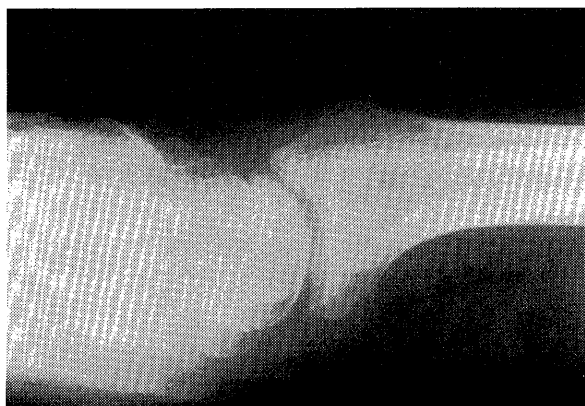

Fig.3-c ; Lateral view of radiograph revealed the improvement of DISI deformity with 20 degrees dorsiflexed lunare.

## Discussion

Laviet et al.(1984) reported two cases of CTS associated with ununited scaphoid fractures in which the upper end of the dorsiflexed lunate had bulged into the tunnel and had compressed median nerve. Graf et al.(1990) reported a case of the scaphoid non-union leading to an attrition rupture of flexor pollicis longus tendon, tenosynovitis and haemorrhage into the carpal tunnel causing recurrent symptoms of an acute CTS. In his case, the scaphoid pseudoarthrosis was exposed into the floor of the carpal tunnel but a large bony prominence projecting into the carpal tunnel could not be seen.

It is well known that the scaphoid non-union is accompanied with carpal instability (Mack et al., 1984; Black et al., 1987). In this case, the scaphoid fracture which might have occurred thirty years earlier resulted in the pseudoarthrosis and DISI deformity. Dorsiflexed lunate would cause the rupture of the palmar capsule and ligament because of the vigorous use as a farmer with his hand in a dorsiflexed position. Consequently, the palmarly dislocated lunate led the friction of the flexor tendons and tenosynovitis within the carpal tunnel and compressed the median nerve. In this case, it was considered that tenosynovitis might be a main cause of CTS.

In regard to the management of CTS combined with the scaphoid non-union, Laviet treated his two cases by division of the carpal ligament, neurolysis and partial resection of the lunate to restore the normal concavity of the carpus. Graf also carried out release of transverse carpal ligament, neurolysis and flattening of the edge of pseudoarthrosis. However, it might be reasonable to treat the pseudoarthrosis and DISI deformity in combination with the release of carpal tunnel and synovectomy to prevent recurrence of CTS.

## Reference

- Black, D.M., et al. Scapholunate gap with scaphoid nonunion. Clin. Orthop. 224: 205-209, 1987.
- Graf, P., et al. Akutes Karpaltunnelsyndrom und Ruptur der Sehne des M. flexor pollicis longus als seltene Komplikation einer Skaphoidpseudoarthrose. Handchir. -Mikrochir. -Plast-Chir. 22: 261-263, 1990.
- Laviet, D., et al. Syndrome du canal carpien et pseudoarthrose du scaphoide. A propose de deux cas. Rev-chir-Orthop. 70: 79-81, 1984.
- Mack, G.R., et al. The natural history of scaphoid non-union. J. Bone Joint Surg. 66-A: 504-509, 1984.