

Proliferating Cell Nuclear Antigen (PCNA), Nucleolar Organizer Regions (AgNORs), and Mitotic Indices in Nasopharyngeal Carcinoma

Masachika Senba, Xue-Yun Zhong and Hideyo Itakura

Department of Pathology, Institute of Tropical Medicine, Nagasaki University, 1-12-4 Sakamoto, Nagasaki 852 Japan

Proliferative activity of nasopharyngeal carcinoma (NPC) using 20 biopsy cases obtained from southern China were analyzed by immunolabelling with the monoclonal antibody of proliferating cell nuclear antigen (PCNA), the numbers of interphase silver stained nucleolar organizer regions (AgNORs), and mitotic indices. Nucleolar organizer regions (NORs) are loops of ribosomal DNA (rDNA) occurring in the nucleoli of cells, which transcribe to ribosomal RNA (rRNA) and ultimately direct ribosome and protein formation. PCNA is a nuclear protein synthesized in the nucleus late in G1 phase, peaking during S phase and subsiding during G2 and M phases of the cell cycle. These may indicate that PCNA and AgNORs are present at different stages of the cell cycle. The authors found that 28% of differentiated non-keratinizing carcinoma type of NPC and 18% of undifferentiated carcinoma type of NPC were positively stained by PCNA. The mean AgNOR counts for differentiated non-keratinizing carcinoma type of NPC, and undifferentiated carcinoma type of NPC were 1.8 and 1.2, respectively. The mean mitotic counts for differentiated non-keratinizing carcinoma type of NPC and undifferentiated carcinoma type of NPC were 3.4 and 2.1, respectively. Therefore, it is suggested that PCNA labelling immunoreactivity may be correlated with AgNORs score and mitotic indices, thus in NPC, these number and size have been regarded as markers of cell proliferative ability.

Introduction

Nasopharyngeal carcinoma (NPC) was first described as a neoplasm occurring in the nasopharynx, characterized by anaplastic cells surrounding prominent infiltration of lymphoid cells, and this tumor has been known as lymphoepithelioma. The nuclear features of the carcinoma cells are distinctive with large nuclear and prominent nucleolus. The cytoplasmic features of the carcinoma cells are variable, and the cellular borders are often indistinct due to fusion of cytoplasm. NPC has been confirmed to arise from squamous epithelium by electron microscopical and immunohistochemical examination. According to the World Health Organization (WHO) classification, NPC can be divided into three types as squamous cell carcinoma, differentiated

non-keratinizing carcinoma, and undifferentiated carcinoma.^{1,2)}

The Epstein-Barr virus (EBV) is associated with a variety of benign and malignant lymphoproliferative disorders, most notably infectious B-cell lymphoma and NPC. Malignant tumors primarily arising in the nasopharynx are most often carcinoma or malignant lymphoma. Undifferentiated NPC is accompanied by prominent lymphocytic infiltration, thus, it is often difficult to differentiate from malignant lymphomas, especially of the large-cell type. Although histochemical diagnosis of NPC has been difficult to differentiate from malignant lymphoma, immunohistochemical diagnosis of NPC may be distinguished from malignant lymphoma.^{6, 11, 13, 17)}

Proliferating cell nuclear antigen (PCNA) was discovered by Miyachi and co-workers⁴⁾ by the use of autoantibodies in the sera of patients with systemic lupus erythematosus (SLE). A relationship between the PCNA value and other cell proliferative activity has been reported by many investigators.^{2, 3, 7, 15, 16, 18)} Thus, the proportion of tumor cells with nuclear positivity for PCNA, the quantity of interphase nucleolar organizer regions (NORs),^{1, 5, 8-10, 14)} and mitotic indices are linearly related. In this study, we examined to assess proliferative activity in differentiated non-keratinizing carcinoma type of NPC and undifferentiated carcinoma type of NPC, using following techniques; (1) fraction of immunoreactive for PCNA, (2) evaluation of AgNORs, (3) mitotic counting.

Materials and Methods

The NPC specimens from 20 biopsy cases at the Jinan University Hospital in southern China were used. Shanmugaratnam and Sobin criteria were applied in assigning the diagnosis of NPC to the tissue. These NPC cases were divided into two groups as follows: (1) differentiated non-keratinizing carcinoma, and (2) undifferentiated carcinoma. The materials were fixed in 10% formalin, and embedded in paraffin for histochemical and immunohistochemical studies. Sections were cut at 4 micron and stained with hematoxylin and eosin stain for histological examination.

Correspondence to: Dr. Masachika Senba, Department of Pathology, Institute Tropical Medicine, Nagasaki University, 1-12-4 Sakamoto, Nagasaki 852, Japan

Anti-PCNA immunostaining

The number of PCNA positive nuclei in 100 nuclei per structural component of differentiated non-keratinizing carcinoma type of specimens were stained by indirect peroxidase-antiperoxidase (PAP) method for PCNA (Dako corp., U. S. A., No. 879; Lot. 121). This antibody was diluted 1:50 with PBS pH 7.4. The indirect PAP method was performed for the staining of PCNA using Dako Universal kit for monoclonal antibody (Dako corp., PAP kit K550, Lot. 072-6).

The steps involved in the immunoperoxidase procedure are the following: (1) Deparaffinize and hydrate in distilled water. (2) Treat with hydrogen peroxidase for 5 minutes. (3) Wash in Tris buffer pH 7.4 using three cycle changes of 3 minutes each. (4) Treat with normal serum for 20 minutes. (5) Treat with blot excess normal serum from sections. (6) Treat with primary antibody for 3 hours in room temperature. (7) Wash in Tris buffer pH 7.4 using three cycle changes of 5 minutes. (8) Treat with second antibody for 40 minutes in room temperature. (9) Wash in Tris buffer pH 7.4 using three cycle changes of 5 minutes. (10) Treat with PAP for 40 minutes in room temperature. (11) Wash in Tris buffer pH 7.4 using three cycle changes of 5 minutes. (12) Treat with 3, 3-diaminobenzidine tetrahydrochloride (DAB) solution with hydrogen peroxidase for 5 minutes. (13) Wash in running water. (14) Nuclei stain in Mayer's hematoxylin for 2 minutes. (15) Wash in running water. (16) Dehydrate, clear, and mount.

AgNOR staining

To assess the proliferative activity of these lesions, one-step silver colloid for NOR was applied and the number of AgNOR dots in 100 nuclei per structural component of differentiated non-keratinizing carcinoma type of NPC and undifferentiated carcinoma type of NPC were counted. The AgNORs method was modified as follows: (1) Deparaffinize and hydrate in distilled water. (2) Treat with AgNORs solution for 30 minutes at 37 °C incubator. AgNORs solution: One volume of 2% gelatin in 1% formic acid solution and two volume of 50% silver nitrate solution was mixed before using. (3) Wash in warm water using three cycle changes. (4) Treat with 0.2% gold chloride solution for 5 minutes. (5) Wash in running water. (6) Dehydrate, clear, and mount. No counterstain was used.

Mitotic counting

The tissue sections were stained with hematoxylin and eosin. Mitotic counting was performed in 100 nuclei per structural component of differentiated non-keratinizing carcinoma type of NPC and undifferentiated carcinoma type of NPC.

Results

Immunostaining for PCNA yielded distinct nuclear labeling which was easy to count. The fraction of PCNA immunoreactivity was widely distributed in the NPC tissues. By PCNA immunohistochemistry, 28% of differentiated non-keratinizing carcinoma type of NPC (Fig. 1) and 18% of undifferentiated carcinoma type of NPC (Fig. 2) were positively reacted. In all specimens AgNORs were clearly visible as black dots of varying size in the nuclei. These were arranged into one or more clusters. Most of the AgNOR dots in differentiated non-keratinizing carcinoma type of NPC and undifferentiated carcinoma type of NPC were small and round in shape. The AgNOR dot-size in undifferentiated carcinoma type of NPC was larger than differentiated non-keratinizing carcinoma type of NPC. The mean AgNOR counts for differentiated non-keratinizing carcinoma type of NPC (Fig. 3) and undifferentiated carcinoma (Fig. 4) were 1.8 and 1.2, respectively. The mean mitotic counts for differentiated non-keratinizing

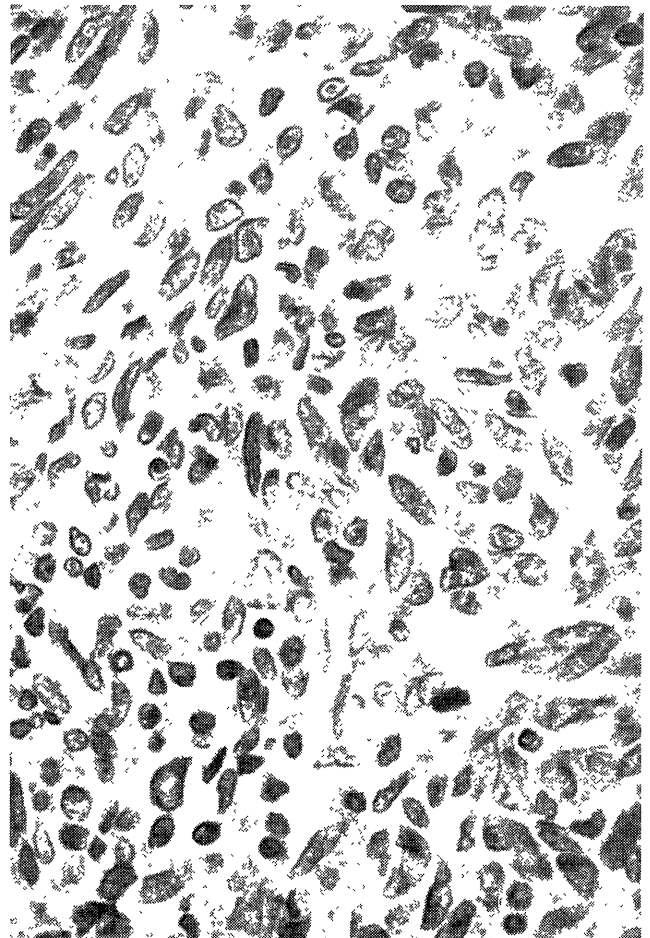


Fig. 1. PCNA positive nuclei are seen in differentiated non-keratinizing carcinoma tissue of nasopharynx. Immunoreactivity for PCNA, X 400.

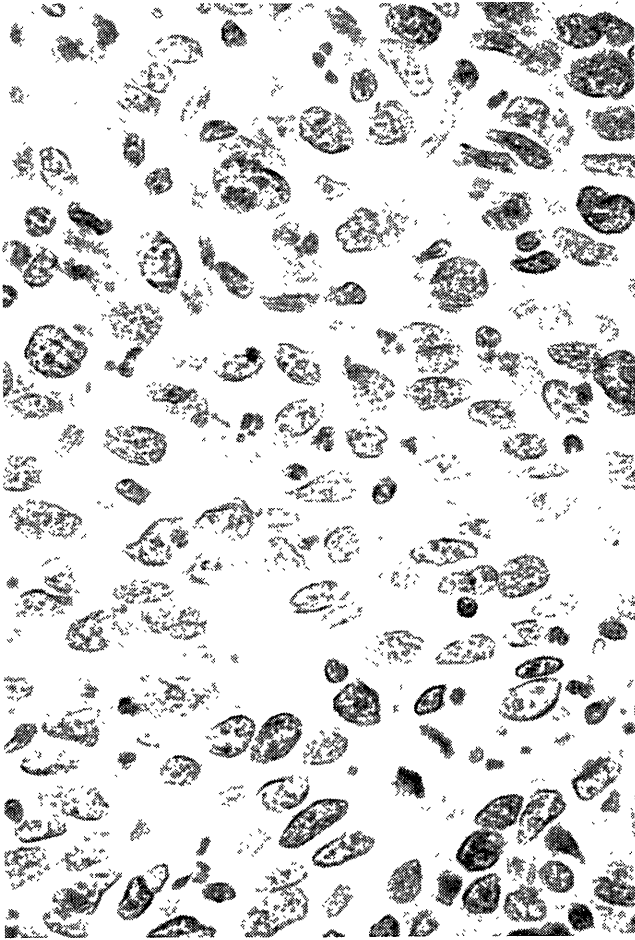


Fig. 2. PCNA positive nuclei are detected in undifferentiated carcinoma tissue of nasopharynx. Immunoreactivity for PCNA, X 400.

carcinoma type of NPC and undifferentiated carcinoma type of NPC were 3.4 and 2.1, respectively (Figs. 5 and 6). Therefore, differentiated non-keratinizing carcinoma type of NPC had a higher AgNOR scores than undifferentiated type of NPC. The mitotic indices correlated with both ratios of PCNA fraction and the number of AgNOR dots count.




Fig. 3. Silver-stained for AgNOR proteins are shown non-keratinizing carcinoma tissue of nasopharynx. The tumor nuclei accumulated one to five AgNOR dots. X 400.

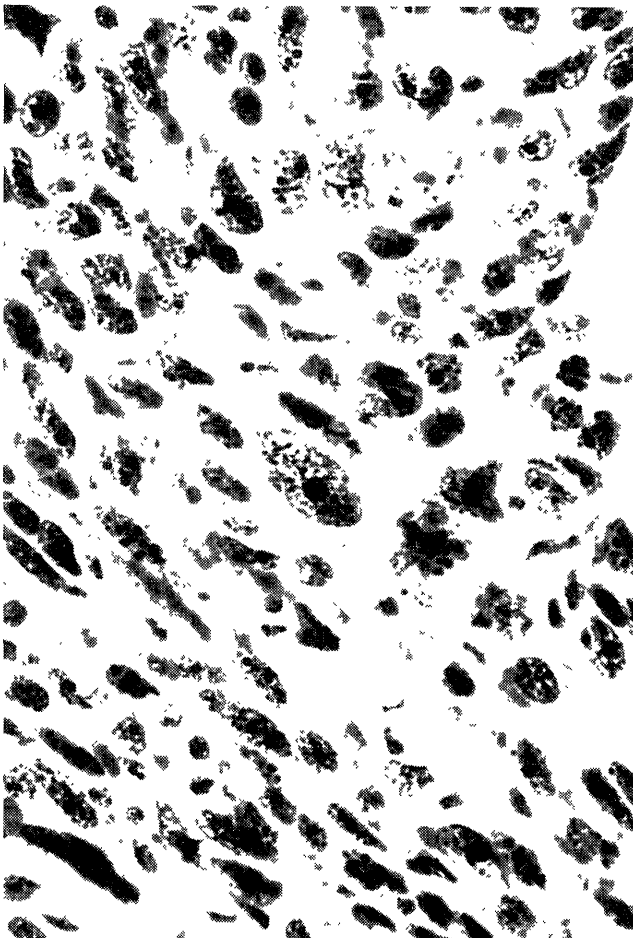


Fig. 4. Silver-stained for AgNOR proteins are observed in undifferentiated carcinoma tissue of nasopharynx. Most of the neoplastic nuclei contained one AgNOR dots. X 400.

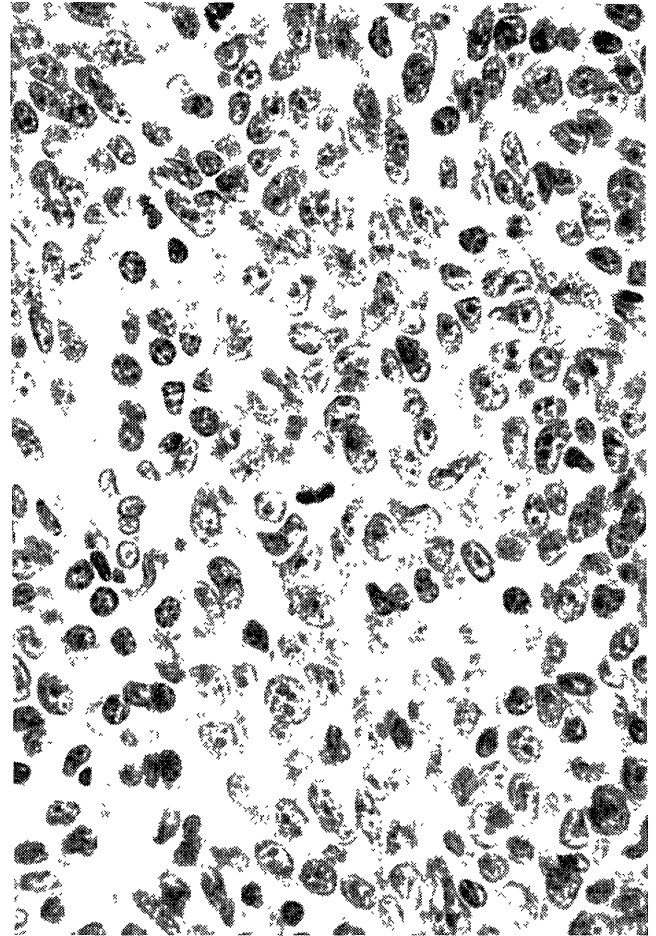


Fig. 5. Mitosis are seen in differentiated non-keratinizing carcinoma tissue of nasopharynx. Hematoxylin-and eosin stain, X 400.

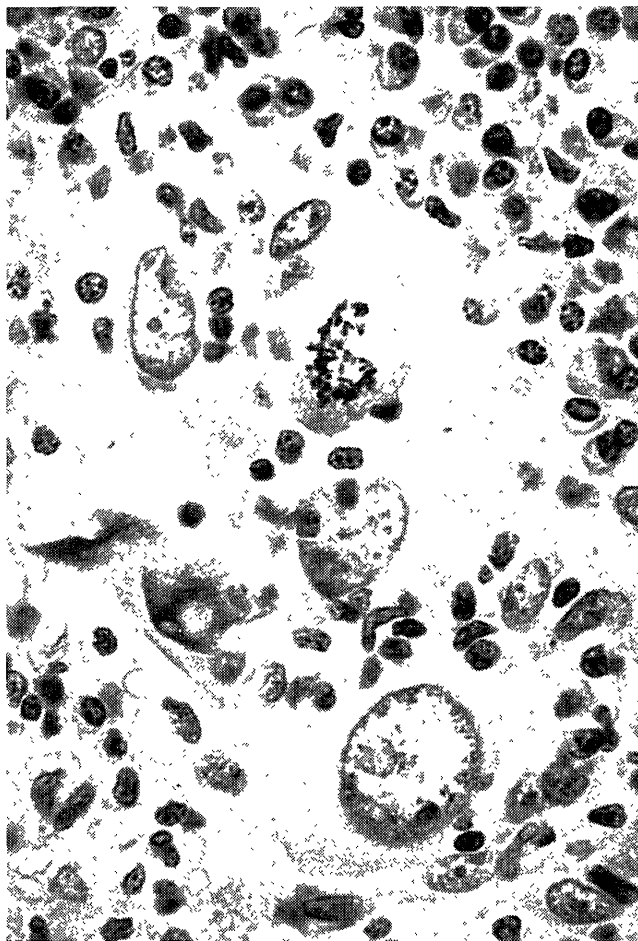


Fig. 6. Mitosis are detected in undifferentiated carcinoma tissue of nasopharynx. Hematoxylin-and-eosin stain, X 400.

Discussion

One of the aims in diagnostic surgical pathology is the identification of morphological markers for malignant transformation, and the nucleus and the nucleolus are studied in this field. Immunohistochemical detection of cell cycle related markers for estimation of tumor growth fractions using paraffin embedded tissue sections would have applications in clinical pathology as an in situ histological alternative to flow cytometry.³⁾ DNA replication, chromosome condition, and mitosis can be useful markers for cellular growth and division. We investigated PCNA, AgNORs, and mitotic indices for proliferative activity in NPC obtained from southern China using immunohistochemical and histochemical procedures. There was a correlation among PCNA fraction, AgNOR count, and mitotic indices.

Proliferating cell nuclear antigen (PCNA) was originally detected by Miyachi and co-workers⁴⁾ during experiments with autoantibodies in the sera from patients with SLE which reacted with nuclei of proliferating cells in normal

human tissues. DNA synthesis and rate of cellular proliferation have been found to be important factors in human malignancy. This study shows that monoclonal antibody PCNA is a valuable marker for proliferating cells in formalin-fixed and paraffin-embedded tissues. The distribution of PCNA in the cell cycle increases through G1, peak at the G1/S phase interphase and decreases through G2 phase reaching levels which are virtually undetectable in M phase and in quiescent cell using immunohistochemical method.¹⁵⁾ The human PCNA gene has 261 amino acid polypeptide with a high content of aspartate and glutamic acid. In most autopsy specimens PCNA immunoreactivity was markedly diminished as compared with similar surgical specimens. This indicates that PCNA is stable under conditions routinely encountered in diagnostic surgical pathology and facilitates its potential use as a diagnostic proliferation marker.^{2,3,7,15,16,18)} High fractions of PCNA immunolabelling combined with low mitotic indices were observed in NPC.

The AgNOR proteins are defined as markers of "active" ribosomal genes.⁹⁾ In cycling cells, the quantity of AgNOR proteins increases progressively during the G1 phase. The synthesis of AgNOR proteins during G1 is associated with ribosomal chromatin dispersion. These argyrophilic proteins are specifically related to NORs, which are loops of ribosomal DNA (rDNA) that transcribe for ribosomal nucleic acid (rRNA) and are involved in the synthesis of the site of 18S and 28S rRNA.¹⁰⁾ AgNOR proteins are detected by a specific silver staining procedure based on the ability of such proteins to reduce silver under acidic conditions. Their size and number might reflect cell proliferation and malignant transformation. A simple silver colloid staining method for NORs has been applied to paraffin sections of tumors in studies of oncogenesis. Many investigators have reported that enumeration of AgNORs is useful for histological diagnosis between benign and malignant tumors, because the number and distribution pattern of AgNORs can be easily detected by light microscopy in paraffin embedded tissues.^{1,5,8,10,14)} This study assessed the value of AgNOR staining as a potential technique for the estimation of cell kinetics in conventional histological sections in NPC. Finally, in further investigations, we would like to know relationship between prognosis of NPC and markers for the activity of cell proliferation.

References

- 1) Dervan P, Gilmartin LG, Loftus BM, Carney DN Breast carcinoma kinetics. Argyrophilic nucleolar organizer region counts correlate with Ki67 scores *Am J Clin Pathol.*, 92 401-407, 1989
- 2) Dierendonck JH, Wijsman JH, Keijzer R, Velde CJH, Cornelisse CJ Cell-cycle-related staining patterns of anti-proliferating cell nuclear antigen monoclonal antibodies. Comparison with BrdUrd labeling and Ki-67 staining *Am J Pathol.*, 138 1165-1172, 1991
- 3) Gelb A, Kamel OW, LeBrun DP, Warnke RA Estimation of tumor growth fractions in archival formalin-fixed, paraffin-embedded tissues

- using two anti-PCNA/cyclin monoclonal antibodies: Factors affecting reactivity. *Am. J. Pathol.*, 141:1453-1458, 1992.
- 4) Miyachi K, fritzler MY, Tan EM: Autoantibody to nuclear antigen in proliferating cells. *J. Immunol.*, 12:2228-2234, 1987.
 - 5) Niwa K, Yokoyama Y, Furui T, Tanaka T, Mori H, Mori H, Tamaya T: Changes of silver-stained nucleolar organizer regions in mouse endometrial carcinogenesis induced by N-methyl-N-nitrosourea and 17 β -oestradiol. *Virchows Arch. A*, 421:387-391, 1992.
 - 6) Nomori H, Kameya T, Shimosato Y, Saito H, Ebihara S, Ono I: Nasopharyngeal carcinoma: Immunohistochemical study for keratin, secondary component and leukocyte common antigen. *Jpn. J. Clin. Oncol.*, 15:95-105, 1985.
 - 7) Penneys N, Bogaert M, Serfling U, Sisto M: PCNA expression in cutaneous keratinous neoplasms and verruca vulgaris. *Am. J. Pathol.*, 141:139-142, 1992.
 - 8) Roussel P, Belenguer P, Amalric F, Hernandez-Verdun D: Nucleolin is an AgNOR protein: This property is determined by its amino-terminal domain independently of its phosphorylation state. *Exp. Cell Res.*, 203:259-269, 1992.
 - 9) Rüschoff J, Plate K, Bittinger A, Thomas C: Nucleolar Organizer Regions (NORs): Basic concepts and practical application in tumor pathology. *Pathol. Res. Pract.*, 185:878-885, 1989.
 - 10) Scucchi L, Silecchia G, Stefano DD, Spaziani E, Polimeno L, Materia A, Mingazzini PL, Basso N, Marinozzi V: Interphasic nucleolar organizer regions expression and cell kinetics evaluation during gastric carcinogenesis induced by nitrosoguanidine in the rat. *Virchows Arch. B*, 62:303-309, 1992.
 - 11) Senba M, Zhong XY, Itakura H: Immunohistochemical investigation of nasopharyngeal carcinoma using keratin, EMA, laminin, fibronectin, collagen type IV, laminin receptor, and laminin/collagen receptor antibodies. *Acta Med Nagasaki.*, (in press)
 - 12) Shanmugaratnam K, Sobin LH: Histological typing of upper respiratory tract and ear: WHO international histological classification of tumors. 2nd Ed. Berlin, Springer-Verlag, 1991.
 - 13) Sugimoto T, Hashimoto H, Enjouji M: Nasopharyngeal carcinoma and malignant lymphomas: An immunohistochemical analysis of 74 cases. *Laryngoscope*, 100:742-748, 1990.
 - 14) Trerè D, Farabegoli F, Cancellieri A, Ceccarelli C, Eused V, Derenzine M: AgNOR area in interphase nuclei of human tumors correlates with the proliferative activity evaluated by bromodeoxyuridine labeling and Ki-67 immunostaining. *J. Pathol.*, 165:53-59, 1991.
 - 15) Tsuji T, Shrestha P, Yamada K, Takagi H, Shinozaki F, Sasaki K, Maeda K, Mori M: Proliferating cell nuclear antigen in malignant and pre-malignant lesions of epithelia origin in the oral cavity and the skin: An immunohistochemical study. *Virchows Arch. A*, 420:377-383, 1992.
 - 16) Wolf HK, Dittrich KL: Detection of proliferating cell nuclear antigen in diagnostic histopathology. *J. Histochem. Cytochem.*, 40:1269-1273, 1992.
 - 17) Zhong XY, Senba M, Gu JN, Itakura H: B-cell antigen marker expression on the nasopharyngeal carcinoma. *Zentralbl. Pathol.*, (in press)
 - 18) Zimmer C, Gottschalk J, Cervos-Navarro J: Proliferating cell nuclear antigen (PCNA) in atypical and malignant meningiomas. *Pathol. Res. Pract.*, 188:951-958, 1992.