

The Properties of An Immature Glial Cell Line (HITS Glioma) Derived from Ethylnitrosourea (ENU)-Induced Rat Glioma

Yuji Ikeno

The First Department of Pathology, Nagasaki University School of Medicine, 1-12-4 Sakamoto, Nagasaki 852, Japan

In order to evaluate the proliferation and differentiation potentials of ethylnitrosourea (ENU)-induced glioma cells, the author attempted to obtain a cell line that maintains glial features in long term culture. One of five cell lines cultivated from ENU-induced rat gliomas deserved particular interest because of the differentiation of the neoplastic glia. This cell line, designated as HITS glioma, had a polygonal cell body and formed a monolayer with pile-up foci *in vitro*, in contrast to the other cell lines, which showed a mesenchymal drift through passages. GFAP-positive cells, found in the primary culture, disappeared in the late passages of HITS glioma as they did in the other cell lines. Galactocerebroside (GC) and GD3 ganglioside were not expressed in the cell lines during culture. Subcutaneous inoculation of HITS glioma into neonatal rats induced tumors with various histopathological components mimicking the histopathological appearance of ENU-induced gliomas. The components also had a fraction of GFAP-positive cells. These findings indicate that HITS glioma cells may be composed of immature glial cells and differentiate into astrocytic cells under certain conditions. Insulin-like growth factor I (IGF-I), which promoted the proliferation of GFAP-positive cells in neonatal glia, was used to evaluate the mechanism(s) of proliferation and/or differentiation of HITS glioma. IGF-I did not induce the expression of GFAP in HITS glioma, even though it promoted the proliferation of HITS glioma. Although the mechanism involving the astrocytic differentiation of HITS glioma is unknown, HITS glioma may serve as a research tool in evaluating the mechanisms of proliferation and differentiation of neoplastic glia.

Key Words: Ethylnitrosourea-Glioma-Cell line-GFAP

Introduction

Ethylnitrosourea(ENU)-induced gliomas in the rat⁵⁾ are histopathologically similar to oligodendroglioma, mixed oligo-astrocytoma, astrocytoma, and anaplastic glioma in humans,¹⁷⁾ and have been utilized extensively as an experimental model of human gliomas. Many investigators have

been intrigued by the polymorphic phenotype of this tumor model, which may indicate the existence of pluripotent neoplastic glia and provide a way to investigate the differentiation of normal as well as neoplastic glia. However, there is still some controversy about this model. Reactive astrocytes, which appear within and around gliomas during the neoplastic process, complicated *in vivo* studies. Mauro *et al.*¹⁹⁾ and Shimokawa³⁴⁾ indicated that most, if not all, GFAP-positive cells within tumors could be reactive cells, while other investigators^{29, 37, 38)} considered them neoplastic cells. In our laboratory, Higami suggested the reactive nature of GFAP-positive cells in the glioma using primary culture cells.¹²⁾ However, the possibility remained that GFAP-negative neoplastic glia differentiate into astrocytic cells under certain conditions. A cell line, derived from ENU-induced glioma, has expressed GFAP in a fraction of cells.¹⁶⁾ The author have also cultured a cell line which expressed GFAP, not *in vitro* but only in transplanted sites of neonatal rats. In this report, the author take up the task of characterizing this cell line, designated as HITS glioma.

Recent advances in oncology have revealed the significant role of growth factors or oncogenes in the development of neoplasms.^{31, 32)} Insulin-like growth factor I (IGF-I), which is increased in the serum of animals at the onset of puberty,³⁹⁾ regulates the proliferation and differentiation of normal and neoplastic glia.^{22, 23, 24, 30)} The response of HITS glioma to IGF-I was examined to elucidate the mechanism(s) of cell proliferation and GFAP-expression in cells after transplantation.

Materials and Methods

Experimental Animals and Tumor Induction

Glioma induction was conducted according to the method of Koestner *et al.*¹⁷⁾ Briefly, pregnant Wistar rats on the 15th day of gestation received an intravenous injection of a single 50mg/kg body weight dose of N-ethyl-N-nitrosourea (ENU, Nakarai Chemical, Ltd., Kyoto, Japan) dissolved in distilled water. After delivery, the offspring were fed *ad libitum* for 6-9 months and sacrificed under ether anes-

Corresponding Author: Name: Yuji Ikeno
Mailing Address: The First Department of Pathology,
Nagasaki University School of Medicine, 1-12-4
Sakamoto, Nagasaki 852, Japan
Phone: 0958-47-2111 Ext. 2192
FAX: 0958-47-8514

thesia when neurological symptoms appeared. Neonatal rats were used as controls and sacrificed on the day of birth.

Cell Culture

A half portion of macroscopic glioma or the cerebral hemisphere of neonatal rats was minced and digested with 0.25% trypsin (GIBCO, U.S.A.) at 37 °C for 15min. Isolated cells were suspended in Eagle's Minimum Essential Medium (MEM, GIBCO) supplemented with 10% fetal bovine serum (FBS, GIBCO) and antibiotics (10 units/ml penicillin G sodium, 10 µg/ml streptomycin sulfate, 0.025 µg/ml amphotericin B, GIBCO), and incubated at 37 °C in 55cm² petri dishes in a 5% humidified atmosphere. In the glioma-derived cell cultures, passages were performed when the culture dishes became confluent. Cells were washed with Ca⁺⁺, Mg⁺⁺-free phosphate buffered saline (CMF-PBS), detached from the dishes with 0.05% trypsin/0.02% EDTA-PBS solution and inoculated into new culture dishes. The splitting ratio was 1:4. At the same time, a portion of the subcultivated cells was inoculated onto a cover slip sheeted into new dishes and grown for a day for immunocytochemical examination.

Subcutaneous Inoculation of Cultured Cells

HITS glioma and one other cell line (RT1005)-1 × 10⁶ cells in 0.5ml phosphate buffered saline (PBS)-were subcutaneously inoculated into 1-day-old neonatal rats. The tumors were harvested at a 3.0-4.0cm diameter. Each tumor was dissected free of connective tissue, fixed, and processed for hematoxylin-eosin and immunohistochemical examination.

Tissue Preparation for Histological and Immunohistochemical Examination

A portion of the original gliomas and transplanted tumors was fixed in 4% paraformaldehyde/0.1M PB at 4 °C overnight. After fixation, the specimens were dehydrated, embedded in paraffin and cut into 5 µm thick serial sections. Another portion of the specimens was cut in 2mm thick slices, placed in O. C. T. compound (Miles, U.S.A.) and quickly frozen in ethanol cooled by dry ice to -80 °C. The specimens were cut into 5 µm sections on a cryostat and fixed for 10min. with cold acetone. The serial sections were mounted on glass slides coated with poly-L-lysine (Sigma, Deisenhofen, FRG), and stained with hematoxylin-eosin or used for immunohistochemical examination.

Immunostaining

The primary antibodies used in this study and their optimal dilutions were as follows: Rabbit anti-cow GFAP (glial fibrillary acidic protein, 1:800, DAKO, Denmark), Rabbit

anti-bovine galactocerebroside (1:200, Chemicon International, Inc., California, U.S.A.), Rabbit anti-human MBP (Myelin basic protein, 1:200, DAKO), Mouse anti-GD3 ganglioside (1:1600, Dr. A. Houghton, Sloan Kettering Memorial Institute, New York, U.S.A.). Galactocerebroside (GC) was used as an oligodendrocytic marker in vitro for frozen sections, since MBP displayed a frequent non-specific staining in culture cells. The avidin-biotin peroxidase complex (ABC) method¹³⁾ was applied to demonstrate GFAP, MBP, GC and GD3 on tissue specimens and cultured cells. Commercial reagents were used (VECTASTAIN, VECTOR LABORATORIES, California, U.S.A.). Negative controls included replacement of the primary antibodies with normal rabbit serum (1:200-1600, DAKO). The immunoreactivity to rat positive control specimen of these primary antibodies was determined before use.

In the immunocytochemical analysis, GFAP-, GC-, and GD3- positive rates were calculated by counting more than 500 cells on a cover slip.

Bromodeoxyulidine (BrdU) Incorporation and Immunostaining

BrdU incorporation was performed to examine the proliferative activity of cultured cells,⁹⁾ using an Amersham cell proliferation kit (Amersham, England). Culture cells grown on cover slips were incubated with the labelling medium containing BrdU (5-bromo-2'-deoxyuridine, BrdU;1:1000 dilution ratio) for 1 hour, and fixed in 4% paraformaldehyde for 20min. The indirect method was used for immunocytochemical visualization of BrdU incorporated cells. Cells were counterstained with hematoxylin. All steps were performed at room temperature. The BrdU incorporation rates were calculated by counting more than 500 cells on a cover slip.

Response of HITS Cells to Insulin-Like Growth Factor-I (IGF-I) in vitro

To elucidate mechanisms of cell proliferation and differentiation, the response to IGF-I was assessed by measuring the increased cell number, BrdU incorporation and GFAP-, GC-, GD3-expression in HITS glioma in vitro. To measure the increased cell number, 2 × 10⁴ cells were inoculated in 21cm² culture dishes with MEM + 10% FBS. The following day, the culture medium was replaced by the following culture mediums; (a) MEM + 10% FBS, (b) MEM + 0.1% FBS + Insulin-like growth factor-I (IGF-I, Collaborative Research, Inc., U. S. A.) in 10, 100, 200ng/ml amounts, (C) MEM + 0.1% FBS. Each culture medium was replaced by fresh medium on the 4th day, and the cells were harvested on the 7th day and counted using a hemocytometer.

To measure the effect of IGF-I on BrdU incorporation and GFAP-, GC-, GD3-expression, 5 × 10³ cells inoculated onto a cover slip were cultivated under the same condi-

tions. These cells were cultured for 12 hours in the experimental media. BrdU incorporation was performed for the last 1 hour of the culture, as previously described, and immunostaining was also performed. GFAP-, GC- and GD3-expression were observed on the 7th day of culture in the experimental media. The data were estimated by t-test ($P < 0.05$).

Transmission Electron Microscopic Examination

For transmission electron microscopy, the cells were fixed with 2.5% glutaraldehyde and postfixed with 1% osmium tetroxide in situ. Fixed cells were dehydrated, embedded in Epon-Araldite resin, sectioned with an ultramicrotome and observed with a JEM-1200EX (JEOL) transmission electron microscope.

Results

Original Gliomas

The five ENU-induced gliomas, from which cell lines in this study were derived, were basically oligodendrogliomas (Fig. 1). One contained a sarcomatous focus. Astrocytic (GFAP-positive) cells were scattered in and around the tumors (Fig. 2). Neither GFAP, GC nor MBP was detected in the oligodendroglioma cells.

Culture Cells

During passages, four of five cell lines showed mesenchymal drift developing spindle-shaped cells and losing glial features, morphologically. However, the HITS glioma possessed a polygonal cell body and a relatively small nucleus (Fig. 3), grew in a monolayer and formed pile-up foci after 30 days of culture (6th passage, Fig. 3). HITS glioma have been continuously cultivated for more than 300 days (over 50 passages) and still maintain these features.

Fig. 4 shows changes in the proportion of GFAP-positive, BrdU-incorporated cells in each cell line. Although approximately 10% of cultured cells expressed GFAP in the early passage of each cell line, the GFAP-positive cells decreased in proportion and finally disappeared. The proportion of BrdU-incorporated cells was within the range of approximately 10-15% in each cell line. There were no positive cells for GC and GD3 in any of the cell lines.

Subcutaneous Inoculation of HITS Glioma and RT1005 Cells

Subcutaneous inoculation of each cell line yielded tumors in all recipient rats. These tumors reached diameters of

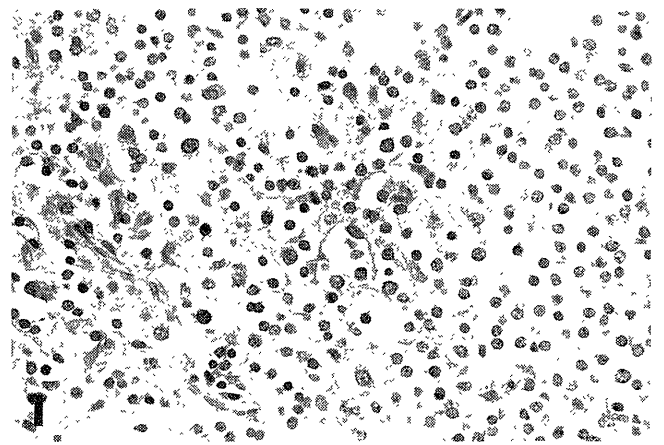


Fig. 1. Light microscopy of an ENU-induced rat glioma. The tumor cells show slight pleomorphism and a typical honeycomb pattern. (H & E, x 400).

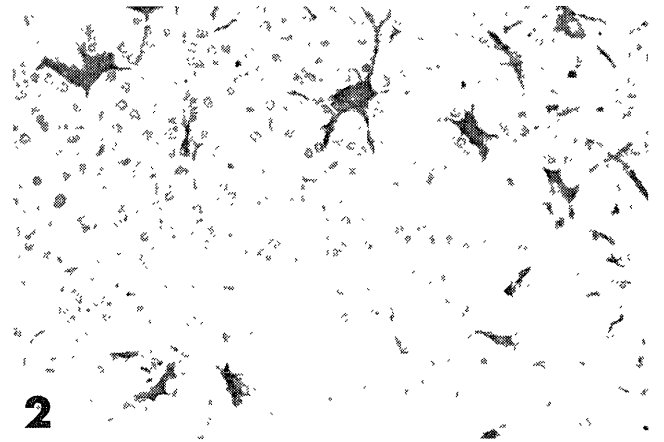


Fig. 2. Light microscopy of an ENU-induced rat glioma. GFAP positive cells are located within and around the tumor. (GFAP, x 600).

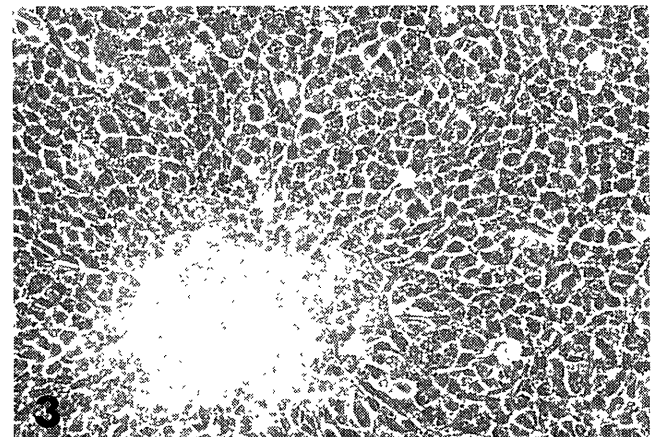


Fig. 3. Cultured cells obtained from an ENU-induced rat glioma (HITS glioma) showing pile-up focus. (phase contrast x 400)

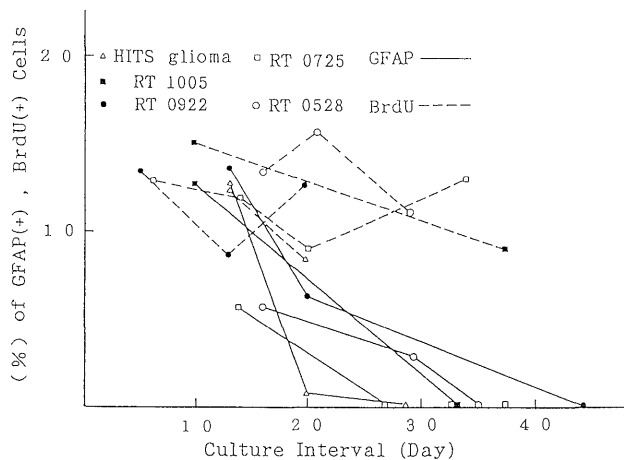


Fig. 4. The proportion of GFAP-positive, BrdU-incorporated cells in each cell line. Although approximately 10% of cultured cells expressed GFAP in the early passage of each cell line, the GFAP-positive cells decreased in proportion and finally disappeared.

3-4cm, 2-8 weeks after inoculation. They were solid, white colored, soft tumors with gelatinous appearance and cystic change (Fig. 5). The tumors derived from HITS glioma consisted of oligodendroglioma (Fig. 6a) and anaplastic glioma (Fig. 6b). The tumors also contained a variety of minor components including sarcomatous (Fig. 6c), ependymomatous (Fig. 6d), astrocytoma-like foci (Fig. 6e), and perivascular proliferation (Fig. 6f). Immunostaining revealed GFAP-positive cells in all areas despite differing histopathology (Fig. 7 a-f), although no isomorphic proliferation of GFAP-positive cells was observed. MBP, GC and GD3 were not detected in any area of these tumors.

Subcutaneous tumors derived from RT1005 cells showed only a sarcomatous appearance (Fig. 8). No GFAP- or MBP- positive cells were found.

Response of HITS Glioma to IGF-I in vitro

(1) Cell Proliferation: *Cell Number*

The effect of IGF-I (10, 100 and 200 ng/ml) on the proliferation of HITS glioma is shown in Tables 1 and 2. In the medium supplemented with 0.1% FBS, IGF-I induced a significant increase in the cell number of both neoplastic and neonatal glia, compared with controls (0.1% FBS alone).

(2) Cell Proliferation: *BrdU Incorporation*

The effect of IGF-I (10, 100 and 200ng/ml) on BrdU incorporation by the cultured tumor cells is shown in Table 2. In 0.1% FBS supplemented medium, IGF-I induced BrdU incorporation of both neoplastic and neonatal glia, compared with controls (0.1% FBS alone). IGF-I stimulated BrdU incorporation in a dose-dependent fashion in both neonatal and neoplastic glial cultures.




Fig. 5. Transplanted tumor of HITS glioma. The tumor was solid, white colored with gelatinous appearance. Cystic change was also noted in the tumor.

Effect of IGF-I on the Expression of GFAP, GC and GD3

IGF-I did not induce antigenic expression of GFAP in HITS glioma, although IGF-I increased the proportion and absolute cell number of GFAP-positive cells in neonatal glial cell culture, depending on the concentration (Table 3). IGF-I did not induce antigenic expression of GC or GD3 in neoplastic glia nor increase the population of GC or GD3 positive cells in neonatal glial cell culture.

Transmission Electron Microscope Examination (Fig. 9)

Each cell of HITS glioma contained a slightly irregular nucleus and a moderate amount of cytoplasm. The nucleus contained nucleoli and dense chromatin which were partially attached to the nuclear envelope. A moderate number of rER, mitochondria, abundant free ribosomes, and microtubules were observed in the cytoplasm (inset). There were thin cytoplasmic processes, but glial filaments were absent.

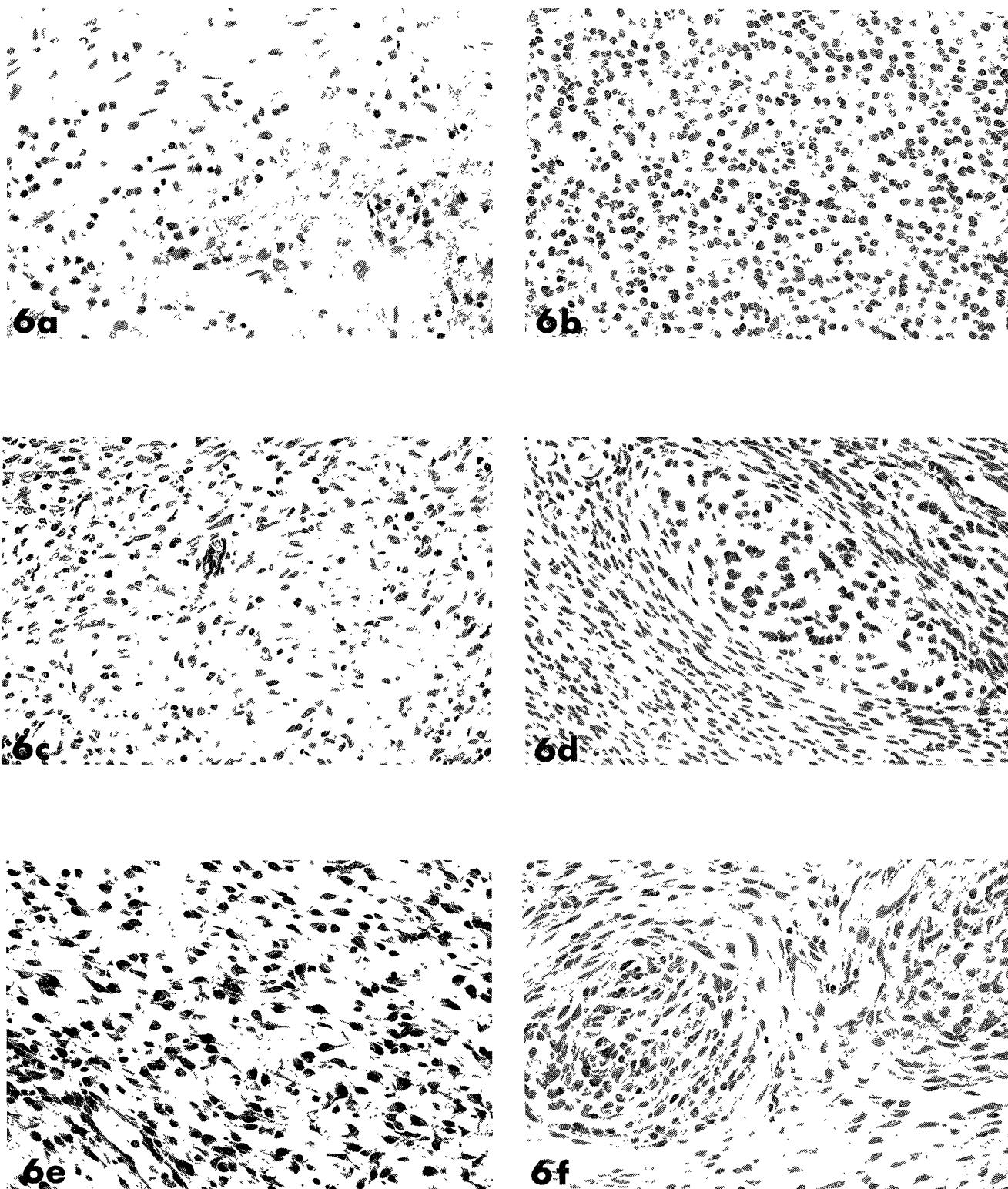


Fig. 6 (a-f). Light microscopy of transplanted tumors (HITS glioma). (H & E, x 400)
6a; Isomorphic proliferation of small round cells corresponding to oligodendroglioma.
6b; anaplastic glioma-like lesion composed of small polygonal cells.
6c; sarcomatous focus composed of spindle cells.
6d; ependymomatous focus composed of small polygonal cells and wide intercellular spaces.
6e; astrocytoma-like lesion composed of multipolar cells.
6f; perivascular proliferation composed of spindle cell proliferation in concentric circles.

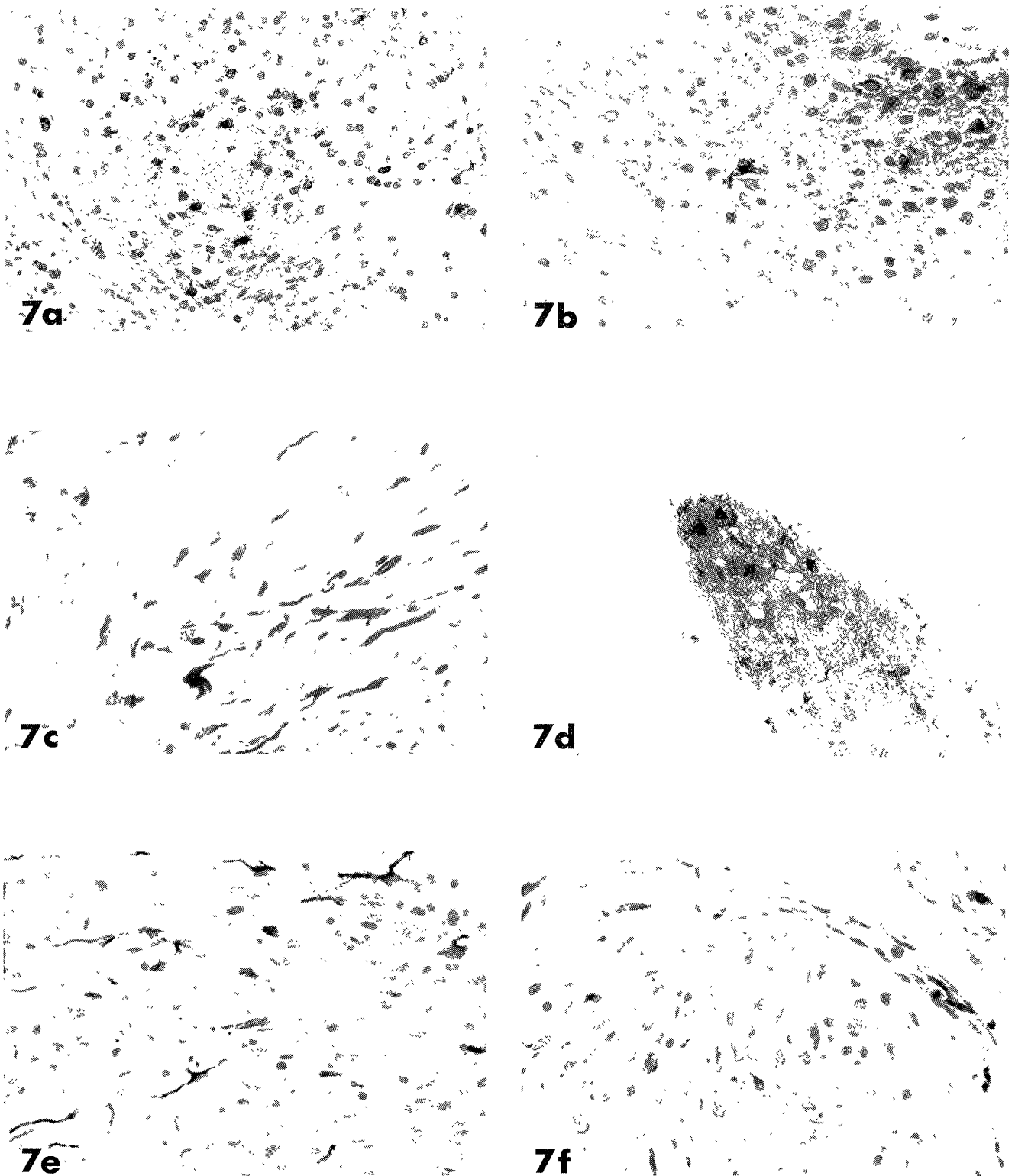


Fig. 7 (a-f). GFAP immunostaining of transplanted tumors (HITS glioma). (GFAP)
 7a; oligodendrogloma-like lesion. (x 400)
 7b; anaplastic glioma-like lesion. (x 600)
 7c; sarcomatous focus. (x 600)
 7d; ependymomatous focus. (x 400)
 7e; astrocytoma-like lesion. (x 400)
 7f; perivascular proliferation. (x 600)

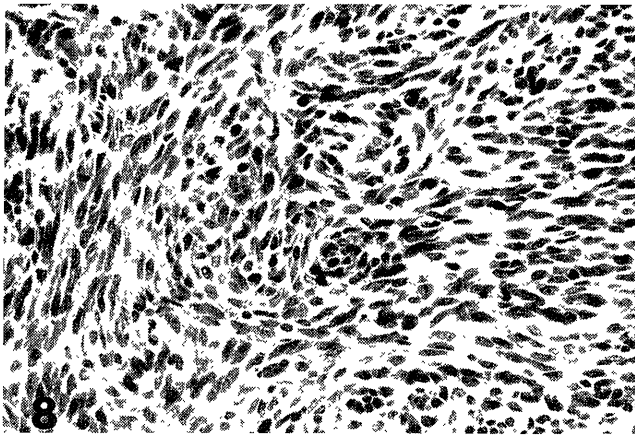


Fig. 8. Light microscopy of another transplanted tumor (RT1005) (H & E, x 200)
The tumor composed of spindle cells lacks the morphological feature of primary glioma, histologically.

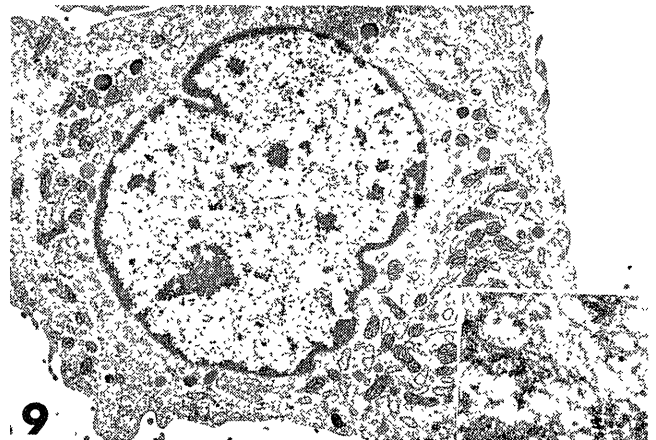


Fig. 9. Transmission electron micrographs of HITS glioma culture. (x 4000)
Each cell contained a slightly irregular nucleus and a moderate amount of cytoplasm. Microtubules were observed in the cytoplasm (inset).

Table 1. Effect of IGF-I on the Proliferation of HITS Glioma Cells and Neonatal Rat Glial Cell Culture (x 10⁴): Cell Number After One Week

		IGF1 (-)	10ngIGF1	100ngIGF1	200ngIGF1
0.1%FBS	HITS glioma	8.40 ± 0.72	10.33 ± 1.04	16.77 ± 1.65	16.50 ± 0.73
	control glia	2.30 ± 0.21	2.70 ± 0.21	5.07 ± 0.31	5.40 ± 0.38
10%FBS	HITS glioma	19.23 ± 0.45	—	—	—
	control glia	8.07 ± 0.48	—	—	—

seeded cell number (approximately 2.0 x 10⁴)
mean ± standard deviation (n = 3, P < 0.05)

Table 2. Effect of IGF-I on BrdU Incorporation of HITS Glioma Cells and Neonatal Rat Glial Cell Culture (%)

		IGF1 (-)	10ngIGF1	100ngIGF1	200ngIGF1
0.1%FBS	HITS glioma	6.40 ± 0.50	9.00 ± 0.28	9.93 ± 0.21	10.30 ± 0.21
	control glia	5.43 ± 0.12	6.33 ± 0.26	8.66 ± 0.35	9.60 ± 0.64
10%FBS	HITS glioma	11.70 ± 0.29	—	—	—
	control glia	11.00 ± 0.33	—	—	—

seeded cell number (approximately 5.0 x 10³)
mean ± standard deviation (n = 3, P < 0.05)

Table 3. Proportion and Cell Number of GFAP Positive Cells of HITS Glioma Cells and Neonatal Rat Glial Cell Culture

		proportion of GFAP positive cells (%) (cell number of GFAP positive cells x10 ⁴)			
		IGF1 (-)	10ngIGF1	100ngIGF1	200ngIGF1
0.1%FBS	HITS glioma	0	0	0	0
	control glia	19.17 ± 0.76 (0.4)	28.83 ± 1.04 (0.7)	45.50 ± 1.68 (2.3)	48.30 ± 1.02 (2.6)
10%FBS	HITS glioma	0	—	—	—
	control glia	51.60 ± 1.51 (4.1)	—	—	—

seeded cell number (approximately 5.0 x 10³)
mean ± standard deviation (n = 3, P < 0.05)

Discussion

Several types of neoplastic glia histologically similar to their normal counterparts (oligodendrocytes, astrocytes, and immature glia) have been recognized in ENU-induced gliomas.¹⁷⁾ This fact may indicate the existence of pluripotent neoplastic glia. Identification of these pluripotent neoplastic glia and the elucidation of the mechanisms of their differentiation should therefore promote our understanding of their neurobiology. *In vivo* studies, however, have limitations in assigning pluripotent or immature glia to specific lineages, and are also complicated by reactive glia. *In vitro* studies circumvent these limitations, although antigenic instability or phenotypic change such as mesenchymal drift are often observed.^{21,26)} In order to characterize the tumor cells *in vitro*, it is necessary to obtain cell lines which display morphological characteristics similar to the tumor cells *in vivo*.

In the present study, four out of five cell lines derived from ENU-induced gliomas showed mesenchymal drift, i. e. isomorphic proliferation of spindle-shaped cells in late passage, but one cell line, the HITS glioma, retained the morphological characteristics of cells in the primary culture for more than 300 days (over 50 passages) and showed the feature of neoplastic oligodendrocyte by electron microscopy.¹⁷⁾ Furthermore, the HITS glioma have shown unique characteristics after subcutaneous inoculation into neonatal rats, yielding tumors similar to *in vivo* tumors of several histological types, including oligodendroglioma-like lesions, anaplastic glioma-like lesions, sarcomatous foci, ependymomatous foci, and astrocytoma-like lesions. There were apparent transitions among the various components. A fraction of the cells expressed GFAP, a specific astrocyte marker, and GFAP-positive cells in inoculated tumors varied in morphological features, consisting of oligodendrocytic, astrocytic and fibroblastic types. These GFAP-positive cells were negative for MBP, and so the author consider that the cells derived from inoculated culture cells rather than Schwann cells that migrated from the peripheral nerve of recipient rats. Since HITS glioma did not express GFAP *in vitro*, these GFAP-positive cells seemed to originate from GFAP-negative neoplastic glia as astrocytic differentiation of immature neoplastic glia. Using electron microscopy, Mandybur saw ENU-induced ependymomatous neoplasms not as true ependymal tumors but rather as primitive neuroepithelial neoplasms.²⁰⁾ In oligodendrogliomas, the existence of transitional cells between oligodendrocytes and gemistocytic astrocytes,¹¹⁾ and GFAP-positive neoplastic oligodendrocytes^{2,14,25,29,38)} were reported. Some authors reported transient GFAP expression by immature oligodendrocytes.^{1,3,14)} The morphological variety and GFAP expression in inoculated tumors suggest that HITS glioma consist of immature neoplastic glia.

Raff *et al.* found a type of progenitor cell (0-2A progenitor cells) in the rat optic nerve capable of differentiating to

both oligodendrocytes and astrocytes depending on culture conditions.²⁸⁾ In humans, oligodendrogliomas may originate from 0-2A progenitor cells.⁴⁾ In our laboratory, the antigenic expression of GD3, a marker for immature glia in 0-2A lineage^{6,18)} was found in ENU-induced gliomas *in vivo*.³⁶⁾ Although, HITS glioma cells in cell culture and inoculated sites showed loss of the GD3 ganglioside expression, HITS glioma cells had the ability to form the tumor histopathologically mimicking the primary glioma. Therefore, loss of the antigenic expression of GD3 ganglioside in cultured cells and inoculated tumor cells may be due to the change of environment or dedifferentiation of the cells. The subpopulation of HITS glioma that expressed GFAP may belong to cells of 0-2A lineage, although oligodendrocytic differentiation of HITS glioma has been proven neither *in vivo* nor *in vitro* in the present study despite the oligodendrocytic morphological characteristics *in vitro*. MBP and GC are expressed by mature oligodendrocytes,^{27,35)} and the possibility of the mixture of various differential stages of glial cells in HITS glioma is not denied. In this respect, cloning of HITS glioma and other antibodies specific for immature oligodendrocytes is necessary for further investigation.

IGF-I, which is distributed throughout the central nervous system,³³⁾ regulates the proliferation and differentiation of glia.^{10,22,23)} Specific receptors for IGF-I were also found in neoplastic glia.^{7,15,24)} The present study suggested that IGF-I at physiological concentrations played a role in the proliferation of HITS glioma as well as neonatal glia *in vitro*. IGF-I induced the cell proliferation or differentiation of astrocytes in neonatal glial cultures, and not only the proportion but also the total number of GFAP positive cells was increased in the present study. However, GFAP was not detected in HITS glioma. Thus the expression of GFAP by HITS glioma in inoculated sites is probably mediated by other growth factors, for example, interleukins, fibroblast growth factor *etc.* The importance of the extracellular matrix in the development of gliomas was also noted.⁸⁾ Further examination using other culture conditions that mimic *in vivo* environments is necessary to elucidate the glial cell differentiation *in vitro*.

The studies on the role of growth factors on ontogenesis in the fetal brain, and the mechanisms of proliferation of tumor cells by growth factors *in vitro* may clarify the differentiation of normal glial lineage and neoplastic glia. HITS glioma is a unique cell line that differentiates to astrocytic cells under certain conditions. This cell line might serve as a way to promote understanding of the proliferation and differentiation of neoplastic glia, although the mechanism of astrocytic differentiation remains to be elucidated.

Acknowledgements

The author wish to express thanks to Professor Takayoshi Ikeda for his constant guidance and encouragement in the course of the study. Thanks are also due to Dr. Keisuke Iwasaki, Dr. Isao Shimokawa and Dr. Yoshikazu Higami for valuable suggestions, Dr. Alan Houghton, Sloan Kettering Memorial Institute, New York, for providing anti-GD3 ganglioside antibody, Mr. Masanori Shibata for his skillful photographic technique, and Mr. Brian Burke-Gaffney for his comments on our English manuscript. I am also indebted to the members of the First Department of Pathology, Bio-safety Laboratory, Department of Electron Microscopy Center and Laboratory Animal Center for Biomedical Research, Nagasaki University School of Medicine, for their cooperation in the study.

References

- 1) Borit A., and McIntosh G. C.: Myelin basic protein and glial fibrillary acidic protein in human fetal brain. *Neuropathol. Appl. Neurobiol.* 7:279-287, 1981.
- 2) Conley F. K.: The immunocytochemical localization of GFA Protein in experimental murine CNS tumors. *Acta Neuropathol. (Berl.)* 45:9-16, 1979.
- 3) Dahl D.: The vimentin-GFA Protein transition in rat neuroglia cytoskeleton occurs at the time of myelination. *J. Neurosci. Res.* 6:741-748, 1981.
- 4) de la Monte S. M.: Uniform lineage of oligodendrogliomas. *Am. J. Pathol.* 135 (3):529-540, 1989.
- 5) Druckrey H., Ivankovic S., and Preussmann R.: Teratogenic and carcinogenic effects in the offspring after single injection of ethylnitrosourea to pregnant rats. *Nature* 210:1378-1379, 1966.
- 6) Dutly F., and Schwab M. E.: Neurons and astrocytes influence the development of purified 0-2A progenitor cells. *Glia* 4:559-571, 1991.
- 7) Gammeltoft S., Ballotti R., Kowalski A., Westermarck B., and Obberghan E. V.: Expression of two types of receptor for insulin-like growth factors in human malignant glioma. *Cancer Res.* 48:1233-1237, 1988.
- 8) Giordana M. T., Mauro A., and schiffer D.: Glycosaminoglycans of brain tumors transplacentally induced by ENU in the rat. *Acta Neuropathol. (Berl.) Suppl.* VII:79-80, 1981.
- 9) Gratzner H. G.: Monoclonal antibody to 5-bromo and 5-iododeoxyuridine: A new reagent for detection of DNA replication. *Science* 218:474-475, 1982.
- 10) Han V. K. M., Lauder J. M., and D'Ercole A. J.: Characterization of Somatomedin/Insulin-like growth factor receptors and correlation with biologic action in cultured neonatal rat astroglial cells. *J. Neurosci.* 7 (2):501-511, 1987.
- 11) Herpers M. J. H. M., and Budka H.: Glial fibrillary acidic protein (GFAP) in oligodendroglial tumors: Gliofibrillary oligodendroglioma and transitional oligoastrocytoma as subtypes of oligodendroglioma. *Acta Neuropathol. (Berl.)* 64:265-272, 1984.
- 12) Higami Y.: Response of ethylnitrosourea-induced rat glioma to growth factors in primary culture. *Nagasaki Med. J.* 62 (2):150-172, 1990. (in Japanese with English abstract)
- 13) Hsu S. -M., Raine L., and Fanger H.: Use of avidin-biotin-peroxidase complex (ABC) in immunoperoxidase techniques: A comparison between ABC and unlabeled antibody (PAP) procedures. *J. Histochem. Cytochem.* 29 (4):577-580, 1981.
- 14) Jagadha V., Halliday W. C., and Becker L. E.: Glial fibrillary acidic protein (GFAP) in oligodendrogliomas: A reflection of transient GFAP expression by immature oligodendroglia. *Can. J. Neurol. Sci.* 13:307-311, 1986.
- 15) Kiess W., Lee L., Graham D. E., Greenstein L., Tseng L. Y. -H., Rechler M. M., and Nissley S. P.: Rat C6 glial cells synthesize Insulin-like growth factor I (IGF-I) and express IGF-I receptors and IGF-II/mannose 6-phosphate receptors. *Endocrinology* 124:1727-1736, 1989.
- 16) Ko L., Koestner A., and Wechsler W.: Morphological characterization of nitrosourea-induced glioma cell lines and clones. *Acta Neuropathol. (Berl.)* 51:23-31, 1980.
- 17) Koestner A., Swenberg J. A. and Wechsler W.: Transplacental production with ethylnitrosourea of neoplasms of the nervous system in Sprague-Dawley rats. *Am. J. Pathol.* 63 (1):37-50, 1971.
- 18) LeVine S. M., and Goldman J. E.: Ultrastructural characteristics of GD3 ganglioside-positive immature glia in rat forebrain white matter. *J. Comp. Neurol.* 277:456-464, 1988.
- 19) Mauro A., Giordana M. T., Migheli A. and Schiffer D.: Glial fibrillary acidic protein (GFAP) in rat brain tumors transplacentally induced by ethylnitrosourea (ENU). *J. Neurosci. Sci.* 61:349-355, 1983.
- 20) Mandybur T. I. and Alvira M. M. : Ultrastructural findings in so-called ependymal rat tumors induced by transplacental administration of ethylnitrosourea (ENU). *Acta Neuropathol. (Berl.)* 57:51-58, 1982.
- 21) McKeever P. E.: Functional aspects of alterations in glioma cell antigens. *Neuroimmunol. Res.* 2:19-39, 1989.
- 22) McMorris F. A., Smith T. M., DeSalvo S. and Furlanetto R. W.: Insulin-like growth factor I/Somatomedin C: A potent inducer of oligodendrocyte development. *Proc. Natl. Acad. Sci. U. S. A.* 83:822-826, 1986.
- 23) McMorris F. A., and Dubois-DaIcq M.: Insulin-like growth factor I promotes cell proliferation and oligodendroglial commitment in rat glial progenitor cells developing in vitro. *J. Neurosci. Res.* 21:199-209, 1988.
- 24) Merrill M. J., and Edwards N. A.: Insulin-like growth factor-I receptors in human glial tumors. *J. Clin. Endocrinol. Metab.* 71 (1):199-209, 1990.
- 25) Nakagawa Y., Perentes E., and Rubinstein L. J.: Immunohistochemical characterization of oligodendrogliomas: an analysis of multiple markers. *Acta Neuropathol. (Berl.)* 72:15-22, 1986.
- 26) Peatau A. : Glial fibrillary acidic protein, vimentin and fibronectin in primary cultures of human glioma and fetal brain. *Acta Neuropathol. (Berl.)* 75:448-455, 1988.
- 27) Raff M. C., Rhona M., Fields K. L., Lisak R. P., Dorfman S. H., Silberberg D. H., Gregson N. A., Leibowitz S., and Kennedy M. C.: Galactose is a specific cell-surface antigenic marker for oligodendrocytes in culture. *Nature* 274:813-816, 1978.
- 28) Raff M. C., Miller R. H., and Noble M.: A glial progenitor cell that develops in vitro into an astrocyte or an oligodendrocyte depending on culture medium. *Nature* 303 (2):390-396, 1983.
- 29) Reifenberger G., Bilzer T., Seitz R. J., and Wechsler W.: Expression of vimentin and glial fibrillary acidic protein in ethylnitrosourea-induced rat gliomas and glioma cell lines. *Acta Neuropathol. (Berl.)* 78:270-282, 1989.
- 30) Sandberg A. -C., Engberg C., Lake M., von Holst H., and Sara V. R.: The expression of insulin-like growth factor I and insulin-like growth factor II genes in the human fetal and adult brain and in glioma. *Neurosci. Lett.* 93:114-119, 1988.
- 31) Schechter A. L., Stern D. F., Vaidyanathan L., Decker S. J., Drebin J. A., Green M. I., and Weinberg R. A.: The neu oncogene: an erb-B-related gene encoding a 185,000-Mr tumour antigen. *Nature* 312:513-516, 1984.
- 32) Shapiro J. R.: Biology of gliomas: Heterogeneity, oncogenes, growth factors. *Semin. Oncol.* 13 (1):4-15, 1986.
- 33) Shemer J., Raizada M. K., Masters B. A., Ota A., and LeRoith D.: Insulin-like growth factor I receptors in neuronal and glial cells. *J. Biol. Chem.* 262 (16):7693-7699, 1987.
- 34) Shimokawa I.: Immunohistochemical properties of glial cells of ethylnitrosourea induced brain tumor in the rat. *Acta Med. Nagasaki.* 31:90-116, 1986.
- 35) Sternberger N. H., Itoyama Y., Kies M. W., and Webster H. F.: Myelin basic protein demonstrated immunocytochemically in oligodendroglioma prior to myelin sheath formation. *Proc. Natl. Acad. Sci.*

- U. S. A. 75 (5):2521-2524, 1978.
- 36) Takeshima F., Iwasaki K., Shimokawa I., Ikeda T., and Matsuo T.: Immunohistochemical localization of gangliosides in ENU-induced rat glioma. *Acta Pathol. Jpn.* 42 (8):558-565, 1992.
- 37) Yoshimine T., Maruno M., Ushio Y., Hayakawa T., Nakajima Y., and Mogami H.: Intermediate filaments and anaplastic change of ENU-induced gliomas: immunohistochemical study with vimentin and astroprotein (GFAP). *J. Neurooncol.* 5:377-385, 1987.
- 38) Yoshino T., Motoi M. and Ogawa K.: Morphological maturation of tumor cells induced by ethylnitrosourea (ENU) in rat brains. I. On the tumors by administration of ENU in the late gestational stage. *Acta Pathol. Jpn.* 35 (6):1385-1396, 1985.
- 39) Zapf J., Froesch E. R., and Humbel R. E.: The Insulin-like growth factors (IGF) of human serum: Chemical and biological characterization and aspects of their possible physiological role. *Curr. Top. Cell Regul.* 19:257-309, 1981.