

## Paget's Disease of the Female Breast

Hiroyoshi AYABE, Shinsuke HARA, Hiroharu TSUJI  
Tadayuki OKA, Yutaka TAGAWA Katsunobu KAWAHARA  
and Masao TOMITA

*The First Department of Surgery,  
Nagasaki University School of Medicine*

*Received for publication, June 17, 1991*

**ABSTRACT:** Eight patients of Paget's disease of the breast operated during 1969 and 1990 were studied. Four patients had Paget's diseases confirmed to the nipple and remaining 4 patients had an associated palpable tumor. Seven patients had invasive intraductal carcinoma and only one had noninfiltrative ductal carcinoma. None of the patients without palpable mass had axillary lymph node metastasis, while three of four patients (75%) with palpable mass in the breast had axillary lymph node metastases.

One patient of 4 without palpable mass died of lung cancer 19 years and 8 months after operation. Remaining 3 are alive and well 3 years, 4 years and 16 years following mastectomy. Two of 4 patients with palpable breast mass died of metastasis 6 months and 8 months after surgery. Remaining 2 are alive and well 7 months and 22 years following mastectomy.

### INTRODUCTION

Paget's disease of the breast has an incidence of 1 to 4 per cent of all breast cancer. Since Sir James Paget first described paget's disease of the nipple in 1874, a number of authors have extensively studied this unusual form of breast cancer. Certain factors relating to the pathogenesis and surgical management of this disease remain controversial.

This paper reports our experience with this disease and summarizes results of the therapy.

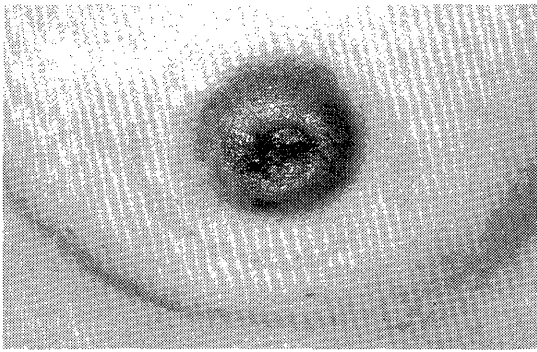
### MATERIALS AND METHODS

Between 1969 and December 1990, eight patients (1.7%) were to have Paget's invasion of the nipple among 466 patients with breast cancer in our department (Table 1). The patients had a mean age of 49.8 years (range 36-67 years). The mean duration of symptoms

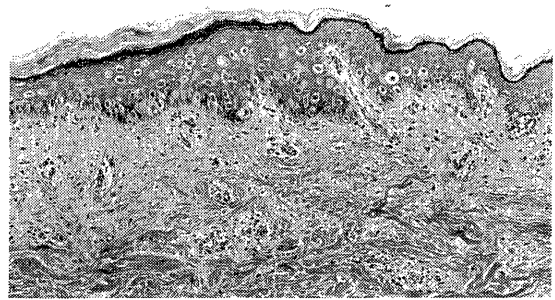
prior to surgery was 13.3 months (range 1-24 months). At the time of initial examination, 4 patients presented with disease confined to the nipple and areola characterized by eczema, erosion, crust formation or bleeding discharge without palpable mass in the breast (Fig. 1). Four patients had palpable mass with or without visible nipple changes. In two patients with palpable mass, they were immediately adjacent to the nipple. The lesions were unilateral and in the right in all instances.

Four patients were treated by modified radical mastectomy, 2 by extended radical mastectomy, 1 by radical mastectomy and 1 by simple mastectomy. A reason of the patient who underwent simple mastectomy was an old age. The radiation therapy was not added to any patients and only one patient was given postoperative adjuvant chemotherapy.

Follow-up information was obtained on all patients.



**Fig. 1.** Paget's disease of the breast with ulcerating lesion of the nipple



**Fig. 2.** Paget's disease of the nipple without underlying breast carcinoma

**Table 1.**

Number	Age (years)	Sex	Side and presenting findings	Time to symptom to diagnosis	Mass in breast	Axillary nodes	Pathology	Treatment	Follow-up
1	47	F	Right ECzema nipple	3 mo.	Yes 1.8 cm	No	Infiltrating ductal carcinoma	Radical mastectomy	well 22 yr.
2	67	F	Right Erosion of nipple	6 mo.	No	No	Infiltrating ductal carcinoma	Simple mastectomy	died 19yr. 4 mo. (lung cancer) No recurrence of breast cancer
3	46	F	Right Mass in breast	1 mo.	Yes 8.7 cm	Yes	Infiltrating ductal carcinoma	Extended radical mastectomy	died 8 mo. (lung metastasis)
4	49	F	Right Erosion of nipple and areola	18 mo.	No	No	Paget's carcinoma	Extended radical mastectomy	well 16 yr. 9 mo.
5	47	F	Right Erosion of nipple and areola	24 mo.	No	No	Non-infiltrating ductal carcinoma	Modified radical mastectomy	well 4 yr. 6 mo.
6	51	F	Right Bloody discharge nipple	24 mo.	Yes 3.0 cm	Yes	Infiltrating ductal carcinoma	Modified radical mastectomy	died 7 mo. (liver metastasis)
7	55	F	Right Erosion of nipple	6 mo.	No	No	Paget's carcinoma nipple	Modified radical mastectomy	well 3 yr. 4 mo.
8	36	F	Right ulcer of nipple	24 mo.	Yes 1.1 cm	Yes	Infiltrating ductal carcinoma	Modified radical mastectomy	well 1 yr. 3 mo.

## RESULTS

On histologic examination of the breast, the nipple contained typical intradermal Paget cells in all 8 patients. Six of 8 patients had infiltrating duct cell carcinoma, while one had non-infiltrating duct cell carcinoma. In one patient, large, clear intraepidermal Paget cells were present within intact epidermis, but underlying ductal cancer could not be found in the resected specimen (**Fig. 2**). None of the patients without palpable mass preoperatively had axillary lymph node metastases. However, three of four patients (75%) with palpable mass in the breast had axillary lymph node metastases. One of them had extensive axillary, subclavicular and parasternal lymph node metastases.

One patient of 4 without palpable breast mass who underwent simple mastectomy died of advanced small cell lung cancer 19 years and 8 months after operation. There was no local or systemic metastasis of Paget's disease in this patient at the time of death. Remaining 3 patients are now alive and well 3 years, 4 years and 16 years following mastectomy. Two of 4 patients with palpable breast mass died of lung or liver metastasis 6 months and 8 months after operation. Remaining 2 are alive now without disease 7 months and 22 years after mastectomy, respectively. They had both axillary lymph node metastasis microscopically in the resected specimen.

## DISCUSSION

The histologic appearance of Paget's disease is well known but histogenesis is still debatable. Several theories have been proposed to explain the origin of the Paget cell. One theory is that the lesion begins in the mammary duct, secondary involving the skin and areola of nipple. Another theory is that the first evidence of the disease is the skin with eventual downgrowth into the ductal system. Alternative explanation is that sometimes two independent lesions are present, the nipple finding representing one neoplastic entity and an infiltrating carcinoma of the breast a second concomitant tumor. In the past, most patholo-

gists supported the view that the lesion of the nipple is an intraepithelial extension of underlying intraductal carcinoma<sup>1,2</sup>. However, the proposal that the Paget cell arise in the nipple epidermis independent from the underlying carcinoma either through in situ malignant transformation or degeneration from existing cells has gained support recently. Further support of this theory of in situ transformation has come from ultrastructural studies on Paget's disease in the breast<sup>3</sup>. Paone and Baker<sup>4</sup> reported that in one patient, Paget's disease developed in an area of a congenitally absent nipple-areola complex and an underlying intraductal and infiltrating duct carcinoma was present, but there were no ducts leading to the affected area of underlying skin. These observations also supported the view that Paget cells arise primarily in the nipple without direct connection to an underlying carcinoma. In our series, one patient had Paget's disease localized only in the epidermis in the nipple without underlying breast carcinoma. This finding also favors the theory that the Paget cells arise in an intraepidermal origin.

Abnormal findings of the nipple and areola in Paget's disease of the breast characterized by eczema, scaling, crust formation, erosion or ulceration without palpable breast mass. These findings are similar to eczema of the skin. Then, some percentage of the patients are misdiagnosed and mismanaged as benign diseases for a long period. Four patients in this series treated as eczema of the nipple initially and diagnosed as Paget's disease by nipple biopsy after 2 years from their initial symptoms. Then, lesions that do not respond to conservative therapy within 2 weeks should be biopsied. And every lesion of the nipple or areola should be biopsied when there is doubt as to the diagnosis is recommended<sup>5</sup>.

Surgical treatment should be varied according to the nature and extent of the disease. The choice of the therapy depends upon the stage of the tumor, the age and general condition of the patient and the biologic relationship between host and disease. One of the striking findings has been the clear-cut difference in clinical behavior of this disease depending on whether or not a mass in the breast. None of the patient

without a palpable mass in the breast had axillary lymph node metastases and none died of breast cancer in this series. Several authors<sup>6, 7)</sup> reported the same results and recommended the simple mastectomy for the patients with Paget's disease without a palpable breast mass. However, Ashikari *et al*<sup>8)</sup> found axillary lymph node metastases in 13 per cent of the patients without a palpable breast mass and Aktan *et al*<sup>9)</sup> also reported 2 patients without a palpable mass with axillary lymph node metastases among 10 patients. From these findings, at present day, modified radical mastectomy such as Auchincloss procedure might be suitable for the patients with Paget's disease without a palpable mass in the breast. The incidence of a palpable mass associated with a lesion of the nipple or areola ranges from 33.3 to 69 per cent<sup>10)</sup>. In our series 4 of 8 patients or 50 percent had a palpable mass. Paget's disease with palpable breast mass behave little differently from ordinary breast cancer and should be treated according to the stage of the disease.

The survival of the patients with Paget's disease depends on with or without a palpable mass. A review of the literatures reveals the reported incidence of 5 year survival rates in patients with Paget's disease without a palpable mass ranges between 94% and 100%<sup>7, 8)</sup>. However, the prognosis of the patients with Paget's disease and a mass is no better than that from ordinary breast cancer. The reported survival rates of 5 years of the patients with Paget's disease with a palpable mass were between 18.8% and 42.5%<sup>4, 5)</sup>. Maier *et al*<sup>10)</sup> reported that premenopausal patients with Paget's disease of the breast had poor prognosis with 26.4 per cent five year survival rate, but the reason was not known.

## REFERENCES

- 1) Muir R: The pathogenesis of Paget's disease of the nipple and associated lesions. *Brit J Surg* 1935, 22:728-737.
- 2) Inglis K: Paget's disease of the nipple. London, Oxford University Press, 1936.
- 3) Sagebiel RW: Ultrastructural observations on epidermal cells in Paget's disease of the breast. *Am J Pathol*, 1969, 57: 49-64.
- 4) Paone JF, Baker RR: Pathogenesis and treatment of Paget's disease of the breast, *Cancer*, 1981, 48: 825-829.
- 5) McGregor JM, McGregor DD: Paget's disease of the breast. A twenty-year survey of cases presenting at a large General Hospital. *Surgery* 1959, 45: 562-568.
- 6) Kay S: Paget's disease of the nipple. *Surg Gynec Obstet*, 1966, 23: 1010-1014.
- 7) Nance FC, DeLoach DH, Welsh RA, Becker WF: Paget's disease of the breast, *Am Surg*, 1970, 171: 864-874.
- 8) Ashikari R, Park K, Huvos AG, Urban JA: Paget's disease of the breast, *Cancer*, 1970, 26: 680-685.
- 9) Aktan AO, Gokoz A, Goskel H: Paget's disease without a palpable mass in the breast, *Birt J Surg* 1990, 77: 226-227.
- 10) Maier WP, Rosemond GP, Harasym E, Al-Saleem TI, Fasson EM, Schor SS: Paget's disease in the female breast. *Surg Gynec Obstet*, 1969. 128: 1253-1263.