

Beta-Subunit of Human Chorionic Gonadotropin in Malignant Lymphoma: An Immunohistochemical Study

Masachika SENBA and Masami WATANABE

*Department of Pathology, Institute of Tropical Medicine, Nagasaki University,
Nagasaki 852, Japan.*

Received for publication, February 18, 1991

SUMMARY: We present a rare case of a 77-year-old Japanese man with malignant lymphoma associated with production of beta-subunit of human chorionic gonadotropin in the cytoplasm of lymphoma cells in the lymph nodes. By immunoperoxidase staining, numerous tumor cells were reacted with beta-subunit of human chorionic gonadotropin. To the best of our knowledge, production of beta-subunit of human chorionic gonadotropin in the cytoplasm of lymphoma cells has not been reported. This patient evidences that beta-subunit of human chorionic gonadotropin may be produced by tumor cells, therefore, beta-subunit of human chorionic gonadotropin may be used as a tumor maker in some malignant lymphoma patients.

INTRODUCTION

Human chorionic gonadotropin is a pregnancy associated glycoprotein hormone consisting of two different independently synthesized subunits, which are designated as alpha and beta. Human chorionic gonadotropin (HCG), follicle stimulating hormone (HFSH), and luteinizing hormone (HLH), consist of almost identical alpha-subunit and specific beta-subunit^{16, 21}. Human chorionic gonadotropin is normally secreted by the syncytiotrophoblasts of the placenta, and the human chorionic gonadotropin level is elevated in all trophoblastic tumors³. Extopic beta-subunit of human chorionic gonadotropin production has also been reported in a variety of non-germ cell tumors, especially in carcinomas of the lungs^{8, 20}, esophagus⁶, stomach¹⁰, liver¹⁴, pancreas¹², and bladder¹⁷.

The case presented in this report documents pathologically and clinically a malignant lymphoma that produced beta-subunit of human chorionic gonadotropin. Tumor cells were stained for the hormone antibody using immu-

noperoxidase procedure.

CASE REPORT

A 77-year-old Japanese man was admitted to Nagasaki University Hospital for the treatment of malignant lymphoma. The patient died of cardiac failure and renal failure. A lymph node biopsy showed a diffuse infiltration of atypical lymphoid cells with irregular nuclei, and a diagnosis of malignant lymphoma, diffuse mixed type, was made. At autopsy, swelling of lymph nodes was recognized in the mesenteric, paraaortic, and peripancreas. Infiltrations of lymphoma cells with irregular nuclei were found in the spleen, in the pancreas, in the stomach, in the lung, in the liver, in the duodenum, in the jejunum, and in the bone marrow. Shock kidneys were observed as diffuse necrosis, degeneration, and dilatation of proximal tubules. There was no hepatosplenomegaly.

Tissue specimens of all organs including lymph nodes were taken at autopsy and fixed in 10% formalin and embedded in paraffin. After ordinary methods of histological preparations,

paraffin blocks of specimens were cut at 4 micron, and stained with histochemical methods, and immunoperoxidase methods for beta-subunit of human chorionic gonadotropin (HCG) (polyclonal antibody; DAKO PAP Kit: K508, Lot. 108-1), for B-cells (monoclonal antibody; Bio-science products: Anti-leukocyte B-cells (MB-1); Lot. 050), and for T-cells (monoclonal antibody; Bio-science products: Antileukocyte T-cells (MT-1); Lot. 048).

Beta-subunit of human chorionic gonadotropin was revealed in numerous cytoplasm of lymphoma cells in lymph nodes by immunoperoxidase procedure with DAB counterstaining

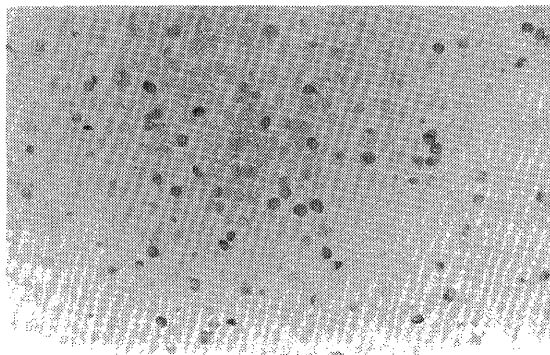


Fig. 1. Immunohistochemical preparation demonstrating numerous neoplastic cells reacting to beta-subunit of human chorionic gonadotropin. (Immunoperoxidase with DAB counterstained with methyl green, $\times 200$)

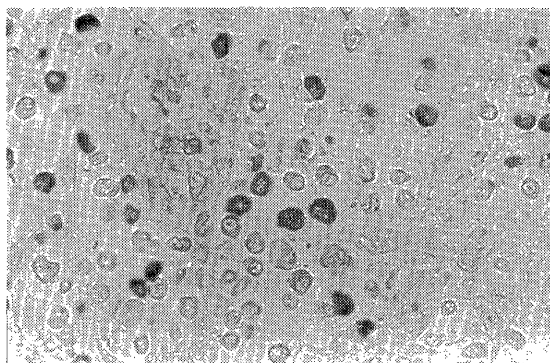


Fig. 2. High power view of Figure 1. Immunohistochemical stain for beta-subunit of human chorionic gonadotropin shows cytoplasmic positivity of tumor cells. (Immunoperoxidase with DAB counterstained with methyl green, $\times 400$)

(**Figs. 1 and 2**). Immunoperoxidase staining showed numerous tumor cells reacted with MT-1 antibody, therefore, this case was diagnosed as T-cell type lymphoma.

DISCUSSION

The production and secretion of beta-subunit of human chorionic gonadotropin and the detection of this protein in the tissue have been associated with a wide variety of neoplasms in addition to the more frequently described placental, gonadal, and extragonadal choriocarcinoma. Extragonadal human chorionic gonadotropin production has frequently been reported in a variety of carcinomas, and occasionally in sarcomas. Ectopic beta-subunit of human chorionic gonadotropin production has also been reported in a variety of non-germ cell tumors. The reasons for localization of beta-subunit of human chorionic gonadotropin in the non-germ cell tumors are not clear. A possible explanation may be that ectopic beta-subunit of human chorionic gonadotropin production by malignant tumors is due to derepression of genes that are repressed in fetal life, to recruitment of uncommitted cells, or to a random mutation⁴). The presence of HCG-like material has been reported in the spermatozoa¹, in the normal testis⁶, in the liver¹⁹), in the colon²²), and in the pituitary⁷). Extracts of fetal liver and kidneys¹³), and bacteria²) have exhibited HCG-like activity. HeLa cells and variety of other malignant cell lines also secrete HCG and its free subunit in culture¹⁵).

In this case, serum assay of beta-subunit of human chorionic gonadotropin was not examined. The one cases were found good correlation between elevated serum level and tissue localization, the other cases were not. Two explanations for the discrepancy in the incidence of beta-subunit of human chorionic gonadotropin in serum and tissue staining are considered. The first, the tumors produce beta-subunit of human chorionic gonadotropin, but not secrete it. The second, the substance metabolism is very rapid resulting in undetectable in the serum.

REFERENCES

- 1) Acevedo HF, Slifkin M, Pouchet GR, Rakhashan M: Identification of the beta-subunit of choriongonadotropin in human spermatozoa. In: Troen P, Nankin HR, eds., *The testis in normal and infertile men*. New York: Raven Press, 185-192, 1977.
- 2) Acevedo HF, Slifkin M, Pouchet GR, Pardo M: Immunohistochemical localization of a choriongonadotropin-like protein in bacteria isolated from cancer patients. *Cancer*, **41**: 1217-1229, 1978.
- 3) Bagshaw KD, Wass M, Searle F: Markers in gynecological cancer. *Arch. Gynecol.*, **229**: 303-310, 1980.
- 4) Blackman MR, Rosen SW, Weintraub BD: Ectopic hormones. *Adv. Intern. Med.*, **23**: 85-113, 1978.
- 5) Braunstein GD, Razor J, Wade ME: Presence in normal human testes of a chorionic-gonadotropin-like substance distinct from human luteinizing hormone. *N. Engl. J. Med.*, **295**: 1339-1343, 1975.
- 6) Burg-Kurland CL, Purnel DM, Combs JW, Hillman EA, Harris CC, Trump BF: Immunocytochemical evaluation of human esophageal neoplasms and preneoplastic lesions for beta-chorionic gonadotropin, placental lactogen, alpha-fetoprotein, carcinoembryonic antigen, and nonspecific cross-reacting antigen. *Cancer Res.*, **46**: 2936-2943, 1986.
- 7) Chen HC, Hodgen GD, Matsuura S, Lin LJ, Gross E, Reichert LE, Birken S, Canfield RE, Toss G: Evidence for a gonadotropin from nonpregnant subjects that has physical, immunological, and biological similarities to human chorionic gonadotropin. *Proc. Natl. Acad. Sci. USA*, **73**: 2885-2889, 1976.
- 8) Fukayama M, Hayashi Y, Koike M, Hajikano H, Endo S, Okumura H: Human chorionic gonadotropin in lung and lung tumors. *Lab. Invest.*, **55**: 433-443, 1986.
- 9) Fukuyama M, Hayashi Y, Koike M: Human chorionic gonadotropin in the rectosigmoid colon: Immunohistochemical study on unbalanced distribution of subunits. *Am. J. Pathol.*, **127**: 83-89, 1987.
- 10) Gailani S, Chu TM, Nussbaum A, Ostrander M, Christoff N: Human chorionic gonadotropins (hCG) in non-trophoblastic neoplasms: Assessment of abnormalities of hCG and CEA in bronchogenic and digestive neoplasms. *Cancer*, **38**: 1684-1686, 1976.
- 11) Ghosh NK, Cox PP: Production of human chorionic gonadotropin in HeLa cell cultures. *Nature*, **259**: 416-417, 1976.
- 12) Hyderman E, Chapman DV, Richardson TC, Calvert I, Rosen SW: Human chorionic gonadotropin and human placental lactogen in extragonadal tumors: An immunoperoxidase study of ten non-germ cell neoplasms. *Cancer*, **56**: 2674-2682, 1985.
- 13) McGregor WG, Kuhn RW, Jaffe RB: Biologically active chorionic gonadotropin: Synthesis by the human fetus. *Science*, **220**: 306-308, 1983.
- 14) Nakanuma Y, Unoura M, Noto H, Ohta G: Human chorionic gonadotropin in primary liver carcinoma in adults. *Virchows Arch. A*, **409**: 365-373, 1986.
- 15) Neuwald PD, Anderson C, Saliver WO, Aldenderfer PH, Dermody WC, Weintraub BD, Rosen SW, Nelson-Rees WA, Ruddon RW: Expression of oncodevelopmental gene products by human tumor cells in culture. *J. Natl. Cancer Inst.*, **64**: 447-459, 1980.
- 16) Pierce JG, Parsons TF: Glycoprotein hormones: Structure and function. *Ann. Rev. Biochem.*, **50**: 465-495, 1981.
- 17) Shah VM, Newman J, Crocker J, Chapple CR, Collard MJ, O'Brien JM, Considine J: Ectopic beta-human chorionic gonadotropin production by bladder urothelial neoplasia. *Arch. Pathol. Lab. Med.*, **110**: 107-111, 1986.
- 18) Tyrey L: Human chorionic gonadotropin: Structural, biologic, and immunologic aspects. *Semin. Oncol.*, **9**: 163-173, 1982.
- 19) Yoshimoto Y, Wolfsen AR, Oddell WD: Human chorionic gonadotropin-like substance in non-endocrine tissues of normal subjects. *Science*, **197**: 575-577, 1977.
- 20) Wilson TS, McDowell EM, McIntire R, Trump BF: Elaboration of human chorionic gonadotropin by lung tumors. *Arch. Pathol. Lab. Med.*, **105**: 169-177, 1981.