

Temporary Division of the Superior Vena Cava For Extended Left Atriotomy ; Left-sided Atrioventricular Valve Repair in Corrected Transposition of the Great Arteries

Tetsuo HADAMA, M. D., Joji SHIRABE, M. D., Hidemi TAKASAKI, M. D., Yoshiaki MORI, M. D., Keiji OKA, M. D., Osamu SHIGEMITSU, M. D., Tatsunori KIMURA, M. D., Shinji MIYAMOTO, M. D., and Yuzo UCHIDA, M. D.

*Second Department of Surgery, Medical College of Oita, 1-1
Idaigaoka, Hazama-cho, Oita, 879-56, Japan*

Received for publication, March 2, 1990

SUMMARY : The extended left atriotomy which combines the standard approach with the superior approach by concomitant temporary division of the superior vena cava (SVC) is a safe and useful method in the case of a small atrium. The approach used here is a modification of that which was reported by Selle and Kyger. This technique made it possible to sufficiently expose the laterally situated small left atrium in the case of corrected transposition of the great arteries (cTGA) which requires repair of the left-sided atrioventricular valve (tricuspid valve).

In recent mitral surgery, median sternotomy is used with cannulation of the ascending aorta and both venae cavae to establish cardiopulmonary bypass. Although there are some approaches for left atriotomy, the standard procedure is to use vertical left atriotomy immediately posterior and parallel to interatrial sulcus. And in the case of combined mitral with tricuspid valve surgery, a right atriotomy with incision of interatrial septum has been employed to allow excellent exposure of the left atrium and mitral and tricuspid valve including subvalvular supporting structures. Surgical exposure of the mitral valve is often difficult by the conventional approach, especially in the patient with a small left atrium and a deep chest. In the case of cTGA too, sufficient exposure of the left atrium can not be obtained under median sternotomy on account of anatomical abnormality. We performed prosthetic valve implantaion to the left-sided atrioventricular valve which is tricuspid valve in structure in the case of cTGA by means of new approach with the incision of the lateral to superior wall of the left atrium combined with division of the SVC temporarily. This technique was introduced by Selle¹⁾ in a recent article.

SURGICAL PROCEDURE

A 48-year-old man was diagnosed as cTGA with left-sided atrioventricular valve insufficiency and was admitted to our hospital for the purpose of surgery. A standard sternotomy and

pericardiotomy were made and the heart was exposed entirely. Great arteries of the aorta, pulmonary artery and superior vena cava were situated in order from the left, and the aorta originated from the left-sided ventricle and the pulmonary artery from the right-sided ventricle. Both ventricles were situated side by side

laterally. The right atrium was exceedingly small and the left atrium was placed left and anteriorly so that the right-side lateral wall of the left atrium could not be exposed sufficiently. This anatomical situation indicated a difficulty in the conventional left atriotomy. Therefore, the inflow cannula was placed through the ascending aorta, but the drainage cannula required some contrivance so as to gain excellent exposure of the left atrium. The SVC was mobilized to junction with the azygos vein exceeding out of the pericardial sac, and purse-string suture with a tourniquet was placed on the cephalad SVC. A right-angled venous drainage cannula was inserted from inside of this purse-string and secured with a tourniquet just superior to the azygos vein. The inferior vena cava (IVC) was drained with a cannula placed through the right atrial wall. The cardiopulmonary bypass was begun and moderate hypothermia was acquired by core cooling. The SVC was divided between the superior drainage cannula and the right atrium, and a bulldog clamp was applied to the azygos vein to avoid flooding of the operative field. The left atriotomy could be made posterior to the interatrial sulcus from around the IVC toward the superior wall behind the SVC and the pulmonary artery. By means of retraction of the collapsed pulmonary artery toward left-sided aorta laterally, exposure of the left atrium and of the tricuspid valve with this approach was excellent, and precise observation of the leaflets and subvalvular structure could be done completely. Tricuspid insufficiency was caused by annular enlargement and prolongation of the tendinous chord with partial rupture. Prosthetic valve implantation was performed with St. June Medical bi-leaflet valve preserving the native valvular structure without removing the tendinous chord. The left ventricular vent was placed in the left superior pulmonary vein though the prosthetic valve and the left atrium was closed with a running over and over suture using 3-0 Prolene. Declamp of the ascending aorta followed by rewarming and SVC was reanastomosed closely with the running over and over suture using 4-0 Prolene avoiding stenosis. Postoperative course was uneventful without morbidity caused by division

of the SVC.

DISCUSSION

The following are approaches for left atriotomy: (1) standard approach; vertical atriotomy posterior to interatrial sulcus, (2) right atriotomy with interatrial septotomy, (3) modified approach to standard left atriotomy combining right atriotomy with interatrial septotomy perpendicular to left atrial vertical incision,^{2,3)} (4) superior approach; transverse incision of superior portion of the left atrium retracting the aorta to the left, the SVC to the right.⁴⁾ In the patient with chronic mitral valve disease with an enlarged left atrium, the standard approach gives sufficient exposure of the left atrium and mitral valve. In the case of combined mitral with tricuspid valvular disease the right atriotomy with interatrial septotomy is useful. Although, acute mitral insufficiency due to acute myocardial infarction or infective endocarditis requires more extensive technique for the left atriotomy because in these cases the left atrium is frequently small and the day of the operation can not be delayed until it becomes sufficiently large. Selle¹⁾ has reported a new approach of the left atriotomy for patient with small left atrium which involves temporary division of the SVC and combining the standard vertical approach with the superior transverse incision. He employed this technique in three cases; in two a division of abnormal Kent pathway in Wolff-Parkinson-White syndrome and in one ventricular septal myectomy and mitral valve replacement for idiopathic hypertrophic subaortic stenosis with mitral valve insufficiency. In this article, he reported that this approach affords excellent exposure in selected cases. We performed this technique in the patient with cTGA with left-sided atrioventricular valve insufficiency. Because in this disease the right atrium is small and left atrium is situated left laterally and anteriorly, so that conventional insertion of the drainage cannula and left atriotomy is difficult. It is advantageous to use this technique in this operation because the aorta is located to the left of the pulmonary artery which is being decompressed during the cardiopulmonary bypass, so that the retraction

of the pulmonary artery toward the left enhances excellent exposure of the left atrium. We believe this technique with division of the SVC is a worthwhile approach for left atriotomy in the patient with cTGA. The indication of the extended left atriotomy by temporary division of the SVC showed in Table 1 according to Selle including our case of cTGA. Kyger⁵⁾ modified the original technique by Selle and reported. In Selle's method a drainage cannula is placed in the cephalad end of the divided SVC, so that during reanastomosis of the SVC using vascular clamp venous hypertension of the central nervous system will occur significantly. Kyger's method resolved this unfavorable problem by means of placing superior drainage cannula in the left innominate vein. But it is disadvantageous to use the left innominate vein for insertion of the drainage cannula, because the left innominate vein has thin wall and is friable. Whereas in our method the drainage cannula placed in the SVC which is protected by a strong adventitia and divided SVC can be reconstructed without causing venous hypertension. No complications were seen related to this extended left atriotomy.

Table 1. Indications of the extended left atriotomy with temporary division of the superior vena cava (from SELLE's report)

1. Normal-sized left atrium
 - a. Acute mitral valve incompetence following myocardial infarction or bacterial endocarditis
 - b. Division of left free wall knt bundle in Wolff-Parkinson-White syndrome
2. Otherwise difficult exposure
 - a. Previous cardiac operation, especially previous mitral or aortic valve procedure
 - *b. Corrected transposition of the great arteries required repair of left-sided atrioventricular valve
3. Necessity of exceptional mitral valve exposure
 - a. Delicate mitral valve repair for incompetence
 - b. Combined mitral valve replacement and septal resection for idiopathic hypertrophic subaortic stenosis

(* : added present case)

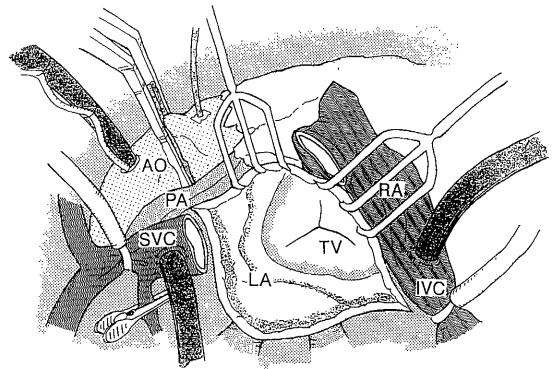


Fig. 1. Great vessels; aorta, pulmonary artery and SVC are situated from left in order. Superior venous drainage cannula is inserted in the SVC, and SVC is divided between drainage cannula and junction to the right atrium. Left atriotomy is made posterior to the interatrial sulcus from around the IVC toward the superior wall behind the SVC and pulmonary artery.

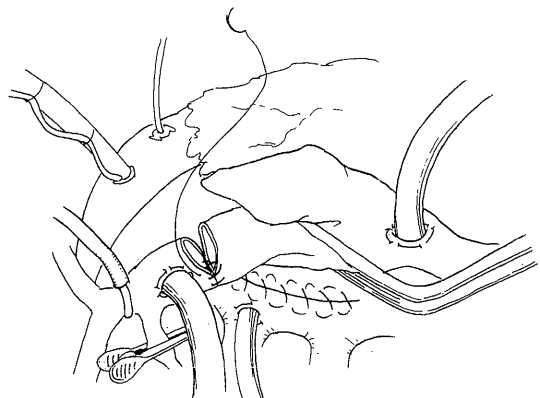


Fig. 2. Left atriotomy is closed under venting and SVC is re-anastomosed by continuous over and over running suture.

REFERENCES

- 1) Selle JG (1984) Temporary division of the superior vena cava for exceptional mitral valve exposure. *J Thorac Cardiovasc Surg* 88 : 302-304.
- 2) Dubost C, Guilmet D, Parades B, (1966) Nouvelle technique d'ouverture de l'oreillette gauche en chirurgie a coeur ouvert: l'abort bi-auriculaire transeptal. *Presse Med* 74 : 1605.
- 3) Brawley RK (1980) Improved exposure of the mitral valve in patients with a small left atrium. *Ann Thorac Surg* 29 : 179-181.

- 4) Meyer BW, Verska JJ, Lindesmith GG, Jones JC (1965) Open repair of mitral valve lesions. The superior approach. *Ann Thorac Surg* 1:453-457.
- 5) Kyger ER. Coselli M, Kalchoff WP (1986) A method for improved exposure of the mitral valve; Cannulation of innominate vein and division of superior vena cava for extended left atriotomy in mitral valve operations. *J Thorac Cardiovasc Surg* 91:143-146.