

## Expression of EGF and, Ras and Myc Oncogene Products in Normal, Graves' Thyroid, Adenoma, and Carcinoma of the Thyroid

Takayoshi TODA<sup>1</sup>, Shigeru DEGUCHI<sup>2</sup>, Kohtaro KURIHARA<sup>2</sup>  
Yuhshi HAMADA<sup>2</sup>, Yoshihiro MUTO<sup>2</sup> and Keizo KITSUKAWA<sup>3</sup>

*Clinical Laboratory Department<sup>1</sup>, University Hospital  
Department of Surgery<sup>2</sup>, School of Medicine,  
Department of Internal Medicine<sup>3</sup>, School of Medicine,  
University of the Ryukyus 903, Okinawa, Japan*

*Received for publication, December 26, 1987*

**SUMMARY :** An immunohistochemical study of EGF, and products of ras and myc oncogenes was carried out in 47 cases of non-neoplastic and neoplastic lesions of the thyroid. Normal thyroid tissues showed no significant immunostaining reaction to antibodies for EGF, and products of ras and myc oncogenes. The incidence of EGF positivity was 27%, 46% and 76% in Graves' disease, follicular adenoma, and carcinoma, respectively. The incidence of positivity of ras oncogene product was 27%, 38%, and 82% in Graves' disease, follicular adenoma and carcinoma, respectively. The incidence of positivity of myc oncogene product was 18%, 46% and 71% in Graves' disease, Follicular adenoma, and carcinoma, respectively. These results suggest that EGF, and ras and myc oncogenes or proto-oncogenes play a role in neoplastic lesions of the thyroid.

### INTRODUCTION

Oncogenes are nucleotides present in the genome of neoplastic cells, and they have been known to be differentiated from protooncogenes which are supposed to be important for normal cellular growth and differentiation (3). Recent investigations have suggested that various cellular oncogenes are expressed in human cancer tissues (17). To date about 40 oncogenes have been isolated and characterized. With regard to transformation of protooncogene to oncogene, three major types of processes have been postulated as follows : 1) amplification of oncogenes, 2) rearrangement of oncogenes and 3) point-mutations (23). The hypothesis has been proposed that at least two

kinds of oncogenes such as myc and ras are required in carcinogenesis (11). We have previously reported that ras and myc oncogene products are expressed in human coronary atherosclerotic lesions which are pathologically categorized as degenerative and non-neoplastic disease (21). These results prompted us to reevaluate the expression of several oncogenes in pathological lesions in various tissues because results are conflicting. This report describes an immunohistochemical identification of EGF, and products of ras and myc oncogenes in non-malignant and malignant thyroid tissues.

### MATERIALS AND METHODS

We examined six autopsy cases with normal

thyroid and a total of forty-one surgical cases including 11 Graves' disease, 13 adenoma and 17 carcinoma. Diagnosis was made according to WHO histological classification of thyroid tumors (6). Affinity purified monoclonal antibodies for EGF, ras and myc oncogene products (Oncor) were used in this study. Indirect immunoperoxidase (PAP) staining (18) was performed on 4 micrometer thick sections of formalin-fixed, paraffin-embedded tissues. Secondary antibody (rabbit antishoop immunoglobulin) and sheep PAP were purchased from Dakopatts. The sections were stained with 3', 3-diaminobenzidine hydrochloride solution and counterstained with hematoxylin. Omission of the primary antibodies and substitution of the primary antibodies with non-immune sera were used as negative control. The degree of immunoreactivity was expressed as the following: ++, definitely positive; +, weakly positive; -, negative.

## RESULTS

Table 1 shows the results of immunohistochemical staining of EGF in various types of thyroid tissues. Thyroid tissues examined included a total of forty seven cases including 6 normal thyroids, 11 Graves' disease, 13 follicular adenoma, 15 papillary carcinoma, and 2 follicular carcinoma. Normal thyroid tissues were collected from the middle-aged autopsy cases. These thyroid tissues showed various sizes of follicles which were composed of flat follicular epithelium and moderately dense eosinophilic colloid material. Immunostaining of EGF gave no reaction of EGF antibody to normal thyroid tissues (Fig. 1). Histological

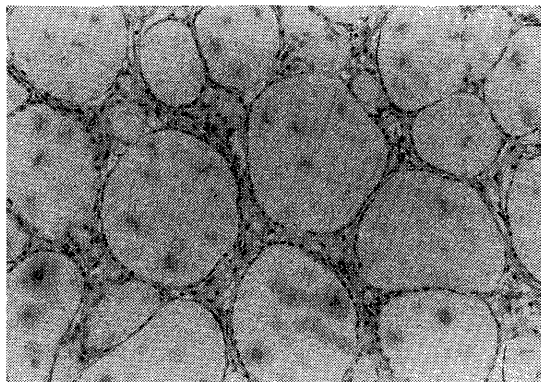


Fig. 1. No EGF is demonstrated in flat follicular epithelial cells of the normal thyroid (PAP stain  $\times 150$ ).

findings of the thyroid tissues with Graves' disease were variable because all the cases were placed on medication for certain duration before surgical operation. Most of the follicular epithelium of the thyroid with Graves' disease were cuboidal. Colloid material was weakly stained with eosin. Small vacuoles were occasionally seen along the luminal surface of the follicular epithelium. EGF was slightly to moderately demonstrated in hyperplastic foci of cuboidal epithelium which were seen in three of the 11 cases of Graves' diseases (Fig. 2). The thyroid tissues which were negative for EGF antibodies consisted of various size of follicles having flat epithelium. The follicular adenoma had a well defined capsule and was composed of various sizes of follicles showing a trabecular or tubular pattern. In this study, histological subtypes of follicular adenoma was not used because the number of follicular adenoma cases was not sufficient. Six of thirteen follicular adenoma cases showed definitely or

Table 1. Immunoreactivity for EGF in various types of thyroid tissues.

Diagnosis	Number of cases	Immunoreactivity			
		++	+	-	
Normal	6	0/6	0/6	6/6	
Graves' disease	11	1/11	2/11	8/11	
Follicular adenoma	13	2/13	4/13	7/13	
Carcinoma	papillary	15	8/15	3/15	4/15
	follicular	2	1/2	1/2	0/2

++ : definitely positive, + : weakly positive, - : negative

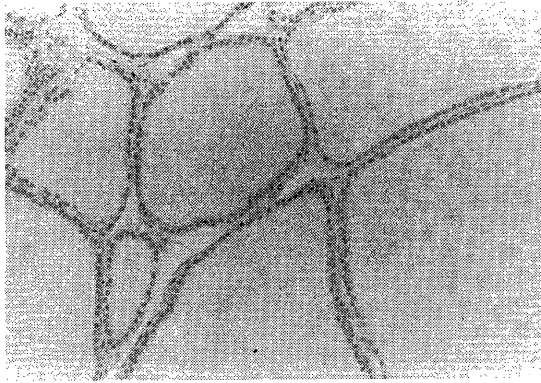


Fig. 2. Hyperplastic cuboidal follicular epithelial cells are weakly positive for EGF antibodies (PAP stain  $\times 150$ ).

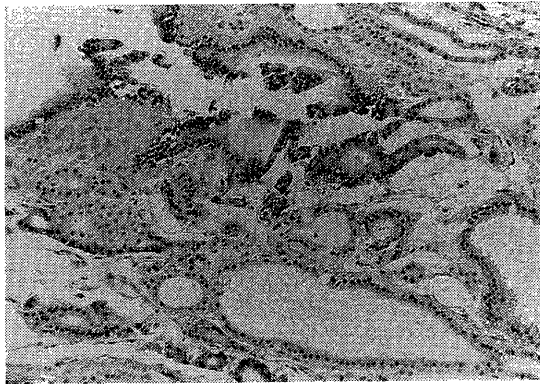


Fig. 3. Definitely EGF positive cells (P) are focally seen in adenoma (PAP stain  $\times 150$ ).

weakly positive reaction (Fig. 3). Epithelial cells of papillary carcinoma were characterized by the presence of pale ground-glass nuclei and clear or oxyphilic cytoplasm. Calcified spherules were occasionally seen in papillary carcinoma. Depending upon the degree of differentiation, follicular carcinoma showed follicular and trabecular patterns and solid masses of tumor cells. Tumor cells of follicular carcinoma possessed the hyperchromatic nuclei and the similar cytoplasm to those of the normal follicular cells. Positive reaction of EGF was seen in 76% of carcinomas including 11 papillary and two follicular carcinomas (Fig. 4). Immunohistochemical staining pattern of the products of ras and myc oncogenes were similar to that of EGF in various types of thyroid

tissues (Fig. 5 & 6).

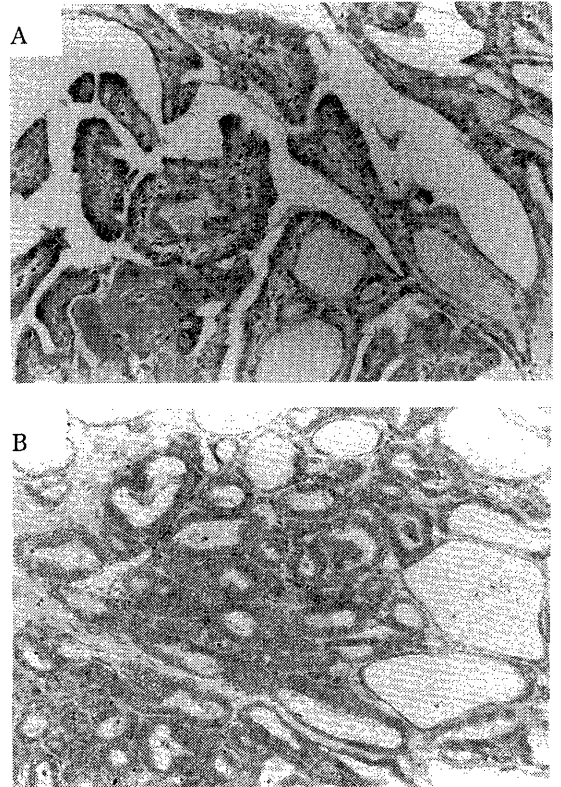


Fig. 4. Note definitely positive reaction of EGF antibody in papillary (A) and follicular (B) carcinomas (PAP stain  $\times 150$ ).

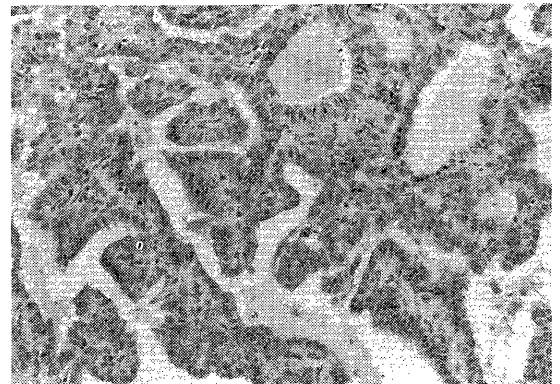


Fig. 5. Papillary carcinoma showing definitely positive staining of antibody for myc oncogene product (PAP stain  $\times 150$ ).

Table 2 and 3 present the incidence of immunohistochemical positivity of products of ras and myc oncogenes, respectively. Products of ras

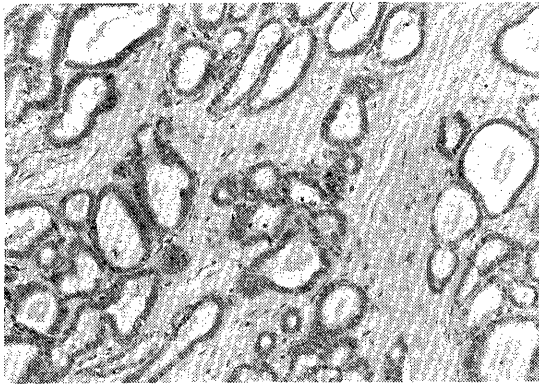


Fig. 6. Follicular carcinoma showing definitely positive staining of antibody for ras oncogene product (PAP stain  $\times 150$ ).

and myc oncogenes were more frequently and intensely demonstrated in carcinoma cases than in the adenoma cases and Graves' disease.

## DISCUSSION

Radioimmunoassay studies reported that EGF is a physiologically occurring plasma hormone and is contained in a relatively higher amount in human thyroid tissues than in other tissues (7, 8). Kesselberg *et al.* (10) investigat-

ed immunocytochemical localization of human epidermal growth factor in several human tissues and they found no significant EGF in the normal thyroid tissue. The cause of this discrepancy is unknown. However, the present immunohistochemical study demonstrated no significant amount of EGF in normal thyroid tissues. Recent study indicated that c-erbB is a truncated form of the EGF-R gene and the content of EGF in the thyroid tissue is regulated by the EGF-receptor (4). Therefore, much attention have been paid to the relationship between EGF and various tumors such as thyroid carcinoma (12). Duh *et al.* (5) reported that the binding of EGF to thyroid neoplasm is higher than the normal thyroid tissue. It has been reported that both EGF and EGF-receptor are highly expressed in esophageal cancer (19). The present immunohistochemical study suggests that thyroid tissue of carcinoma contains more abundant EGF than that of the other non-neoplastic lesions. We found that normal arterial tissue contains more EGF than the arterial tissue with atherosclerotic lesions (unpublished data). Therefore, we have an impression that oncogenes are differently expressed depending upon types of tissues and

Table 2. Immunoreactivity for ras oncogene product in various types of thyroid tissues

Diagnosis	Number of cases	Immunoreactivity			
		++	+	-	
Normal	6	0/6	0/6	6/6	
Graves' disease	11	0/11	3/11	8/11	
Follicular adenoma	13	1/13	4/13	8/13	
Carcinoma	papillary	15	7/15	5/15	3/15
	follicular	2	2/2	0/2	0/2

++ : definitely positive, + : weakly positive, - : negative

Table 3. Immunoreactivity for myc oncogene product in various types of thyroid tissues

Diagnosis	Number of cases	Immunoreactivity			
		++	+	-	
Normal	6	0/6	1/6	5/6	
Graves' disease	11	0/11	2/11	9/11	
Follicular adenoma	13	3/13	3/13	7/13	
Carcinoma	papillary	15	6/15	4/15	5/15
	follicular	2	1/2	1/2	0/2

++ : definitely positive, + : weakly positive, - : negative

maturity of non-tumor and tumors.

It has been reported that members of the ras family of cellular oncogenes are most frequently detected in human solid tumors (14, 15). The result of present immunohistochemical study was consistent with the report by Yoshida *et al.* (25) that thyroid adenocarcinoma and adenoma express significantly more ras oncogene product than were seen in non-neoplastic diseases such as Graves' disease. Contrary to these results, Johnson *et al.* (9) reported that ras oncogene p21 antigen is expressed in inflammatory and non-neoplastic proliferative thyroid lesions as well as in benign and malignant thyroid tumors. They have also pointed out that monoclonal antibody reacts both with the pointmutated and proto-oncogene, and that it is unclear whether the increased products of oncogene in various thyroid lesions reflects point-mutation of the ras gene or enhanced expression of ras proto-oncogene.

The cellular myc oncogene is also one of the well known oncogenes which are expressed in human cancer tissues (1, 2, 16). Yamashita *et al.* (24) reported that normal thyroid tissues did not contain myc RNA sequences but that benign thyroid follicular adenoma and papillary thyroid cancer tissues possessed myc RNA sequences. On the other hand, Terrier *et al.* (20) reported that it is not clear that the frequent expression of c-myc in the most malignant thyroid cancer is the cause or the consequence of this malignancy. In the present study, both ras and myc oncogene products were more abundantly demonstrated in neoplastic thyroid tissues than in non-neoplastic thyroid tissues. These two oncogene products were also demonstrated in the transitional phase from fibrocellular intimal thickening lesions to atherosclerotic lesions of human coronary arteries (21), although the intensity of their reaction was weaker than that of the neoplastic thyroid tissue. Furthermore, we demonstrated myc oncogene product in the aortic tissues of the chick embryo and atherosclerotic lesion of the chicken aorta (22). Pfeiffer-Ohlsson *et al.* (13) speculated that the myc gene activity is not simply a marker of proliferative activity but reflects additional tissue specific gene regu-

lation operating during human embryogenesis.

Finally, the present data suggest that EGF, and ras and myc oncogenes play a role in thyroid neoplasia. Further study using molecular biological technique has been under way in our laboratory to examine whether the oncogene expression is qualitatively different in types of tissues and lesions or there exist complex interaction of oncogenes or some other factors are involved in carcinogenesis.

## REFERENCES

- 1) ALITALO, K., SCHWARB, M., LIN, C.C., VARMUS, H., and BISHOP, J.M. : Homogeneously staining chromosomal regions contain amplified malignant neuroendocrine cells from a human colon carcinoma. *Proc Natl Acad Sci USA* 80 : 1707-1711 (1983).
- 2) COLLINS, S., and GROUNDINE, M. : Amplification of endogenous myc related DNA sequences in a human myeloid leukemia cell line. *Nature* 298 : 679-681 (1982).
- 3) DER, C.J. : Cellular oncogenes and human carcinogenesis. *Clin Chem* 33 : 641-646 (1987).
- 4) DOWNWARD, J., YARDEN, Y., MAYES, E. SCRACE, G., TOTTY, N., STOCKWELL, P., ULLRICH, A., SCHLESSINGER, J., and WATERFIELD, M.D. : Close similarity of epidermal growth factor receptor and actin on human breast cancer cells in culture. *Cancer Res.* 44 : 3442-3447 (1984)
- 5) DUH, Q.Y., GUN, E.T., GEREND, P.L., RAPER, S. E., and CLARK, OH. : Epidermal factor receptors in normal and neoplastic thyroid tissue. *Surgery*. 98 : 1000-1007 (1985).
- 6) HEDINGER, C., and SOBIN, L.H. : Histological typing of thyroid tumors. In : International Histological Classification of Tumours, No. 11, World Health Organization, Geneva, 1974.
- 7) HIRATA, Y. and ORTH, D.N. : Epidermal growth factor (urogastron) in human tissues. *J Clin Endocrinol Metab* 48 : 667-672 (1979).
- 8) HIRATA, Y., MOORE, G.W., BESTAGNA, C. and ORTH, D.N. : Plasma concentrations of immunoreactive human epidermal growth factor (urogastron) in man. *J Clin Endocrinol Metab* 50 : 440-444 (1980).
- 9) JOHNSON, T.L., LLOYD, R.V., and THOR, A. : Expression of ras oncogene p 21 antigen in normal and proliferative thyroid tissues. *Am J Pathol* 127 : 60-65 (1987).
- 10) KESSELBERG, A.G., ORTH, D.N., GRAY, M.E., and STALMAN, M.T. : Immunocytochemical locali-

- zation of human epidermal growth factor/urogastrone in several human tissues. *J. Histochem. Cytochem.* **33** : 315-322 (1985).
- 11) LAND, H., PARADA, L.F., and WEINBERG, R.A. : Cellular oncogene and multistep carcinogenesis. *Science* **222** : 771-778 (1983).
  - 12) MIYAMOTO, M., SUNAGA, H., MORI, T., HASE, K., KUMA, K., and HIROO, I. : Epidermal growth factor receptors on cultured neoplastic human thyroid cells and effects of epidermal growth factor and thyroid-stimulating hormone on their growth. *Cancer Res.* **48** : 3652-3656 (1988).
  - 13) Pfeiffer-OHLSSON, S., RYDNERT, J., GOUSTIN, A.S., LARSON, E., BETSCHOLTZ, C. and OHLSSON, R. : Cell-type-specific pattern of myc proto-oncogene expression in developing human embryos. *Proc Natl Acad Sci. USA* **82** : 5050-5054 (1985).
  - 14) REDDY, E.P., REYNOLDS, R., SANTOS, E. and BARBACID, M. : A point mutation is responsible for the acquisition of transforming properties of T24 human bladder carcinoma oncogene. *Nature* **300** : 149-152 (1982).
  - 15) SANTOS, E., MARTIN-ZANCA, D., REDDY, E.P., PIEROTTI, M.A., DELLAPORTER, G. and BARBACID, M. : Malignant activation of a K-ras oncogene in lung carcinoma, but not in normal tissue of the same patient. *Science* **223** : 661-664 (1983).
  - 16) SHIBUYA, M., YOKOTA, J. and UYEYAMA, Y. : Amplification and expression of cellular oncogene (c-myc) in human gastric adenocarcinoma cells. *Mol Cell Biol* **5** : 414-419 (1985).
  - 17) SLAMON, D.J., DEKERNION, J.B., VERMA, I.M., and MARTIN, J.C. : Expression of cellular oncogenes in human malignancies. *Science* **224** : 256-262 (1984).
  - 18) STERNBERGER, L.A., HARDY, P.H., CUCULIS, J.J., and MEYER, H.G. : The unlabeled antibody enzyme method of immunohistochemistry preparation and properties of soluble antigen and antibody complex (horse radish-antihorseradish peroxidase) and its use in identification of spirochetes. *J. Histochem. Cytochem.* **18** : 314-333 (1970).
  - 19) TAHARA, E., SUMIYOSHI, H., and HATA, J. : Human epidermal growth factor in gastric carcinoma as a biologic marker of high malignancy. *Jpn. J. Cancer Res. (Gann)*. **77** : 145-152 (1986)
  - 20) TERRIER, P., SHENG, Z.-M., SCHLUMBERGER, M., TUBIANA, M., CAILLOU, B., TRAVAGLI, J.-P., FRAGU, P., PARMENTIER, C., and RIOU, G. : Structure and expression of c-myc and c-fos proto-oncogenes in thyroid carcinomas. *Br. J. Cancer* **57** : 43-47 (1988).
  - 21) TODA, T., NAGAMINE, M., TAKEI, H., and SEITETSU, H. : Oncogene expressions in coronary atherosclerotic lesions in man. *J Jpn. Atheroscler Soc.* (in press).
  - 22) TODA, T. : Immunohistochemical demonstration of myc gene product in chick embryo aorta and atherosclerotic lesions in chickens. *Acta Med. Nagasaki* (in press).
  - 23) WATSON, J.D., HOKINS, N.H., ROBERTS, J.W., STETZ, J.A., and WEINER, A.M. : Molecular biology of the gene. Menlo Park, California. 1987.
  - 24) YAMASHITA, S., ONG, J., FAGIN, J.A., and MELMED, S. : Expression of the myc cellular protooncogene in human thyroid tissue. *J Clin Endocrinol Metab.* **63** : 1170-1173 (1986).
  - 25) YOSHIDA, K., HAMATANI, K., KOIDE, H., IKEDA, H., NAKAMURA, N., AKIYAMA, M., TSUCHIYAMA, H., NAKAYAMA, E., and SHIKU, H. : preparation of anti-ras Mr 21,000 protein monoclonal antibodies and immunohistochemical analyses on expression of ras genes in human stomach and thyroid cancers. *Cancer Res.* **48** : 5503-5509 (1988).