

Double Staining Method for Identification of Cyst Walls and Intracystic Bodies of *Pneumocystis carinii* in Histologic Sections

Masachika SENBA

Department of Pathology, Institute of Tropical Medicine,
Nagasaki University, Nagasaki 852, Japan

Received for publication, December 26, 1987

SUMMARY : The acquired immune deficiency syndrome (AIDS) is characterized by opportunistic infections including pneumonia caused by *Pneumocystis carinii*. As a staining method for *Pneumocystis carinii*, modified Grocott's methenamine silver method has been used routinely. This procedure can identify the cyst walls of *Pneumocystis carinii*, but, can not identify the intracystic bodies of *Pneumocystis carinii*. The author has applied the method using ammoniacal silver and Giemsa staining, and found that this is a consistently reliable staining procedure for the cyst walls and intracystic bodies of *Pneumocystis carinii*. Moreover, this new method may detect mature and immature cysts of *Pneumocystis carinii*.

INTRODUCTION

In the AIDS patients, established *Pneumocystis carinii* pneumonia may not produce the typical chest film with interstitial or inter-alveolar infiltrates. The increase in the incidence of *Pneumocystis carinii* in association with AIDS, as well as its prevalence in other immunocompromised hosts, have made apparent the necessity for a specific stain for its diagnosis.

Many methods have been developed for the purpose of staining *Pneumocystis carinii* in paraffin sections, including Grocott's methenamine silver,⁵⁾ modified Grocott's methenamine silver,^{3, 8)} toluidine blue O,²⁾ cresyl echt violet,¹⁾ and ammoniacal silver.^{4, 6, 7)}

These methods have been used for staining the cyst walls of *Pneumocystis carinii*, but not for the intracystic bodies of *Pneumocystis carinii*. On the other hand, Giemsa method have been used for the intracystic bodies of

Pneumocystis carinii staining. I propose a new method using ammoniacal silver and Giemsa staining for the identification of both the cyst walls and the intracystic bodies of *Pneumocystis carinii*.

MATERIALS AND METHODS

The lung specimens from the autopsy cases of *Pneumocystis carinii* infection were used. The materials were fixed in formalin and embedded in paraffin.

The steps involved in a new method for both the cyst walls and intracystic bodies of *Pneumocystis carinii* are as follows : (1) Deparaffinize and hydrate in distilled water. (2) Treat with oxidizing solution for 2 minutes. Oxidizing solution : Dissolve 0.3g of potassium permanganate in 100 ml of distilled water and add 0.3 ml of sulfuric acid. (3) Wash in running water. (4) Treat with 2% oxalic acid solution until sections become clear. (5) Wash in running water. (6) Treat with 2% ferric

ammonium sulfate solution for one minute. (7) Wash in running water. (8) Treat with ammoniacal silver solution for 2 minutes. Ammoniacal silver solution : To 20 ml of 10% silver nitrate solution add 0.4g of sodium hydroxide, and then dropwise 28% ammonium hydroxide, until only a few granules of the resulting precipitate remain on the bottom of the cylinder. And add distilled water to make 100 ml. Dilute one part of ammoniacal silver solution with four parts of distilled water for use. Store in the refrigerator and use as needed. (9) Wash in distilled water for 30 seconds. (10) Treat with 95% alcohol solution for one second. (11) Treat with 5% formalin for one minute. (12) Wash in running water. (13) Treat with 0.5% gold chloride for 2 minutes. (14) Wash in running water. (15) Treat with 2% oxalic acid solution for 2 minutes. (16) Wash in running water. (17) Treat with 10% sodium thiosulfate solution for 2 minutes. (18) Wash in running water. (19) Giemsa solution for one hour. Giemsa solution : Mix 6 ml of Giemsa solution with 94 ml of distilled water. (20) Wash in distilled water for 2-3 seconds. (21) Differentiate with 0.5% acetic acid solution for 3-5 seconds. (22) Treat with absolute alcohol for 2-3 minutes. (23) Treat with 100% iso-propyl alcohol solution for 2 changes, 30 seconds each. (24) Treat with xylene for 3 changes, and mount.

RESULTS

Cyst walls of *Pneumocystis carinii* were stained black by ammoniacal silver. Intracystic bodies of *Pneumocystis carinii* were stained blue with Giemsa (Fig. 1). Occasionally, the cyst walls of *Pneumocystis carinii* were stained blue which had empty structure in the cysts (Fig. 2). Fungi and reticulum fibers were stained black, but the cytoplasm was not stained with silver particles. This new method could identify not only the cyst walls of *Pneumocystis carinii* but also intracystic bodies of *Pneumocystis carinii*.

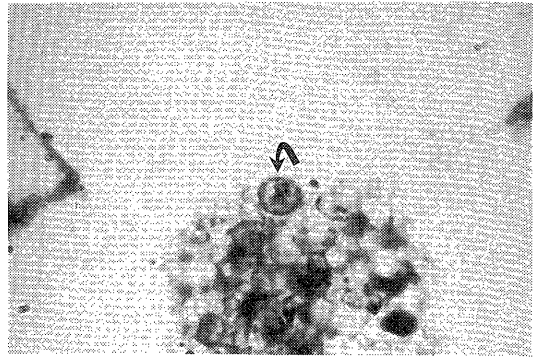


Fig. 1. Cyst walls and intracystic bodies of *Pneumocystis carinii* in the alveolar spaces (arrow). Ammoniacal silver and Giemsa stain ($\times 1,000$).

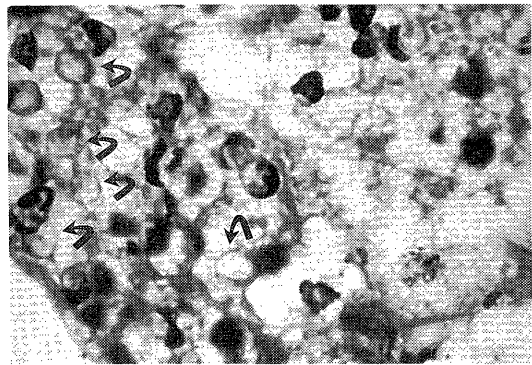


Fig. 2. Most of cyst walls of *Pneumocystis carinii* are stained black which show typical round, oval and crescent forms. Occasionally, the cyst walls of *Pneumocystis carinii* are stained blue which have empty structure in the cysts (arrows). Ammoniacal silver and Giemsa stain ($\times 1,000$).

DISCUSSION

Immunocompromised patients and those afflicted with AIDS at high risk for *Pneumocystis carinii* pneumonia have increased in numbers and require immediate diagnosis and treatment. Histopathological identification of the microbe is essential for diagnosis, thus, a reliable and an understandable staining procedure is important as an available diagnostic method.

Of the various methods for demonstrating *Pneumocystis carinii*, Grocott's modification

of Gomori's methenamine silver procedure is widely used but it occasionally fails to stain *Pneumocystis carinii*. Recently, Churukian and his co-workers (1986) pointed out what affects the quality of the stain is the age of the stock methenamine silver solution which gradually increases in background staining. Therefore, methenamine silver solution can not be stocked. However, ammoniacal silver solution may be stocked for several months in the refrigerator, which does not lead to any background tissue staining. Thus, it has been found that constant and satisfactory results can be obtained by ammoniacal silver and Giemsa procedure. Moreover, this method can detect both the cyst walls and the intracystic bodies of *Pneumocystis carinii*.

REFERENCES

- 1) BOWLING MC, SMITH IM, Wescott SL : A rapid staining procedure for *Pneumocystis carinii*. *Am. J. Med. Technol.* **39** : 267-268, 1973.
- 2) CHALVARDJIAN AM, GRAWE LA : A new procedure for the identification of *Pneumocystis carinii* cysts in tissue sections and smears. *J. Clin. Pathol.* **16** : 383-384, 1963.
- 3) CHURUKIAN CJ, SCHENK EA : Rapid Grocott's methenamine-silver method for fungi and *Pneumocystis carinii*. *Am. J. Clin. Pathol.* **68** : 427-428, 1977.
- 4) CHURUKIAN CJ, SCHENK EA, CLARK G : Dilute ammoniacal silver as a substitute for methenamine silver to demonstrate *Pneumocystis carinii* and fungi. *Lab. Med.* **17** : 87-90, 1986.
- 5) GROCCOTT RG : A stain for fungi in tissue sections and smears using Gomori's methenamine-silver technic. *Am. J. Clin. Pathol.* **10** : 177-179, 1946.
- 6) SENBA M : A reliable silver staining method for *Pneumocystis carinii* and reticulum fibers in histologic sections. *Acta Histochem. Cytochem.* **16** : 169-171, 1983.
- 7) SENBA M : A selective silver staining method for identification of *Pneumocystis carinii* in histologic sections. *Jpn. J. Parasitol.* **34** : 525-526, 1985.
- 8) SMITH JW, HUGHES WT : A rapid staining technique for *Pneumocystis carinii*. *J. Clin. Pathol.* **25** : 269-271, 1972.