

## Application of double stapling technique after anterior resection for rectal cancer

Masumi IFUKU, Fusao KUBOTA, Hiroyuki MINAMI,  
Takaaki KAWAFUCHI, Keiji KAJIWARA,  
Noriaki ITOYANAGI, Hiroshi SINGUU,  
Tohru NAKAGOE\*, Haruhiko NAKAO\*, Tatsuo HIRANO\*,  
Takatoshi SHIMOYAMA\*, Toshio MIURA\*, Masao TOMITA\*

*Department of Surgery, Sasebo Municipal Hospital  
The First Department of Surgery, Nagasaki University School of Medicine\**

*Received for publication, June 30, 1988*

**SUMMARY :** Double stapling technique (DST) were applied in 22 cases who underwent low and high anterior resection of the rectum.

Postoperative complications were encountered in six, three were mild strictures and the other three were minor leakages. All were not severe, demonstrating no correlation to the conditions of the anastomosis and subsided by conservative therapy in a short period.

Anastomotic leakage occurred in three but these were based on technical problems and it is possible to avoid with careful surgical management.

In conclusion, DST is of great benefit for the treatment of carcinoma of the rectum to reduce the consuming operation time and to lessen the risk of bacteriological and oncological contaminations.

### INTRODUCTION

Stapled anastomoses have become popular to allow the continuity of the digestive tract after a resection of the gut. Anterior resection for rectal cancer is a preferable surgical method to preserve the sphincter function of the anus. In 1980 GRIFFEN<sup>1)</sup> proposed a modification of the original procedure as described by RAVITCH<sup>2)</sup> in 1979 and first reported the use of two staples (one linear and the other circular) for low end-to-side colorectal anastomoses. This technique seems to be advantageous for saving operative time, preventing contamination in the operative field and implantation of the neoplastic cells.

This paper reports the technical results obtained in our clinics and aims at lessening the complication related to colorectal anastomoses.

### PATIENTS

Twenty-two patients with double stapling technique (DST) for anastomosis following anterior resection for rectal cancer were subjected to this study. Double stapling comprised of two kinds of the instruments; linear stapler (LS 60, Johnson and Johnson Co. or TA 55, Century Medical Co.) and circular one (ILS 33, Johnson and Johnson Co.).

Linear stapler is positioned around the distal resected line of the rectum. The use of this

stapler is advantageous with respect to leaving the resected margin as distal to the tumor mass as possible and to avoiding contamination by opening the gut lumen.

The circular stapling is used for anastomosis between the proximal colon and distal rectum. Application of the circular stapling is made by one of the two ways, in which one is pierced in the middle of the linear stapling line, the other is at the edge of it, using the lateral wall of the rectum and avoiding misjointing the two stapling lines each other.

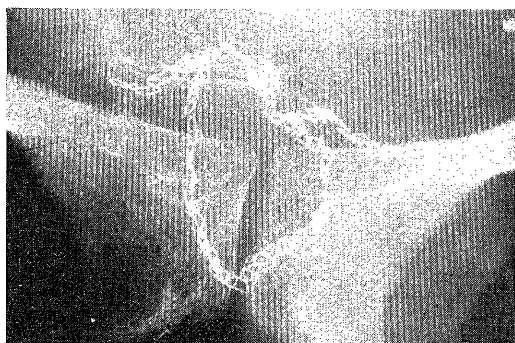


Fig. 1. Fluoroscopic finding showing double stapled line in which the circular stapler was applied in the middle of the linear stapled one

After operation, the endoscopic and fluoroscopic follow-up and CEA monitoring also were routinely used and the postoperative course were carefully made to clarify as to whether the stenosis and minor leakage at anastomosis took place.

## RESULTS

During the past two years from Jan. 1986 to Dec. 1987, DST for the treatment of rectal cancer was used in the 22 cases in the First Department of Surgery, Nagasaki University Hospital. DST were applied following 15 anterior low and seven anterior high resections for rectal cancers. Linear stapling instrument of LS 60 (Johnson and Johnson) was applied in eight and that of TA 55 (Century Medical) was used in 14 respectively. On the other hand, circular stapling instrument of ILS 33 (Johnson

and Johnson) were used in all 22 cases.

The distance of the anastomosed sites from the anal verges ranged from 3 cm to 18 cm, within 5 cm in four, 5 to 10 cm in 10, and over 10 cm in eight respectively.

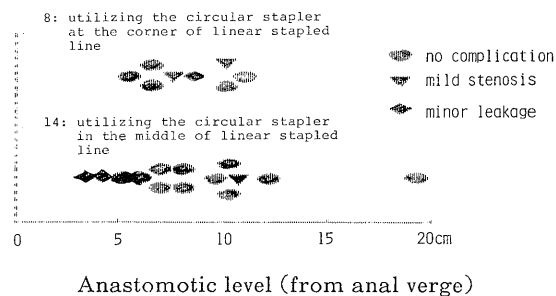


Fig. 2. Relationship the distance of the site of stapled anastomosis from the anal verge and postoperative complication of mild stenosis and minor leakage between the two groups that the circular staplers were applied in the middle or at the corner of the circular stapled lines

The postoperative complications were encountered in six, three were minor leaks at anastomosis and the other three were mild stenosis. No one required reoperation and these subsided by the conservative therapy in a short period within one month.

To avoid crossing the two stapled lines, in eight out of the 22 cases the circular stapler was applied to the corner of the linear stapled line. However, the incidence of postoperative complication of stenosis was not necessarily avoidable even by this consideration. Anastomosis leakage occurred in the two cases with the anastomoses adjacent to the anal verge. The causes of anastomosis leakage in three were considered as shown in Table 1. One was based on the thickened wall of the rectum due to surgical technique which intended to keep the wall of the rectum in good blood perfusion, the other two were attributed to the inadequate handling of the staplers. It is possible that these were technically avoidable with care.

**Table 1.** Causes of anastomotic leakage in 3 cases

1. 58 yrs	M	thickened rectal wall due to inadequate preoperation for fear of ensuing poor blood supply
2. 51 yrs	M	inappropriate edge of the rectum due to incorrect cut-off after removing the linear stapler
3. 41 yrs	F	injury to linear stapled line when introducing the circular stapler

## DISCUSSION

The advantages of double stapling technique were that first, the resected lower margin could be secured as far a distance from the tumor margin as possible, and second, needless to say, this procedure could reduce danger of intraoperative contamination<sup>1)3)</sup> by avoiding the opening of the colonic lumen on dealing with the stump of the rectum.

When DST is not used, the stump of the rectum used to be closed by a purse string suture. This maneuver is frequently restricted to the limited operative field by the pelvis and is not always replaced by a manual suture. Furthermore, GRIFFEN<sup>1)</sup> and COHEN<sup>3)</sup> stressed that the main source of complications in such a surgery arises during a period of an operative maneuver to deal with the opening stump of the rectum.

Meanwhile, DST can lower the risk of possible ischemia on the anastomosed wall of the colon and contamination for the operative field. In addition, it is possible to make a resection margin downwards by pushing down the linear stapler to the rectum. It makes the resected ranges wider and prevent implantation of exfoliated tumor cells around the anastomosis<sup>4)</sup>. And also it results in reducing the con-

suming operation time. Consequently it follows that surgical results become much improved. Minor anastomotic leakage was seen in three. However, it spontaneously cured by nutritional support within a three week duration. The reasons for minor leakage are considered in all three cases with avoidable inadequacy of preparation of the colonic and rectal walls for stapling. First of all, as to DST we feared that wound healing on crossing the two sutured lines may be impaired. We tried not to cross the two stapled lines by using the corner of the linear stapled line in the eight cases. Postoperative stricture was not necessarily reduced by using the corner of the suture line that the linear stapler was applied. From a result of this study, the sites of application of the two staplers did not relate to the incidence of the postoperative complications. It is reasonable to emphasize that gentle handling of the bowel is required to lessen the operative trauma as well as to avoid the postoperative complications and double stapling technique is of great use for the treatment of carcinoma of the rectum in considering the acceptable incidence of postoperative complications.

## REFERENCE

- 1) GRIFFEN FD, KNIGHT C : Low rectal anastomosis with the EEA stapler. *Surg. Rounds* 1983, Sept 18-26.
- 2) RAVITCH MM, STREICHEN FM. A stapling instrument for end-to-end inverting anastomoses in the gastrointestinal tract. *Ann. Surg.* 189 : 791-797, 1979.
- 3) COHEN Z, MYERS E, LANGER B *et al.* : Double stapling technique for low anterior resection. *Dis Col Rect.* 26 : 231-235, 1983.
- 4) UMPLEBY HC, FERMORE B, SYMONS MD *et al.* : Isolation of viable exfoliated colo-rectal cancer cells at the site of intestinal transection. *Br. J. Surg.* 70 : 680-685, 1983.