

Hepatic Resection by combined Use of Microwave Tissue Coagulator and C.U.S.A. System under Intraoperative Ultrasonographic Guidance

Masato FURUKAWA, MD. PhD. Kenya CHIBA, MD.
Toshinori NAKATA, MD. Masayuki SETOGUCHI, MD. PhD.
Toshiomi KUSANO, MD. Yiqin LIN, MD. Kazunori TASHIRO, MD. PhD.

*Department of Surgery,
Nagasaki Chuo National Hospital*

Received for publication, December 11, 1987

SUMMARY : To control the bleeding during hepatic resection, especially in the patients with liver cirrhosis, is an extremely important factor to prevent the development of postoperative hepatic failure.

For this purpose, we have been using a hepatic resection method combining the use of a microwave tissue coagulator and intraoperative ultrasonic examination and the cavitron ultrasonic surgical aspiration system in recent years.

In this procedure, first, the liver is dissected to decide which part to resect using the intraoperative ultrasonography. Second, the hepatic parenchym is coagulated by Microwave. Third, the coagulated necrotic tissues are emulsified and aspirated by C.U.S.A. Fourth, the liver is resected by carefully ligating and dividing the remaining vessels.

This procedure made it possible to control completely the bleeding from liver parenchym during hepatic resection.

We also emphasized that C.U.S.A. were well applicable for hepatic resection even in cirrhotic liver when it followed microwave tissue coagulation.

I INTRODUCTION

In the hepatic resection, especially of the cirrhotic liver, hemorrhage and blood transfusion in large quantities usually induce abnormality in postoperative coagulation or other complications, significantly influencing prognosis.

In this respect, control of intra- and postoperative hemorrhage has been a most important problem.

We have been using a hepatic resection method combining the use of a microwave tissue

coagulator (hereinafter called Microwave), intraoperative ultrasonic examination and the cavitron ultrasonic surgical aspiration system (C.U.S.A.) in recent years. This paper introduces a hepatic resection technique using our "Muc Hepatectomy" and reports on the results of 10 cases treated with this method.

II MUC HEPATECTOMY

Muc Hepatectomy proceeds in the following procedure.

First, the liver is dissected to decide which

part to resect using the intraoperative ultrasonography. Second, the hepatic parenchyma is coagulated by Microwave. Third, the coagulated necrotic tissues are emulsified and aspirated by C.U.S.A. Fourth, the liver is resected by carefully ligating and dividing the remaining vessels.

Muc Hepatectomy is applicable to hepatic resection of various diseases such as hepatic cancer, hepatic hemangioma and hepatic cysts. This paper reports how to use it in the systemic sub-segmentectomy of the liver for hepatic cancer. (Fig. 1)

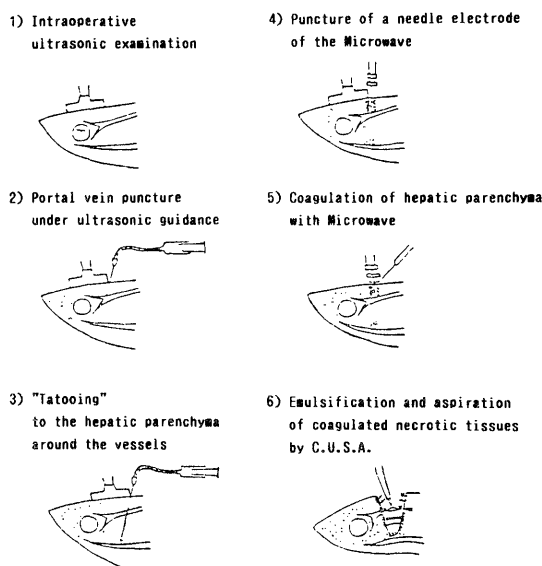


Fig. 1. MUC Hepatectomy

1) Abdominal incision

Abdominal incision is mainly performed with subcostal transverse incision, but if it is not sufficient, upper midline incision or sometimes median inferior partial sternotomy is added, followed by the lift of a costal bow using a lifting retractor.

After then, mobilization of the liver is performed to expose a hepatic cancerous segment and to give enough space for a needle electrode of Microwave to puncture.

2) Intraoperative ultrasonic examination

The portal vein is searched for the location and segment of the tumor, and the existence of a tumorous embolus from the main trunk to the branches in the portal vein, and from the

inferior vena cava to the hepatic veins inside of the liver. In addition, where to inject the dye in the portal vein is decided, which becomes a focus point. (Fig. 1-1)

3) Portal vein puncture under ultrasonic guidance

By searching the hepatic surface with an intraoperative ultrasonic probe in the left hand, the focus point is decided, and the point is punctured with a Cathelin's needle connected to an injector with an extension tube in the right hand. Puncture should be directed to the tumor.

After confirming that the portal vein blood is coming into the injector held by an assistant when the needle enters the portal vein, methylene blue is injected to stain the segment of the liver.

The inflow of the dye to the portal vein is observed on the ultrasonic monitoring screen. The injection should be slowed down as much as to coordinate with a portal vein blood flow. (Fig. 1-2)

4) "Tattooing" to the hepatic parenchyma around the vessels

Hepatic parenchyma around the vessels are tattooed to mark the devided lines of the hepatic veins, portal veins and biliary duct for systemic sub-segmentectomy. (Fig. 1-3)

5) Coagulation of hepatic parenchyma with Microwave

A needle electrode of the Microwave is punctured along the rim of the stained segment(sub-segment) marked by dye injection into portal veins (Fig. 2). Needling of the electrode should follow the ultrasonic guidance, under which the direction and depth are decided, and the length of the electrode are selected. The electrode is directed to the focus point of the portal vein. (Fig. 1-4, Fig. 3)

If the needling stops 1 cm away from the vessels without entering directly into large vessels, hemorrhage and leakage of bile from the needle hole can be prevented.

Coagulation has been performed with 60 to 80 watts for 20 to 40 seconds, but a slightly higher wattage is recommended for cirrhotic liver.

Depolarization follows, which is repeated at

an 2 cm interval along the entire rim of the stained segment. (Fig. 1-5) This coagulation with Microwave enables to isolate a cancerous segment from noncancerous part.

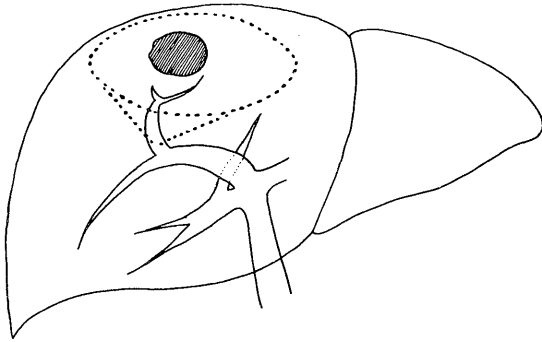


Fig. 2. The cone shape area which enclose the tumor (shown in dotted line) is resected

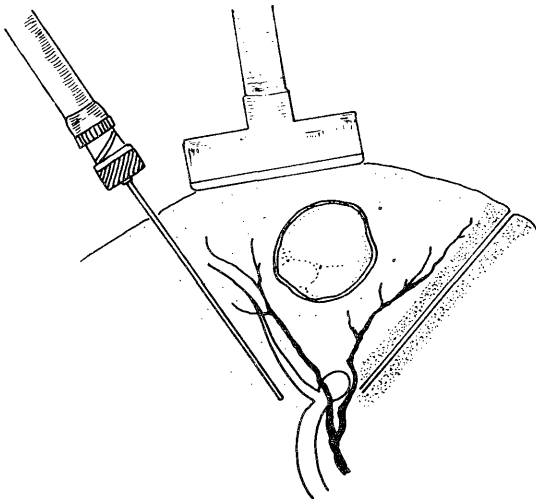


Fig. 3. Needling Microwave electrode.
A needle is inserted to the portal focus point along the cut line.

6) Emulsification and aspiration of coagulated necrotic tissues by C.U.S.A. (Fig. 1-6)

Hepatic parenchymal tissues coagulated and necrosed by Microwave are emulsified and aspirated by C.U.S.A. (Fig. 4) Therefore, vessels, as small as thread to large ones, can be exposed 1 mm wide almost without hemorrhage. (Fig. 5)

This technique enables to leave the portal veins, hepatic arteries, hepatic veins and biliary ducts more than 5 mm large intact, so that the small vessels can be carefully ligated and divided

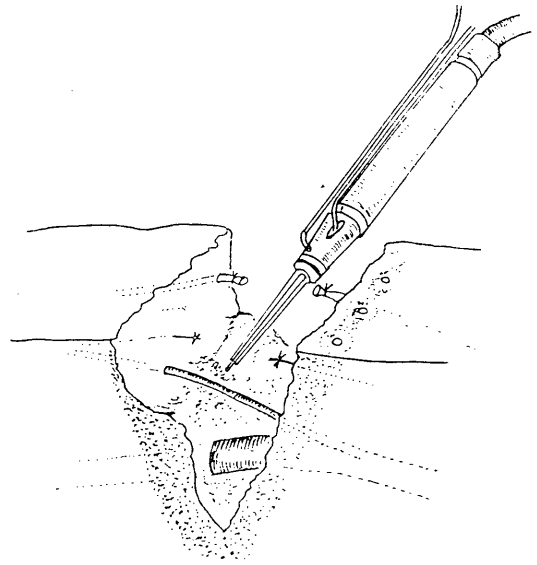


Fig. 4. Coagulated necrotic tissue are emulsified and aspirated by C.U.S.A.

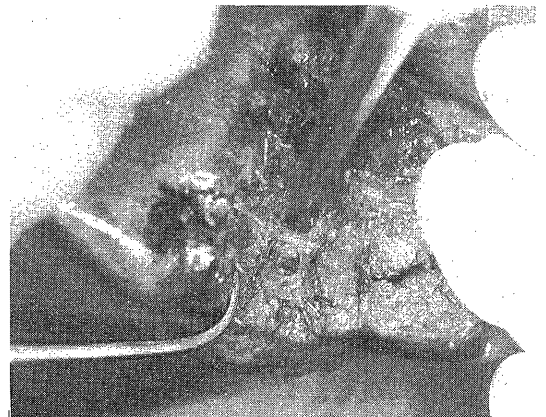


Fig. 5. Vessels can be exposed 1 mm wide almost no hemorrhage.

one by one with hemoclips or silk suture, resulting in prevention of postoperative hemorrhage and bile leakage.

The emulsification and aspiration by C.U.S.A. are repeated in such a manner and proceeded to the hepatic parenchyma around the vessels previously marked with dye, until reaching the hepatic section border.

Treatment of this part completes sub-segmentectomy of the liver including the tumor.

III RESULTS

We treated 13 cases of hepatic resection from January to December 1984, of which 3 cases under hepatic resection with the conventional controlled method and 10 others with Muc Hepatectomy. Among them, 3 cases complicated with hepatic cirrhosis and 1 non-complicated case were treated with systemic sub-segmentectomy using Muc Hepatectomy. (Table 1)

The volume resected (average \pm SD) was 71.5 \pm 56.9 g in the Muc Hepatectomy group (A group) and 83.3 \pm 89.6 g in the controlled method group. (B group), showing no difference, while the average intraoperative hemorrhage was 292.2 \pm 212.9 ml in the A group and 2087 \pm 332.3 ml in the B group, demonstrating that the A group is significantly lower in hemorrhage by about one-seventh. As a result, all the cases in the B group required blood transfusion compared to only a half of the cases in the A group.

In addition, drainage tubes were removed earlier after operation in the A group, since almost no hemorrhage and bile leakage occurred.

Table 1. Cases of hepatic resection

(A) "MUC" Hepatectomy

| Case | LC | Resected segment (Couinaud) | Specimen (g) | Blood loss for MUC (ml) | Blood transfusion |
|------|----|-----------------------------|--------------|-------------------------|-------------------|
| 1 | + | S 2, 3 | 42 | 223 | - |
| 2 | + | S 8 | 35 | 525 | + |
| 3 | + | S 6 | 18 | 355 | - |
| 4 | - | S 5 | 70 | 687 | + |
| 5 | - | S 5 | 30 | 33 | - |
| 6 | - | S 6 | 220 | 285 | + |
| 7 | - | S 5 | 90 | 22 | - |
| 8 | - | S 2, 3 | 30 | 84 | - |
| 9 | - | S 2, 3 | 70 | 207 | + |
| 10 | - | S 2, 3 | 110 | 501 | + |
| | | | 71.5 | 292.2 | |
| | | | \pm 56.9 | \pm 212.9 | |

(B) "Controlled method" Hepatectomy

| Case | LC | Resected segment (Couinaud) | Specimen (g) | Blood loss for MUC (ml) | Blood transfusion |
|------|----|-----------------------------|--------------|-------------------------|-------------------|
| 11 | + | S 7 | 19 | 2557 | + |
| 12 | - | S 8 | 21 | 1850 | + |
| 13 | - | S 6 | 210 | 1854 | + |
| | | | 83.3 | 2087 | |
| | | | \pm 89.6 | \pm 332.3 | |

LC : liver Cirrhosis

IV DISCUSSION

For control of hemorrhage at a time of hepatic resection, the controlled method and Pringle's method have been widely used. However, ischemic condition of the liver caused by clamping of the vessels at the hepatic hilum at the resection of the cirrhotic liver delays the recovery of postoperative hepatic function, causing postoperative complications. It is therefore desirable that the control of hemorrhage at the hepatic hilum is avoided as much as possible.

Hepatectomy improved by the use of apparatus such as Microwave and C.U.S.A. has lessened hemorrhage.

A technique using C.U.S.A. rarely needs control of hemorrhage at the hepatic hilum. However, in case of cirrhotic liver, it injures the blood vessels, increasing hemorrhage. Therefore, it has not been used by itself. The Microwave technique alone makes the dissection of vessels and careful ligation difficult. Especially it leaves a problem of closing the cut end of the bile ducts and necessitates drainage tubes for a postoperative bile leakage for a long time.

To cope with such problems, we have developed Muc Hepatectomy, a hepatic resection technique utilizing the advantages of Microwave and C.U.S.A. There have been reports on hepatic resection techniques combining C.U.S.A. and Microwave. They use Microwave for the shallow layer of the liver and C.U.S.A. for the deep layer.

Our Muc Hepatectomy basically differs from them. Our procedure is that hepatic parenchymal tissues are coagulated by Microwave and then emulsified and aspirated by C.U.S.A. After then the remaining vessels are carefully ligated and divided.

In addition, in our Muc Hepatectomy, the C.U.S.A. which has been considered unapplicable to the resection of the cirrhotic liver was used to emulsify and aspirate coagulated necrotic tissues. The use of C.U.S.A. was proved to be effective in decreasing intraoperative hemorrhage.

Table 1 shows the summary and results of our treated cases. Compared to the three cases treated with the conventional controlled method, our method significantly decreased intraoperative hemorrhage regardless the resectional volume even in the cases complicated with hepatic

cirrhosis, with 50% of the cases requiring no blood transfusion. Almost no bile was observed in the drainage tubes fixed at the resected surface and the drainage tubes were removed soon after operation.

The 10 cases operated with Muc Hepatectomy developed no complications. Disadvantages of our method are: there is some part where a needle electrode of Microwave cannot reach even if the liver is sufficiently mobilized, and it is naturally difficult to be applied in areas close to large vessels.

V CONCLUSION

We introduced a systemic sub-segmentectomy technique using a hepatic resection method "Muc Hepatectomy" combining Microwave, intraoperative Ultrasonic examination and C.U.S.A. are reported its effectiveness.

"Muc Hepatectomy" could significantly decrease intraoperative hemorrhage, which is the most important problem at hepatic resection, even if control of hemorrhage at the hepatic

hilum was omitted. It could also decrease post-operative complications such as bile leakage. In addition, our method proved a possibility of the use of C.U.S.A. at resection of the cirrhotic liver which had been considered impossible. Our Muc Hepatectomy will find many applicable ways in the future.

REFERENCES

- 1) Y. KASAI, M. NAKANISHI, H. SANO, *et al.* Fundamental procedure of the hepatic resection. *Gastroenterological Surgery*; **9**: 429-436, 1982
- 2) M. RYU, Y. WATANABE, and H. SATO. CUSA system-application for hepato-biliary tract surgery. *Jap. J. Clinical Medicine*; **31**: 2375-2379, 1982
- 3) M. RYU, and H. SATO. The practice of medical instruments for hepatic resection. *Surg Diag Treatm (Tokyo)*; **25**: 58-63, 1984
- 4) M. MAKUUCHI, H. HASAGAWA, and S. YAMASAKI. Department on segmentectomy and subsegmentectomy of the liver due to introduction of Ultrasonography. *J. Jap. Surg. Soc*; **84**: 913-916, 1983