

Transcatheter Embolization for Systemic-pulmonary Artery Collaterals after Correction of Extreme Tetralogy of Fallot

Toshio ONITSUKA, Yasunori KOGA, Koichiro SHIBATA,
Kiyoshi ISHII, Takami MAEDA, Yasunori MATSUZAKI,
Tsutomu YONEZAWA, Makoto YOSHIOKA and Yuji WAKUTA*

*The Second Department of Surgery, Miyazaki Medical College,
Miyazaki, Japan*

**The Radiology, Miyazaki Medical College,
Miyazaki, Japan*

Received for publication, June 30, 1985

The selective obliteration of systemic-pulmonary arterial collaterals by wire coil embolization, usually recognized in cyanotic congenital disease, is described in this report. A 11 year-old boy, who had received Blalock-Taussig shunt for extreme tetralogy of Fallot (TOF) at 1.5 year-old, had total correction and ligation of Blalock-Taussig shunt. After cardiac surgery, two times successful collateral transcatheter embolizations were performed for difficulty of weaning from left heart failure.

We stressed that post operative transcatheter embolization was very effective and had many merits in these cases than the ligations of collaterals by means of thoracotomy.

INTRODUCTION

The association of well developed systemic-pulmonary collateral blood vessels is widely recognized in cyanotic congenital heart disease with extreme TOF.

If left unattended, maintenance of adequate perfusion pressure is difficult and achieving optimal surgical exposure without circulatory arrest is at times impossible because of the voluminous cardiac return of blood which leads to flooding of the operative field.

We report the post operative case of transcatheter embolization introduced by GIAN-TURCO *et al.*¹⁾ for the systemic-pulmonary collateral vessels because of difficulty of leaving left heart failure due to shunt flow.

鬼塚 敏男, 古賀保範, 柴田絃一郎, 石井 潔, 前田 隆美, 松崎 泰憲, 米沢 勤, 吉岡 誠,
涌田 裕司

Correspondent: Toshio ONITSUKA, The Second Department of Surgery, Miyazaki Medical College, Kiyotake, Miyazaki, 889-16, Japan.

CASE REPORT

A 11 year-old boy with extreme TOF, who had received a left Blalock-Taussig anastomosis when he was 1.5 years of age was admitted. Physical examination revealed cyanosis, clubbed finger and a Grade 2/6 continuous murmur at the left sternal border of the second intercostal space. Red blood cell count was $592 \times 10^4/\text{mm}^3$, and the hemoglobin value was 19.3 g/dl. The electrocardiogram showed right ventricular (RV) hypertrophy and cardio-thoracic ratio(CTR) was 55 per cent. Cardiac catheterization and cardiac angiogram revealed a pulmonary atresia, and pulmonary artery was demonstrated via Blalock-Taussig anastomosis and aortic-pulmonary collateral shunt (Fig. 1). The recorded pressure were as follows, RV pressure 175/0 mmHg (mean 75), aortic pressure 130/90 mmHg (mean 100).

The operation was performed with cardiopulmonary bypass, hypothermia and aortic root intermittent infusion of a cold blood GIK (glucose, insulin, potassium) following YOUNG's solution, and topical cooling in the pericardial cavity using ice slush was made as myocardial protection. After ligation of the Blalock-Taussig shunt, the ventricular septal defect was closed with a Dacron patch and RV outflow tract plasty was made by porcine pericardial patch with single valve (Polistan Co.) beyond the pulmonary valve.

Severe congestive left heart failure due to left to right shunt flow with low cardiac output persisted postoperatively. Two major systemic-pulmonary collateral vessels were subsequently occluded by transcatheter embolization with spring embolus on the 10th and 15th days after open heart surgery. The spring embolus was showed in Fig. 2.

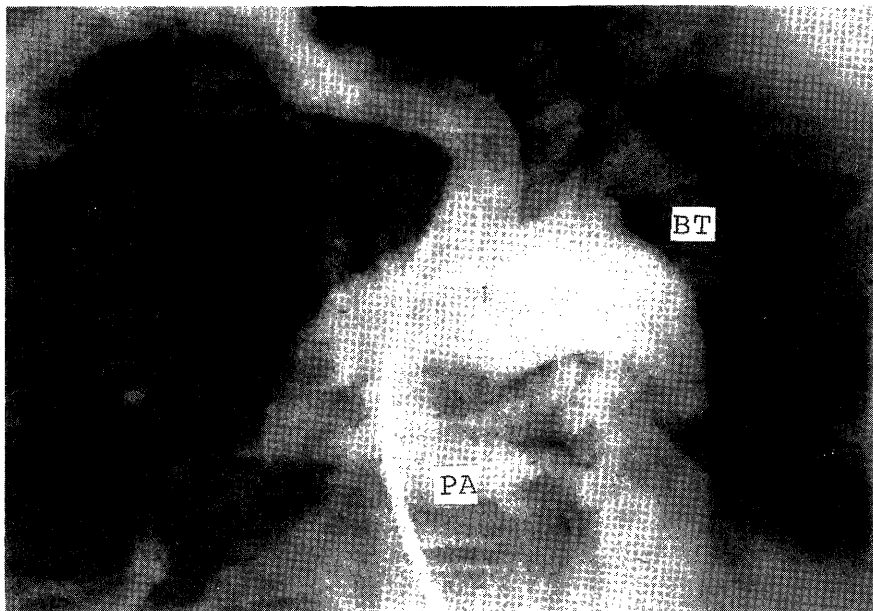


Fig. 1. Pre-operative aortogram
BT: Blalock-Taussig shunt
PA: Pulmonary artery

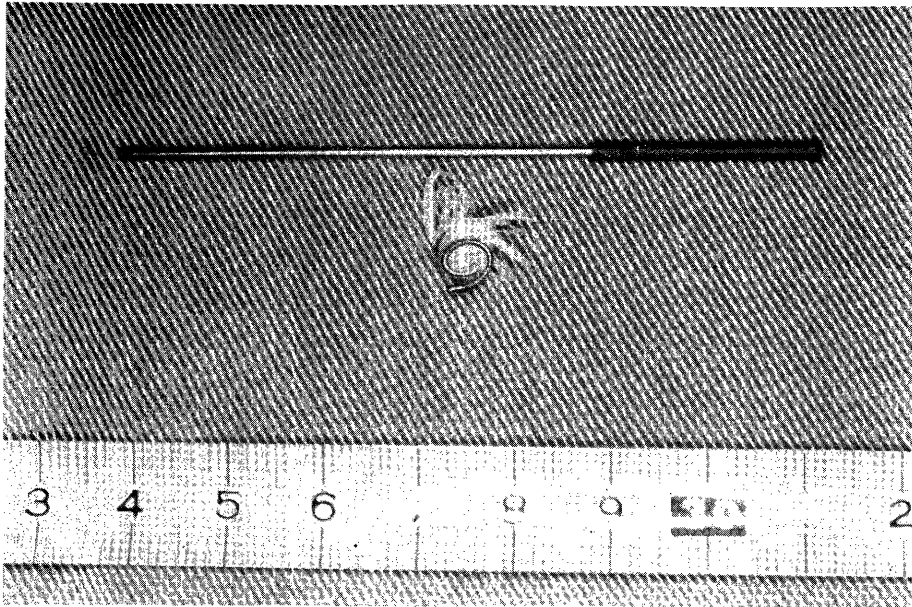


Fig. 2. Spring embolus and cartridge

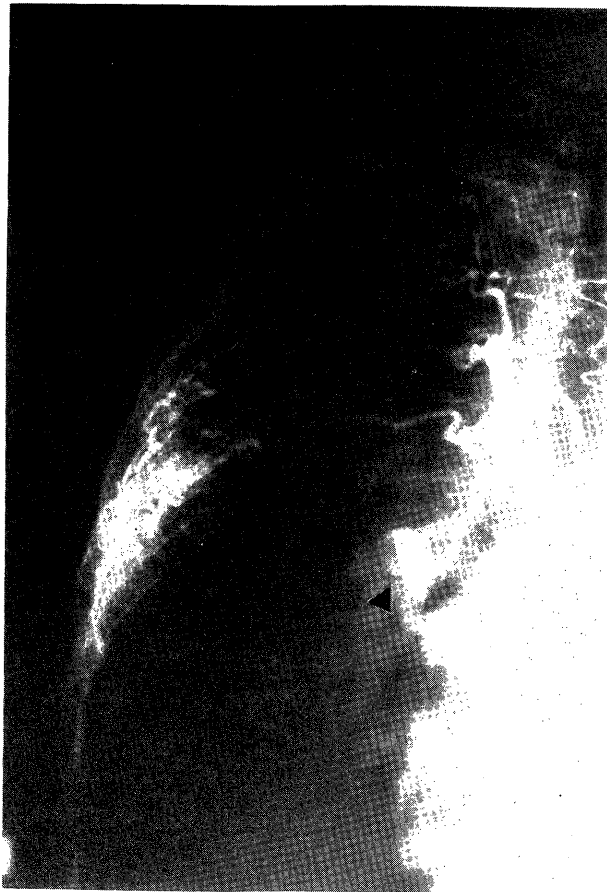

Fig. 3. Pre-embolization selective bronchial arteriogram.
Arrow points to the communication to pulmonary artery.

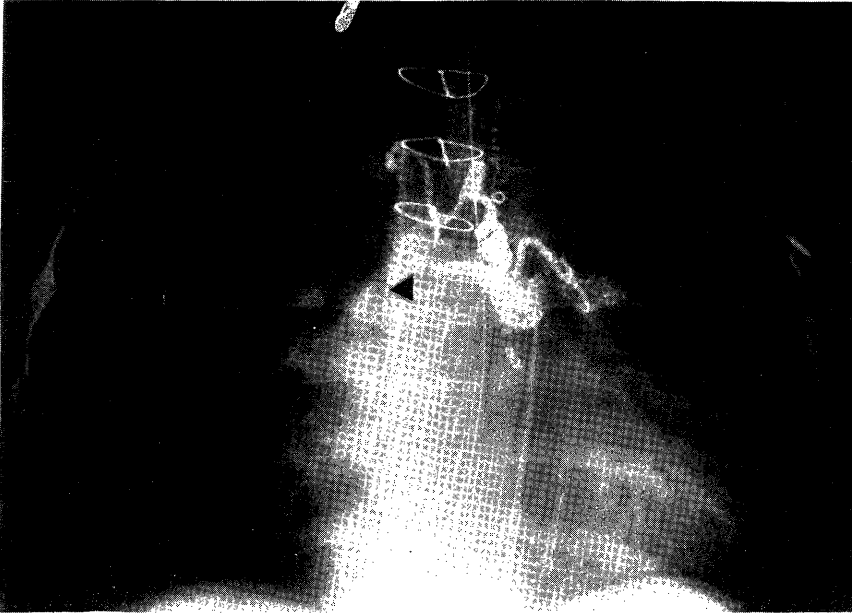


Fig. 4. Selective bronchial arteriogram after first transcatheter embolization. Arrow points to spring embolus.

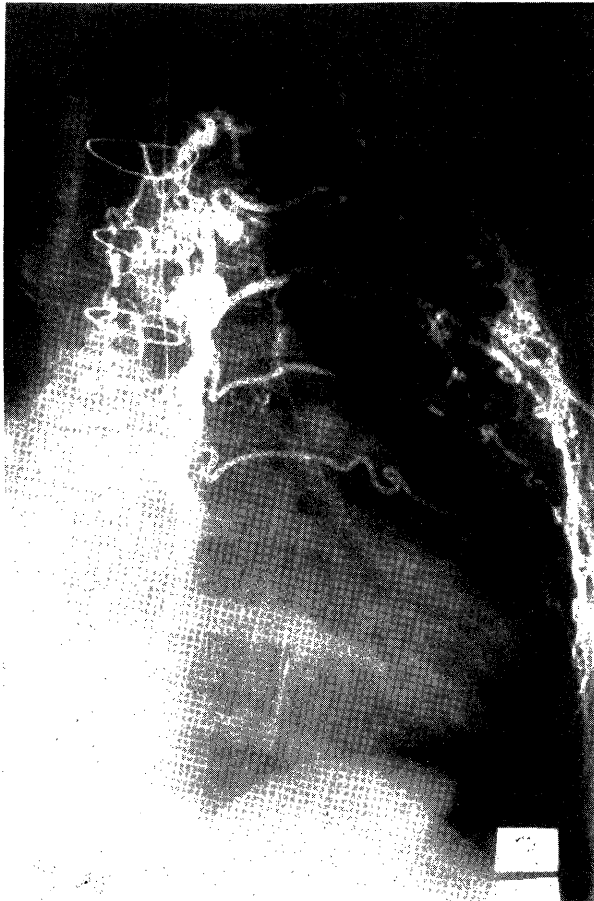


Fig. 5. Intercostal arteriogram arising from abnormal artery.

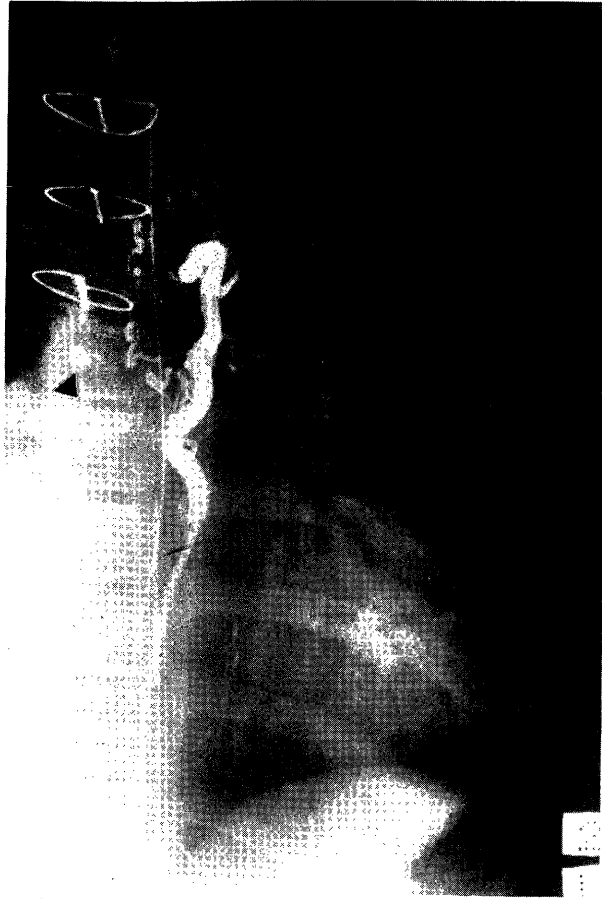


Fig. 6. Selective angiogram after second transcatheter embolization. Arrow points to spring embolus.

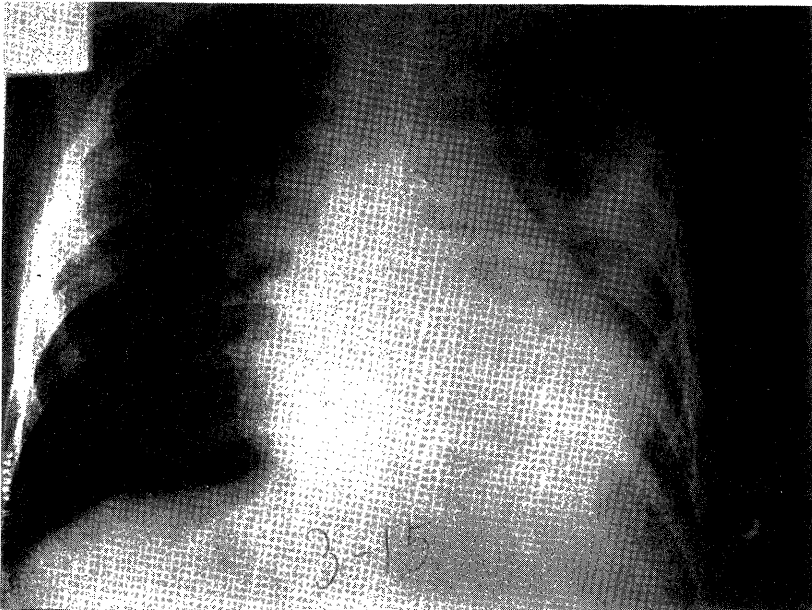


Fig. 7. Pre-embolization chest roentgenogram with severe congestive heart failure.

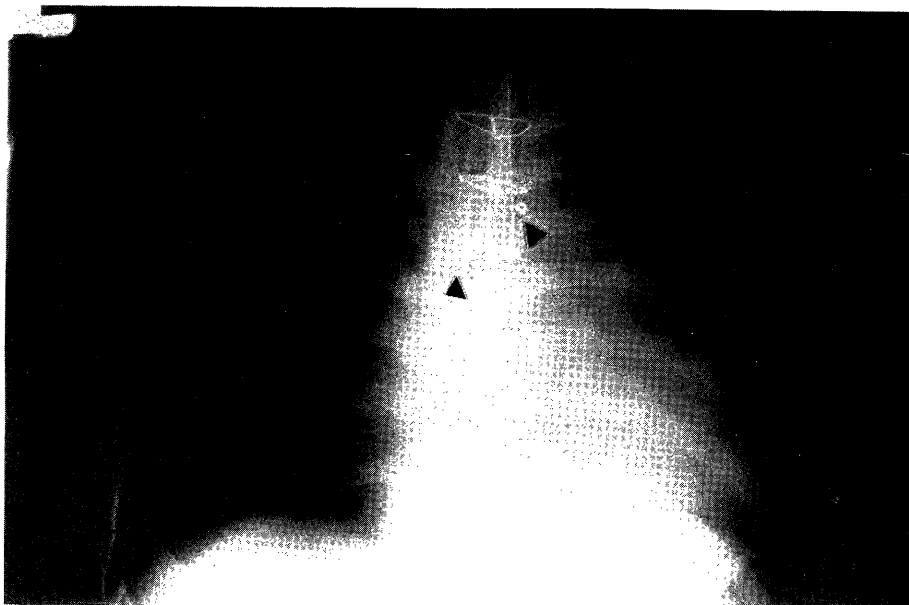


Fig. 8. Chest roentgenogram without congestive heart failure after two times embolizations. Arrow points to spring embolus.

Bronchial arteriogram of the pre-embolization is showed in Fig.3. After first embolization, injection of contrast demonstrates occlusion of the right bronchial artery by spring embolus (Fig.4). An abnormal artery branching out to the left intercostal arteries is revealed in Fig. 5. After second embolization performed for the abnormal artery, collateral flow is extremely decreased in the peripheral artery from the embolized place (Fig. 6). Improvement in the hemodynamics of the patient was evident. Four days after second embolization, bronchial tube could be extubated. Pre-embolization chest roentgenogram is showed with severe congestive heart failure (Fig. 7). Chest roentgenogram without congestive heart failure is revealed after two times embolizations (Fig. 8).

DISCUSSION

Usually, systemic-pulmonary collateral vessels have been developed in the patients of older TOF. It is difficult to leave from left heart failure due to volume overload post operatively. Careful preoperative angiographic assessment of size and location of collateral vessels is essential to determine which of these vessels might best be approached surgically and which might best be occluded by the catheter technique.

In our case, a left Blalock-Taussig anastomosis had been performed, and angiographically, diffuse transpleural communications were noted throughout the left hemithorax. Therefore, preliminary left thoracotomy was felt to be too hazardous.

ASANO *et al.*²⁾ reported two cases of division of collateral arteries by left thoracotomy before corrective operation. This procedure is superior for the patients who had not been

received, or had been received shunt operation in the opposite side of the thoracotomy which will be performed. But this procedure has demerit in operative risk, bleeding and troublesome in changes of patient's position³⁾ under hypoxia.

The transcatheter embolization just before total correction is a safe, reasonably simple and popularizing procedure⁴⁾. The reasons why transcatheter embolization was not made for our case before open heart surgery are 1) possibility of hypoxia due to embolization 2) impossibility of transcatheter embolization at the operating room, furthermore 3) unknown of left to right shunt flow before the operation.

KIRKLIN & KARP⁵⁾ reported that collateral blood flow was recognized to measure the difference of oxygen saturation in the pulmonary artery and RV or to know relationship RV outflow tract stenosis and left ventricular volume. Bronchial collateral blood flow is more large when pulmonary artery/aorta diameter ratio is less small⁶⁾. But practically, it is very difficult to estimate the volume of the left to right shunt and actually, the diameter of the collateral vessel or blood velocity is only method to surmise the volume of the shunt flow.

MAGOON *et al.*⁶⁾ reported successful division of the collateral bronchial artery by thoracotomy after correction. The successful use of this technique in our case demonstrates that it is a safe and reasonably simple procedure⁷⁾ when it is difficult to estimate the volume of left to right shunt, or it is impossible to wean from left heart failure after cardiac operation. If not be careful, the complication of this procedure, for example, embolization to renal, coeliac and superior mesenteric artery, coming off of the spring embolus will be occurred.

We must recognize whether the diameter of the systemic-pulmonary communication is large or not, since unexpected pulmonary arterial embolization will be occurred particularly in large type of the communication⁸⁾. If careful attention is payed, transcatheter embolization is a safe and reasonably simple procedure in the hands of a skilled angiographic technician.

REFERENCES

- 1) GIANTURCO, *et al.*: Mechanical devices for arterial occlusion. *Am. J. Roentgenol.* 124: 428, 1975.
- 2) ASANO, K. *et al.*: Treatment of bronchial collaterals in corrective surgery of the tetralogy of Fallot. *J. J. A. T. S.* 26: 1445, 1978. (in Japanese)
- 3) PACIFICO, A. D. *et al.*: Surgical treatment of common arterial trunk with pseudo-truncus arteriosus. *Circulation* 49 & 50, *Suppl.* II 20: 26, 1974.
- 4) YAMAMOTO, S. *et al.*: The occlusion technique of bronchial collateral arteries in total correction of Fallot: Especially about the application of transcatheter embolization. *J. J. A. T. S.* 27: 1702, 1979. (in Japanese)
- 5) KIRKLIN, J. W., KARP, R. B.: The tetralogy of Fallot from a surgical viewpoint. Philadelphia, London, Toronto, 1970, WB Saunders Co.
- 6) MAGOON, D. C. *et al.*: Surgical management of large bronchial collateral arteries

with pulmonary stenosis or atresia. *Circulation* 52: 109, 1975.

- 7) SZARNICKI, R. *et al.*: Wire coil embolization of systemic pulmonary artery collaterals following surgical correction of pulmonary atresia. *J. Thorac. Cardiovasc. Surg.* 81: 124, 1981.
- 8) JEFFERSON, K. *et al.*: Systemic arterial supply to the lungs in pulmonary atresia and its relation to pulmonary artery development. *Br. Heart. J.* 34: 418, 1972.