

Experimental Study on Healing Process in
Bronchial Anastomosis
—Especially Availability of Omental Wrapping
and Pericardial Covering—

Koji KIMINO

*The First Department of Surgery,
Nagasaki University School of Medicine,
Nagasaki, Japan*

Received for publication, September 1, 1984

Benefits from wrapping procedure for the bronchial anastomotic sites were evaluated on the basis of the findings in relation to restoration and recanalization of the bronchial arteries. Restoration of the bronchial artery in the bronchial anastomotic sites was experimentally tested in regard to wrapping with pedicled omentum (Group II) and pedicled pericardium (Group III) in comparison with non-wrapping (Group I) on mongrel dogs. The grades of recanalization of the bronchial artery, which had been interrupted by bronchial sleeve resection, were assessed by means of postmortem bronchial angiography and healing process in anastomotic sites were evaluated by bronchoscopic and histologic examinations during a period from the 3rd day to 7th month following sleeve anastomosis between the left main and the lower bronchus on dogs.

The results were as follows

- 1) Regeneration and recanalization of the bronchial artery are achieved on Day 7 after operation by using omentopexy procedure, whereas there are evidenced on Day 14 or later in either non-wrapping or pedicled pericardial covering.
- 2) Arterial blood supply to the bronchial wall distal to the anastomotic site is observed on Day 3 of the earliest time period following surgery by using omentopexy procedure, showing an arterial connection with the celiac artery, which becomes manifest within at least 3 or 4 days after performing bronchoplasty.
- 3) There is no difference in development of the bronchial arterial circulation in the bronchus at periphery between the procedures of non covering in bronchial anastomotic site and covering with the pedicled pericardium. The new growing arterial blood flow increased on Day 7 in the both procedures following bronchoplasty.
- 4) A new growing bronchial artery throughout the bronchial wall is completed on Day 14, demonstrating no differences in time periods between non-covering and wrapping groups.

- 5) On the basis of the findings of macroscopic and endoscopic examinations, marked mucosal changes in the bronchial anastomosis are almost observed on Day 7 in Group I and III, whereas approximately on Day 4 in Group II. These disappear almost on Day 14 among all three groups.
- 6) Based on histologic examination, most aggravating mucosal changes are revealed on Day 5 to Day 14 in Group I, III and on Day 3 to Day 4 in Group II. Rapid disappearance of these mucosal changes is observed on Day 7 in Group II.

INTRODUCTION

The technique of bronchoplasty has developed to preserve the healthy lung tissue for the hilar type of lung cancer. However, healing process in bronchial anastomosis is not clarified although bronchial anastomosis have led to interruptions of both the bronchial artery and the lymphatic channels. On the other hand, dehiscence of the bronchial anastomosis is a ominous complication. Then, surgeons tend to employ a wrapping procedure to facilitate the healing process of the bronchial anastomosis. However, it is dubious as to whether this procedure is beneficial in promoting bronchial healing or not.

A procedure of omentopexy has been used for acceleration of bronchial healing in lung allografts as reported by LIMA¹⁾ et al. and also in transplanted artificial trachea as cited by NELSON.²⁾ It, however, is not defined as to whether wrapping either with the pericardium or the pleura is available to make healing of the bronchial anastomosis easier or not.

This study was undertaken to clarify the effect of wrapping procedures on healing of the bronchial anastomosis.

MATERIAL AND METHOD

Sixty-two randomly selected mongrel dogs of both sexes weighting from 7 to 25kg were anesthetized with intravenously administrated pentobarbital sodium (Nembutal) 25mg per kg of body weight, tracheally intubated and maintained with air on positive pressure ventilation by Havard respirator (setting in 200 to 400ml of tidal volume, 20 per minute in respiratory rate)

These dogs were divided as follows:

Group I (control group including 22 dogs as shown in Fig. 1-a):

Left thoracotomy was performed at the 5th intercostal space and upper lobe sleeve lobectomy was made in addition to a procedure of hilar stripping. Bronchus was anastomosed between the left main bronchus and lower bronchus using 4-0 Vicryl with continuous suture.

Group II (omental wrapping group including 21 dogs as shown in Fig. 1-b):

The operative manner similar to Group I was performed and an additional procedure

of wrapping with omental pedicle graft was added. Therefore, laparotomy via upper mid-abdominal incision was performed and the omentum was isolated from the attachment on the spleen and most of the greater curvature of the stomach preserving the omental artery with two or three branches from the right gastroepiploic artery. Isolated omentum was drawn upwards through the retrosternal route.

Omentopexy around the bronchial anastomosis was made by fixations of 4 or 5 stiches using 4-0 Proline.

Group III (pedicled pericardial wrapping including 19 dogs as shown in Fig 1-c):

Wrapping with pedicled pericardium around bronchial anastomotic sites was added to an operative manner similar to Group I and pedicled pericardium was made by fixations of 4 or 5 stiches using 4-0 Proline.

In these dogs in Group I, II and III, antibiotics of cephalosporine and aminoglycoside were given for 3 days following operation.

Drainage tube in the thoracic cage was removed in 2 or 3 hours following surgery, confirming complete lung reexpansion.

Healing process of the bronchial anastomosis was observed in early postoperative period on Day 3 following surgery and in late of the 7th month by bronchoscopy, post-mortem bronchial angiography and histologic examination.

1) bronchoscopic examination

With intravenously given Nembutal (25mg/kg), bronchoscopic examination using OLYMPUS TYPE B-3 was done to check the degree of redness, edema, mucus obstruction in early postoperative period as well as in the degrees of scar, granulation and stenosis formation in late.

2) postmortem bronchial microangiography

With intravenously given Nembutal (25mg/kg) and tracheal intubation on positive pressure ventilation by Havard respirator, thoracotomy was made receiving a 5000U heparin bolously. After cannulations into the pulmonary artery using c-0 cut down tube in all groups, and the isolated descending aorta using No.8 Nelaton catheter in Group I and III, which was ligated at the two points directly distal to the attachment of the subclavian artery and cephalad to the diaphragma, or the celiac artery using c-0 cut down tube in Group II, about 500 or 1000ml saline was used for washout of their vascular trees through these cannulas.

Thereafter, contrast materials, 50 to 70ml of 30% Barium sulfate at 40°C and 50 to 70ml of mixture of 1% Gelatin-agar and Barium sulfate at 40°C, were infused by hand to the isolated descending aorta in Group I and III or the celiac artery in Group II, keeping part of the left atrial wall opened.

Following infusion of the contrast materials, left thoracic cages were cooled with ice slash in a 30 minute duration to make contrast material solid. Then, the lungs with trachea and the main bronchi were removed and prepared for postmortem roentgenogram.

3) postmortem roentgenogram

Softex (Type EMB) was used for evaluation of newly growing bronchial artery connections in the anastomotic site and distal anastomosed bronchus using Fuji Softex Film under a condition of 40KVp, 3mA, 60sec for the lung parenchyma and 40KVp, 3mA, 10sec for the trachea and bronchus as well as microsection in anastomotic sites.

a) bronchus-reconstructed lung

The degree of development of new bronchial artery in the bronchus-anastomosed

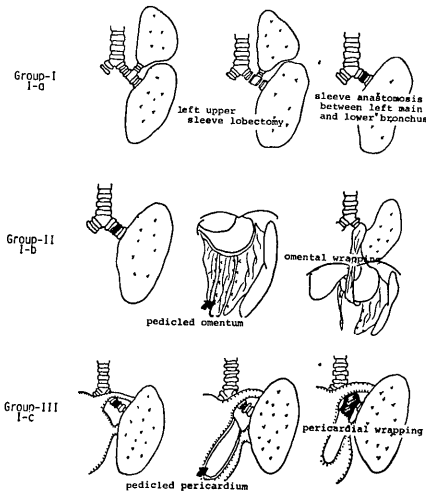


Fig. 1. The diagrams of the operative method

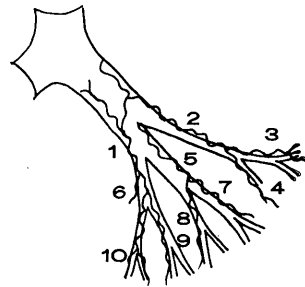


Fig. 2. The development of the bronchial artery in the bronchus-anastomosed lung is shown with classified 1 to 10 according to bronchial wall by bronchial angiography.

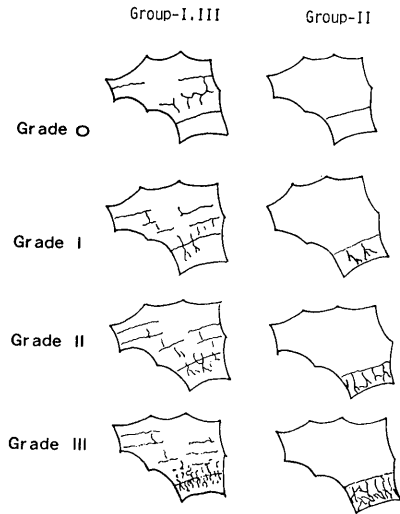


Fig. 3. The newly development of bronchial arteries around the anastomotic site is shown with grading classified by microangiographic finding

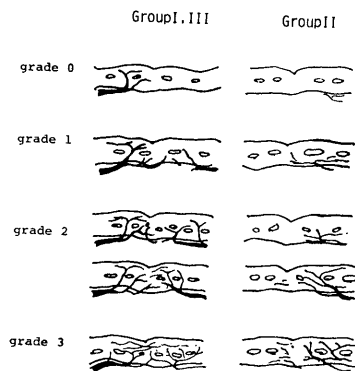


Fig. 4. The newly growing arteries arising from the adventitia on the slices are shown with grading classified by microangiographic finding.

lung was assessed on the bronchus-reconstructed lower lobe as shown in Fig. 2, showing the figures from 1 to 10 according to bronchial branches.

b) anastomosed-bronchus preparation

An anastomosed bronchus was longitudinally opened and it was fixed with 10% formalin for 7 days. This preparation was used for assessment of newly developed bronchial arteries around the anastomotic site.

These were graded as follows: Grade 0—no filling of bronchial artery extended beyond the anastomosis, Grade I—a few vessels on part of the bronchial wall but not throughout the wall, Grade II—filling of bronchial artery spreading throughout the bronchial wall at periphery, Grade III—more dense filling rather than Grade II as shown in Fig. 3.

c) slices of the anastomosed bronchus

Eight to twelve slices longitudinally cut at 2mm interval were prepared to make clear of newly growing arteries by roentgenogram arising from the adventitia around anastomosis performed.

The developments of the bronchial artery circulations were graded as follows: grade 0—no filling of the bronchial artery in the distal bronchus, grade 1—filling limits to the adventitial layer, grade 2—fillings spread both in the adventitia and submucosa, grade 3—filling is clearly visualized in all slices and throughout the bronchial wall as shown in Fig. 4.

d) macroscopic evaluation of newly developed submucosal vessels around anastomotic site.

Yellow and/or red colored silicon rubbers (Canton Bio Medical Co.) as the infused contrast material to the pulmonary artery, descending aorta and celiac artery were used for assessment of newly developmental vessel in the submucosal layer around bronchial anastomosis previously performed. Such becomes easy to assess the degree of newly growing vessels on gross appearance due to colored vessels and also microangiography using Softex was done.

4) Macroscopic observation of healing process in anastomotic site. Surgical specimen prior to formalin fixation was grossly observed with regard to the mucosal changes in redness, edema, ulceration and necrosis around the anastomotic site.

Macroscopic findings were graded as follows: M-0—no change of mucosal surface just above or distal to the bronchial anastomosis, M-1—slight degree of mucosal changes such as edema or redness, M-2—moderate degree of mucosal changes, M-3—severe degree of mucosal changes in erosion and ulceration, M-4—remarkable changes in bleeding, ischemia and degeneration.

5) Histologic evaluation of healing process

Multislices in the anastomotic site were prepared for histologic examination (Hematoxylin-Eosin).

Histologic findings were graded as follows: m-0—no inflammatory and ischemic finding, m-1—slight degree of inflammatory changes in round cell infiltration, erosion,

edema, m-2-moderate degree of inflammatory changes, m-3-severe degree of inflammatory changes combined with a finding of exposure of the cartilage, m-4-aggravating findings such as abscess formation, necrosis and degeneration of the cartilage.

RESULTS

During a period of observation, deaths were occurred in 2 out of 22 dogs in Group I, in 3 out of 21 dogs in Group II and none out of 19 dogs in Group III. Causes of death were anastomosis insufficiency in one on Day 4, emaciation in one on Day 14 in Group I, and anastomosis insufficiency in one on Day 2, tissue necrosis in anastomotic site resulting from omental necrosis in two on Day 4 and 5 in Group II respectively.

1) bronchoscopic examination

Therapeutic bronchoscopy was not infrequently done to evacuate the bronchial secretion in the postoperative period and also it was used for observation on healing of the bronchial anastomosis.

Marked mucosal changes including the finding of erosion and ulceration were almost revealed on Day 7 in Group I, III and approximately on Day 4 in Group II and disappearance of these changes was almost observed on Day 10 in Group I, III and nearly on Day 7 in Group II. There was no serious deterioration on bronchoscopy in late stage except for stenosis in one of Group II and in two of Group III respectively.

2) Postmortem bronchial angiography

a) bronchus reconstructed lung preparation

According to branches of the bronchus as shown in Fig. 2, the sites of the bronchial artery which is illustrated on angiogram were verified to assess the improving bronchial artery circulation. These results were summerized in Fig 5.

In Group I, the branches of the bronchus visualized the bronchial artery were nil to one on Day 5 and one to 10 with varying variety on Day 7 to Day

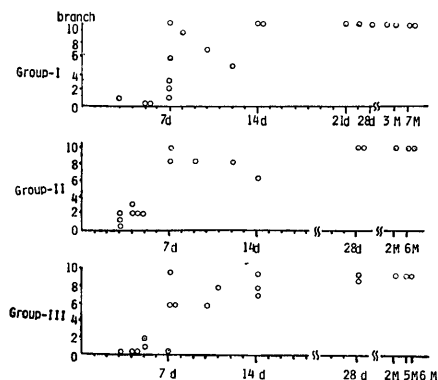


Fig. 5. The degree of the development of the bronchial arteries in the anastomosed lung.

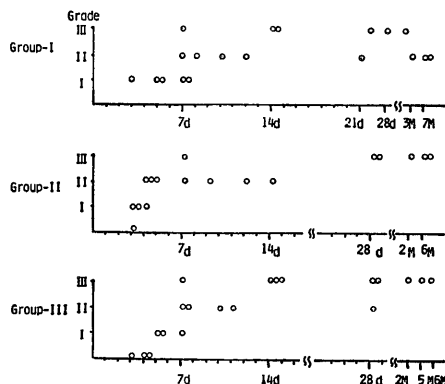


Fig. 6. The degree of the newly developmental bronchial arteries around the anastomotic site.

12 but the development of the bronchial artery was clearly seen in all ten bronchi on Day 14.

In Group II, these were 0 to two on Day 3, 2 to 3 on Day 4 and 8 or more on Day 7. Photo 1 showed well developed bronchial arteries from the celiac artery through omental pedicle graft on Day 7.

In Group III, nil on Day 4, 1 to 2 on Day 5, 6 to 10 on Day 7 in all but one respectively.

b) anastomosed-bronchus preparation

The development of the bronchial artery was assessed according to grading as shown in Fig. 3. These results were plotted in Fig. 6.

In Group I, Grade I was shown on Day 3 to Day 5 in all, Grade I or II on Day 7 to 12 except for Grade III in one and Grade II or III on Day 14 or later.

In Group II, Grade I was revealed on day 3 in two out of three, Grade II on Day 4 in three out of four, Grade II or III on Day 7 to 14, Grade III on Day 28 or later in all.

In Group III, Grade 0 was observed on Day 4 as shown in photo 2, Grade I on Day 5, Grade I to III on Day 7 with varying variety, Grade III on Day 14 or more in all as illustrated in photo 3.

c) slices of the anastomosed bronchus

Newly growing bronchial artery to the bronchus distal to the anastomosis was evaluated by grading as shown in Fig. 4. These results were shown in Fig. 7.



Photo 1. Bronchial arteriogram showed well developed bronchial arteries from the celiac artery through omental pedicle graft on Day 7 in Group-II.

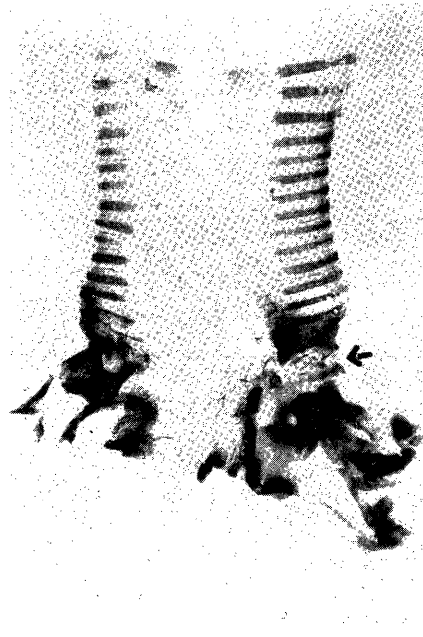


Photo 2. Microangiographic finding of anastomosed bronchus, showing no filling of bronchial artery extended beyond the anastomosis (arrow) on Day 4 in Group-III.

In Group I, grade 1 was on Day 3 to Day 5, grade 1 to 3 were on Day 7 to 12 and grade 3 on Day 14.

In Group II, grade 1 was shown on day 3 in two out of 3, grade 2 on Day 4 in 3 out of four and grade 3 on Day 7 or more in all, photo 4 showed

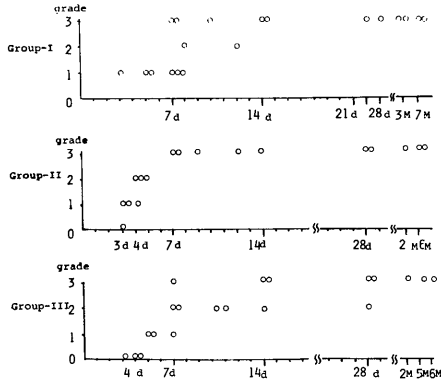


Fig. 7. The degree of the newly growing arteries of the slices of the anastomosed bronchus.

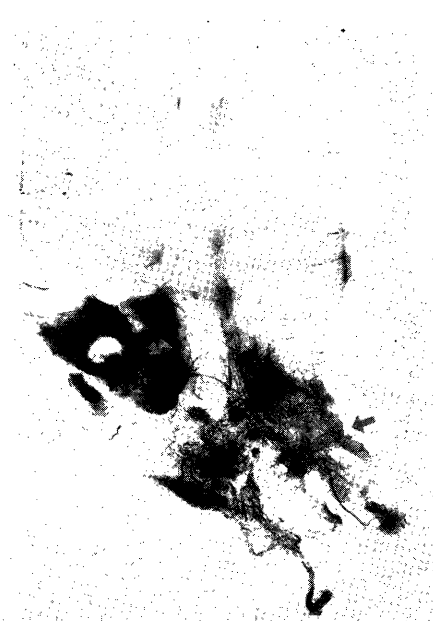

Photo 3. Microangiographic finding of anastomosed bronchus, showing dense filling of the bronchial arteries extended beyond the anastomosis (arrow) on Day 14 in Group-III.

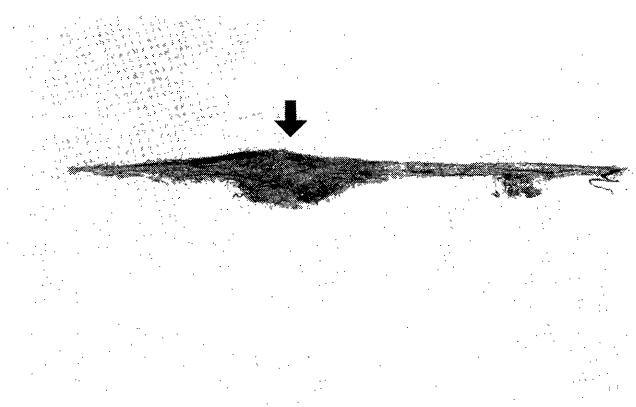


Photo 4. Bronchial angiogram on the slice around the anastomosis (arrow), showing well developed bronchial communication between distal and proximal bronchial arteries on Day 14 in Group-II.

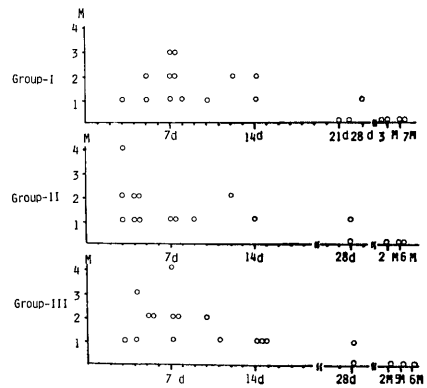


Fig. 8. The degree of the healing process by macroscopic findings.

well developed communication between proximal and distal bronchial arteries on Day 14.

In Group III, grade 0 on Day 4, grade 1 or 3 on Day 7, grade 2 or 3 on Day 12 or more in all.

- d) development of new submucosal vessels visualized by infusion of colored micro-fils.

Newly developmental bronchial arteries in the submucosal layer were clarified by means of infusion of the colored microfils.

In Group II, it appeared in the bronchus at periphery on Day 4, whereas in Group I and III on Day 5 to 7. Especially communication of the proximal bronchial artery with the celiac artery crossing the bronchial anastomosis was characteristic in Group II and has become manifest on Day 14.

- 4) Macroscopic observation of healing process in anastomotic site

The surface of the mucosa just above or distal to the anastomosis was carefully observed according to grading as shown in Fig. 8.

In Group I, M-1 or M-2 were seen on Day 3 to Day 5, M-2 or M-3 on Day 7 except for one (M-1), M-2 was still observed on Day 14.

In Group II, M-1 or M-2 were visualized on Day 3 or Day 4 except for one showing M-4 with stenosis of the pulmonary artery but M-1 on Day 7 as shown in photo 5.

In Group III, M-1 was on Day 3, M-1 or M-3 on Day 4, M-2 on Day 5, M-4 was observed on Day 7 due to pneumonia. M-1, however, was shown on Day 11 or later.

- 5) Histologic evaluation of healing process

Histologic evaluation of healing of the bronchial anastomosis was attempted ac-

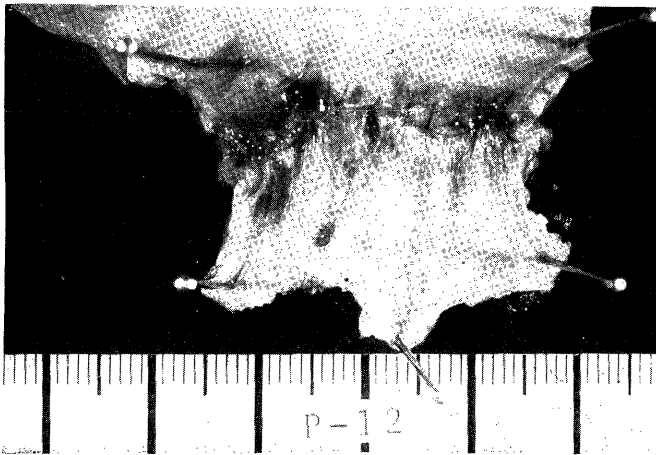

Photo 5. Macroscopic finding of healing in bronchial anastomosis, showing M-1 grading on Day 7 in Group-II.

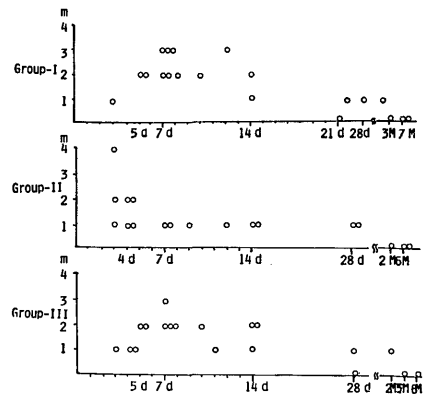


Fig. 9. The degree of the healing process by microscopic findings.

ording to grading as shown in Fig. 9.

In Group I, the findings of m-2 or more were observed on Day 5 to Day 12 in 12 out of the 13, m-0 or m-1 on Day 21 to 2 month and m-0 was shown in 3 month or more in all.

In Group II, m-1 or m-2 were revealed on Day 3 or Day 4, m-1 on Day 7 to Day 28 in all, m-0 was present in 2 month or more in all. In Group III, m-2 or more were demonstrated on Day 5 to Day 14 in 9 out of the 11, m-1 or m-0 on Day 28 to 2 month and m-0 was evaluated in a 5 month period.

DISCUSSION

An operative procedure of bronchoplasty has become available for clinical application for the treatment of lung cancer to preserve healthy lung tissues as reported by PAULSON in 1955⁸⁾ and by JOHNSTON in 1959⁴⁾, since used for repair of traumatic rupture treated by SANGER in 1945⁵⁾ and by GRIFFITH in 1949⁶⁾. In order to prevent bronchial complication, however, further work is needed to devise methods to assure dependable bronchial healing. Such includes acceleration of restoration of bronchial arteries in the sites of bronchial anastomosis, control of accidental infection and establishment of creditable technique for anastomosis.

Among them, restoration of bronchial arteries in the anastomotic sites is of most importance in relation to promoting bronchial healing process.

Wrapping procedures with omentum and pericardium were evaluated in this series as to whether these procedures would be effective in restoration of bronchial artery or not.

Omental pedicle graft has clinically been used for reconstruction of the urinary tract by traumatic injury⁷⁾, treatment of lymphedema⁸⁾, and reconstruction of the thoracic wall by postirradiation necrosis for breast cancer⁹⁾ as well as experimentally been used for revascularization for myocardial infarct¹⁰⁾, repair for defect of the esophageal wall¹¹⁾. These results are favorable. Recently LIMA¹⁾ and MORGAN¹²⁾¹³⁾ reported that wrapping with omental pedicle flap for the lung autotransplantation had led to early and solid healing in the bronchial anastomosis. NELSON²⁾ also noted that omentopexy for microporous tracheal prosthesis is effective in improving neovascularity and tissue affinity.

As a wrapping material, the use of the pleura and pericardium were most common in chest surgery in preventing the bronchial complication which contribute to death. A critical factor in preventing the bronchial anastomotic complication may be attributable to poor restoration of the bronchial artery. Restoration of the bronchial artery has experimentally been assessed by two methods, bronchial arteriography according to SELGINGER'S method and/ or postmortem bronchial arteriography injected with microfil.

In this study, the latter method is used for evaluation of restoration of the bronchial artery continuity. There are many available materials for microfils such as Vinyl acetate, Carbonyl nickel particles, Barium sulfate gelatin mixture, Microfil-Latex rubber, Silicon rubber. In this series, restoration of the bronchial artery beyond the anastomosis was tested

by means of postmortem angiography using microfilms of a mixture of gelatin-agar Barium sulfate applied by KAWAHARA¹⁷⁾ as well as colored Silicon rubber evidenced by LIMA¹⁾ and MORGAN¹²⁾¹³⁾.

MILLS¹⁸⁾ confirmed experimentally that a 80% of left bronchial artery on dog is emerging from the right intercostal arteries and ELLIS¹⁹⁾ also identified that bronchial arterial blood drains to the bronchial and pulmonary veins. The bronchial venous blood also returns to the azygos, hemiazygos and intercostal veins, and also the pulmonary arterial blood circulates the bronchial walls at periphery. Since then, the communication between bronchial and pulmonary arteries was described as precapillary anastomosis as reported by FISHER²⁰⁾ and as pulmonary-bronchial collateral circulation at lung autotransplantation as stated by PEARSON²¹⁾.

Restoration of the bronchial artery continuity are shown on Day 14 following bronchoplasty as evidenced by KAWAHARA¹⁷⁾, on Day 16 by FISHER²⁰⁾ and in the first 4 week by PEARSON²¹⁾. In lung allograft, restoration of the bronchial artery is clearly demonstrated on Day 15 by RAVINOVICH²²⁾, in the first 4 week by PEARSON²¹⁾. In contrast, LIMA¹⁾ reported that it develops from the celiac artery on Day 4 when performing omentopexy.

From the results of this study, there is no difference in restoration of the bronchial artery between non-wrapping (Group I) and pericardial wrapping (Group II) procedures. Restoration of the bronchial artery crossing the anastomosis is observed during a period from Day 7 to Day 14 in Group I and III following bronchoplasty. When adding the procedure of wrapping with omental pedicle flap, it begins from Day 3 or Day 4 and mostly completes on Day 7 or more.

SHIEGELMAN²³⁾ analyzed improvement of bronchial artery circulation beyond the bronchial anastomosis in 10 lung allografts of dogs by grading (0 to 4) on postmortem roentgenogram using Latex rubber. He noted that the bronchial artery grows in 12 days following lung transplantation and regeneration extends into the periphery of the lung with the passage of 2 or 3 weeks. KAWAHARA¹⁷⁾ also confirmed that filling of the bronchial arterial network throughout the distal bronchial wall is observed in the first 7 day or more following bronchoplasty on observation of multislice angiogram.

The author noted that restoration of the bronchial artery around the bronchial anastomosis is observed on Day 7 after bronchoplasty in Group I and III, whereas restoration begins on Day 3 to 4 from the celiac artery and dense filling crossing the anastomosis is observed from Day 4 to Day 7 in Group II. However, there is no evidence in appearance of multiple branches of the bronchial circulation in the period of 14 days or more following the surgical procedure among three groups.

On the other hand, PEARSON²¹⁾ observed healing process in the bronchial anastomosis by means of serial bronchoscopic examination during a period from the first day to the 8th week following the surgical procedure of bronchoplasty in combination with hilar stripping. He noted that edematous and cyanotic mucosal alterations remain well recognized during a period of 6 weeks following surgery. SATO¹⁴⁾ also cited that mucosal

changes following sleeve bronchoplasty performed are more prominent rather than those following wedge bronchoplasty. Meanwhile, on the basis of findings of macroscopic observations on mucosal surfaces around the subsequent bronchial anastomosis to bronchoplasty with making concomitant pulmonary stenosis, KAWAHARA¹⁷⁾ identified that the mucosa surface of the bronchus distal to the anastomosis shows either erosion or ulceration on Day 7 to Day 12 following surgery, and these return to normal appearance on Day 19 or later.

In this series, such mucosal change is almost revealed on Day 7 in Group I and III, whereas nearly on Day 4 in Group II. However, these changes almost disappear on Day 14 and solid healing is shown on Day 28 among all three groups. According to longterm observation on endoscopy, there is no significant difference in the stenosis and granulation formation among three groups.

Lastly, based on histologic examination, most aggravating mucosal changes are demonstrated on Day 5 to Day 14 in Group I and III and on Day 3 to Day 4 in Group II. Rapid disappearance of these mucosal changes is observed on Day 7 in Group II, showing completion of mucosal healing on Day 7.

ACKNOWLEDGMENT

The author wishes to express his sincere gratitude to Prof. Masao TOMITA, The First Department of Surgery, Nagasaki University School of Medicine, for his kind guidance in the study and review of paper. Thanks are also due to Dr. H. AYABE, Dr. K. KAWAHARA, Dr. H. KUSANO and to all the staff members of The First Department of Surgery, Nagasaki University School of Medicine.

REFERENCES

- 1) LIMA, O., GOLDBERG, M., PETERS, W. J., AYABE, H., TOWNSEND, E., COOPER, J. D.: Bronchial Omentopexy in canine lung Transplantation. *J. Thorac. Cardiovasc. Surg.* 83: 418-421, 1982.
- 2) NELSON, R. J., GOLDBERG, L., WHITE, R. A., SHORS, E., HIROSE, F. M.: Neovascularity of a Tracheal Prosthesis/Tissue Complex. *J. Thorac. Cardiovasc. Surg.* 86: 800-803, 1983.
- 3) PAULSON, D. L., SHAW, R. R.: Bronchial Anastomosis and Bronchoplastic Procedures in the Interest of Preservation of Lung tissue. *J. Thoracic. Surg.*, 29: 238-259, 1955.
- 4) JOHNSTON, J. B., JONES, P. H.: The Treatment of Bronchial Carcinoma by Lobectomy and Sleeve resection of the Main Bronchus. *Thorax*, 14: 48-54, 1959.
- 5) SANGER, P. W.: Evacuation Hospital Experiences with War Wounds and Injuries of the Chest. *Ann. Surg.*, 122: 147-162, 1945.
- 6) GRIFFITH, J. L.: Fracture of the Bronchus. *Thorax*, 4: 105-109, 1949.
- 7) TURNER-WARWICK, R. T., WYNNE, E. J. C. HANDLEY-ASHKEN, M. : The Use of the Omental Pedicle Graft in the Repair and Reconstruction of the Urinary Tract. *Br. J. Surg.*, 54: 849-853, 1967.
- 8) GOLDSMITH, H. S., DE LOS SANTOS, R., BEATTIE, E. J. Jr.: Omental

- Transposition in the Control of Chronic Lymphedema. *JAMA* 203: 1119-1121, 1968.
- 9) DUPONT, C., MENARD, Y.: Transposition of the Greater Omentum for Reconstruction of the Chest Wall. *Plast. Reconstr. Surg.* 49: 263-267, 1972.
 - 10) PIFARRE, R., HUFNAGEL, C. A.: Epicardiectomy and Omental Graft in Acute Myocardial Infarction. *Am. J. Surg.* 115: 589-593, 1968.
 - 11) GOLDSMITH, H. S., KIELY, A. A., RANDAL, H. T.: Protection of Intra Thoracic Esophageal Anastomoses by Omentum. *Surgery* 63: 464-466, 1968.
 - 12) MORGAN, E., LIMA, O., GOLDBERG, M., FERDMAN, A., LUK, S. K., COOPER, J. D.: Successful Revascularization of Totally Ischemic Bronchial Autografts with Omental Pedicle Flaps in dogs. *J. Thorac. Cardiovasc. Surg.* 84: 204-210, 1982.
 - 13) MORGAN, E., LIMA, O., GOLDBERG, M., AYABE H., FERDMAN, A., COOPER, J. D.: Improved Bronchial Healing in Canine Left Lung Reimplantation Using Omental Pedicle Wrap. *J. Thorac. Cardiovasc. Surg.* 85: 134-139, 1983.
 - 14) Yasukuni TSUJI, Masao TOMITA: Experimental and Clinical Studies on the Plastic Surgery of Tracheobronchial Tree. *The Journal of the Japanese Association for Thoracic Surgery.* 21: 1-12, 1973.
 - 15) M. TOMITA, K. SHIBATA, Y. KOGA, T. ONIZUKA, H. AYABE, K. TAKETOMI, Y. TSUJI: Cardiac Herniation after Tracheo-Bronchial Reconstruction. *The Japanese Journal of Thoracic Surgery.* 30: 154-157, 1972.
 - 16) FABER, L. P., JENSIK, R. J., KITTLE, C. F.: Results of Sleeve Lobectomy for Bronchogenic Carcinoma in 101 Patients. *Ann. Thorac. Surg.* 37: 279-285, 1984.
 - 17) Katsunobu KAWAHARA: An Experimental Study on Bronchial Re-circulation following Bronchial Reconstruction—Especially the Correlation of Pulmonary Artery Stenosis with Bronchial Arterial Regeneration. *Nagasaki Igakkai Zashi* 55: 199-229, 1980.
 - 18) MILLS, N. L., BOYD, A. D., CHERANPONG, C., SPENCER, F. C.: The Significance of Bronchial Circulation in lung transplantation. *J. Thorac. Cardiovasc. Surg.* 60: 866-878, 1970.
 - 19) ELIS, F. H., GRINDLAY, J. H., EDWARDS, J. E.: The Bronchial Arteries. *Surgery* 30: 810-826, 1951.
 - 20) FISHER, A. B., KOLLMEIER, H., BRODY, J. S., HYDE, R. W., HANSELL, J., FRIEDMAN, J. N., WALDHAUSEN, J. A.: Restoration of Systemic Blood Flow to the Lung after Division of Bronchial Arteries. *J. Appl. Physiol.* 29: 839-846, 1970.
 - 21) PEARSON, F. G., GOLDBERG, M., STONE, R. M., COLAPINTO, R. F.: Bronchial Arterial Circulation Restored after Reimplantation of Canine Lung. *Can. J. Surg.* 13: 243-250, 1970.
 - 22) RABINOVICH, J. J.: Re-establishment of Bronchial Arteries after Experimental Lung Lobe Autotransplantation. *J. Thorac. Cardiovasc. Surg.* 64: 119-126, 1972.
 - 23) SIEGELMAN, S. S., HAGSTROM, J. W. C., KOERNER, S. K., VEITH, F. J.: Restoration of Bronchial Artery Circulation after Canine Lung Allotransplantation. *J. Thorac. Cardiovasc. Surg.* 73: 792-795, 1977.
 - 24) Hideo SATO: Study on the Pathophysiological Changes after Bronchoplastic Operation—with special reference to its effect on morphology as well as function of the reconstructed lung—. *Journal of Juzen Medical Society* 86: 599-615, 1977.