

Changes in Esophageal Blood Flow by Esophageal Transection with Devascularization

Masao TOMITA, Hiroyoshi AYABE, Toshio MIURA
Katsunobu KAWAHARA, Toshiyasu KUGIMIYA

*First Department of Surgery
Nagasaki University School of Medicine*

Received for publication, May 20, 1983

Changes in the blood flow in the wall of the esophagus were experimentally measured with the use of the hydrogen clearance method to evaluate the influence of operative procedure by transectional esophago-esophagostomy with paraesophageal and perigastric devascularization in the treatment of esophageal varices.

As a result of this study, an approximately 30% reduction in blood flow of the adventitia was confirmed according to the procedure of paraesophageal devascularization. When performing a further procedure of esophageal transection, total blood flow was reduced to 50%.

It is logical to conclude that the marked decrease in blood flow in the wall of the esophagus offers a great opportunity for the development of postoperative anastomosis insufficiency.

It is of interest to note that the incidence of postoperative complications in the performance of this operation for esophageal varices has become significant on the basis of blood flow changes in the wall of the esophagus.

INTRODUCTION

Surgical treatment for esophageal varices has been indicated for the catastrophic bleeding from ruptured varices.

However, the outcome of an urgent operation for the treatment of unexpected occurrence of bleeding is not so satisfactory that its treatment may be mainly for prophylactic surgery. The majority of patients with esophageal varices manifest some degree of hypoproteinemia secondary to hepatic dysfunction.

The methods of surgical treatment for esophageal varices are mainly divided into two categories, a) shunt operation¹⁾²⁾ for reducing the level of portal hypertension and b) direct transection³⁾⁴⁾⁵⁾ at the sites of the esophagus or the stomach with devascularization.

富田 正雄, 綾部 公懿, 三浦 敏夫, 川原 克信, 釘宮 敏定

These surgical treatments sometimes result in unexpected complications such as postoperative infection and anastomosis insufficiency, primarily due to a critical condition caused by liver dysfunction. We feel confident that surgical treatments help to reduce recurrent episodes of bleeding from ruptured varices⁶⁾ as well as save lives.

It would seem wise to recommend that complete devascularizations around the lower esophagus and the upper stomach are surgically needed.

However, it is more likely that complete devascularization of operative procedure may offer a marked reduction of blood flow in the esophageal wall. Consequently, it may cause anastomosis insufficiency. The aim of this study, therefore, is to assess the degree of esophageal blood flow reduction in association with experimentally operative procedure.

METHOD

In order to measure the changes in the blood flow of the esophageal wall, the hydrogen wash-out technique was employed with use of wire electrodes placed simultaneously on the adventitial and submucosal layers. The amount of blood flow was measured by the hydrogen clearance method in accordance with FICK's principle. The concentration of hydrogen as an indicator in the tissue is calculated by the following equation: $F = \frac{69.3}{T^{\frac{1}{2}}}$, where F: blood flow (ml/min/100g), T: time in minute from initial hydrogen

concentration to be reduced by half in any periods of hydrogen wash-out time.

Twenty-four mongrel dogs were used in this study were anesthetized intravenously with 25mg/Kg of pentobarbital sodium. With respiratory support provided by a Harvard respirator through an endotracheal tube a right thoracotomy was performed in the 5th intercostal space. The lower two-thirds of the esophagus was exposed with a gentle maneuver to avoid injury to some paraesophageal vessels and also a laparotomy was performed to permit complete devascularization in the upper portion of the stomach. These procedures were established for the maintenance of normal levels of systemic blood pressure. Dogs with a drop of systemic pressure were excluded from this study to obtain uniformity with respect to blood supply. The measurement of blood flow was made experimentally according to surgical steps, which consisted of esophageal transection with paraesophageal devascularization, perigastric devascularization and in combination. The values of esophageal blood flows were shown in adventitial and submucosal layers, respectively with the aid of two wire electrodes anchored in both layers.

Furthermore, the tissue PO₂ in the esophagus was measured by using a PO₂ meter (POG-300A made by Unic Medical Co.) to evaluate the changes in blood flows according to steps in the operative procedures.

RESULTS

After completion of the operative procedure of thoracotomy, the blood flows were compared with those in adventitial and submucosal layers as the control. Blood flow levels in the adventitia of the esophagus ranged from 28 to 40ml/min/100g with an average of 34ml/min/100g, whereas those in the submucosa varied from 22 to 37ml/min/100g with an average of 28ml/min/100g. The esophageal blood flow in the adventitia was dominant rather than in the submucosa in normal situation as indicated in Fig. 1.

By the operative procedure of paraesophageal devascularization, the blood flows in the adventitia were reduced by a mean of 29ml/min/100g, ranging from 22 to 35 ml/min/100g, although those in the submucosa were almost in the same order with an average of 25ml/min/100g, ranging from 19 to 32ml/min/100g.

By the preceding operative management of devascularization in the upper portion of the stomach, blood flows in the adventitia were 32ml/min/100g of a mean value, ranging from 21 to 38ml/min/100g, although those in the submucosa were 26ml/min/100g, ranging from 18 to 34ml/min/100g. A lesser decrease of blood flow in the submucosa was observed despite the slight decrease in the adventitia when compared to those of paraesophageal devascularization as shown in Fig. 2.

By both paraesophageal and perigastric devascularizations of operative procedures, the mean value of blood flows in the adventitia was 21ml/min/100g, ranging from 13 to 28ml/min/100g, whereas that in the submucosa was 22ml/min/100g, ranging from 15 to 26ml/min/100g.

It showed that the decrease of blood flow in the adventitia was more significant than that in the submucosa by devascularization of operative procedures.

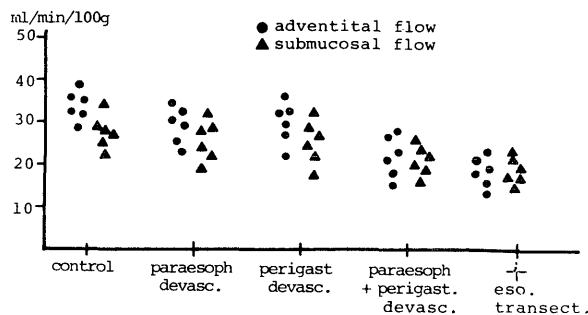


Fig. 1 Changes in tissue blood flow level in the esophageal wall which is divided into the adventitial and submucosal layers according to operative steps of transectional esophagostomy with devascularization.

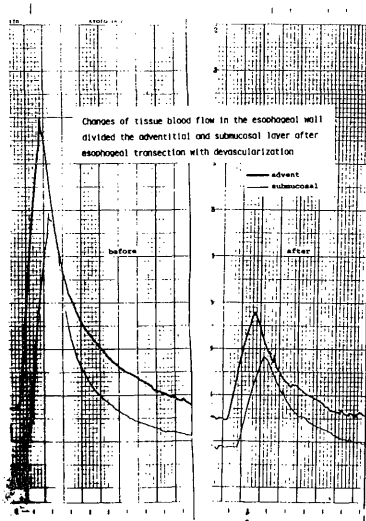


Fig. 2 An example delineating the graphic changes in tissue blood flow in the adventitial (heavy line) and submucosal layer (thin line) of the esophagus with the use of hydrogen clearance method when employed transectional esophagostomy with devascularization.

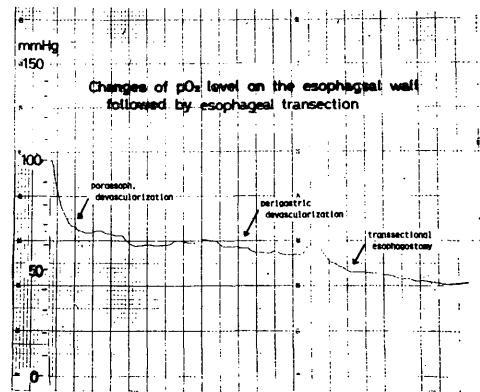


Fig. 3 An example of changes in tissue PO_2 level in the wall of the esophagus according to individual operative step of paraesophageal devascularization, perigastric devascularization and transectional esophagostomy.

When performing the esophageal transection of operative management, the mean value of blood flow in the adventitia was 17ml/min/100g, ranging from 12 to 24ml/min/100g which was reduced by a mean of half the normal, whereas the mean value in the submucosa was 19ml/min/100g, ranging from 15 to 24ml/min/100g in value range, which was equivalent to one-third the blood flow prior to surgery. It means that a decrease of adventitial blood flow is precipitated by the operative procedure of esophageal transection with devascularization. The PO_2 values in the esophageal wall were almost the same propensity as those measured by the hydrogen wash-out method. Fig. 3 represents the patterns of the tissue PO_2 changes in esophageal walls according to the entire operative steps performed.

DISCUSSION

The surgical treatment of esophageal varices was mainly composed of either shunt operation or paraesophageal devascularization with esophageal transection. Surgery was usually indicated by endoscopic finding corresponding to possible occurrence of catastrophic rupture of varices in near future. However, it was difficult to obtain surgically satisfactory results because of underlying liver diseases.

To improve the outcome of surgery, postoperative complications should be eliminated or excluded. One of the most serious complications was anastomosis insufficiency

after performing an operation of esophageal transection. A complete devascularization affords a better likelihood of complete relief from an recurrent episode of bleeding. On the contrary, there is no doubt that a reduced blood flow on the wall of the esophagus may entail and contribute to anastomosis insufficiency. In performing esophageal transection with devascularization for the treatment of esophageal varices, a growing concern in reducing blood flow in the wall of the esophagus by this method has focused attention on the prevention of postoperative complications.

Little has been said on subject of changes of blood flow in the wall of the esophagus.

This study was undertaken to assess changes in blood flow in the wall of the esophagus according to the operative procedures of devascularization and esophageal transection. When performing devascularization around the thoracic esophagus, blood flow is lowered to approximately 30% of normal. The addition of perigastric devascularization of the operative procedures still remains almost unchanged.

However, our study confirms that the esophageal transection enables blood flow on the wall of the esophagus to be reduced by 50%. Our results are very suggestive of a possible hazard of the healing process at the site operated upon.

There is no debate that a decrease of blood flow makes operated area vulnerable to dehiscence. It is not clear as to how much decrease in blood flow causes a delay impairment of wound healing. A 50% decrease of blood flow estimated in this study may delay satisfactory wound healing regardless of the complete elimination of esophageal varices.

Esophageal transection with devascularization as the operative treatment for esophageal varices offers some advantages over prevention of catastrophic bleeding of varices. Esophageal transection with devascularization performed successfully leads to further diminution of blood flow in the wall of the esophagus, especially in the adventitia in which many of the feeding vessels are distributed. It is usually considered advisable to necessitate at least one-half of the normal level in blood flow to give better wound healing. After performing this procedure, the blood flow is apparently reduced. It is reasoned, therefore, that staged operation is sometimes required.⁴⁾

The result of our experimental study is not necessarily consistent with a clinical one. In clinical cases, the numerous collateral circulation associated with portal hypertension is thought to exert in a different fashion.

Although there is some controversy, it seems worthwhile to document that esophageal transection with devascularization allows a 50% reduction in the blood flow of the wall of the esophagus.

Data in our study enables us to conclude that surgical management of devascularization for the treatment of esophageal varices is detrimental to subsequent wound healing in the transected esophages.

Care should be taken to avoid anastomosis insufficiency by using meticulous technique or dividing operative procedures into a two-stage operation.

REFERENCES

- 1) BLAKEMORE, A. H.: Portacaval anastomosis. *Surg. Gynecol. Obstet.*, 87: 277, 1948
- 2) CHILD, C. G. III: Present status of portal decompression for portal hypertension. *Am. J. Gastroent.*, 25: 148, 1956
- 3) WALTERS, W., *et al.*: Ligation of coronary veins for bleeding esophageal varices. *Proc. Staff. Mayo Clin.*, 4: 146, 1927
- 4) HASSAB, M. A.: Gastroesophageal decongestion and splenectomy in the treatment of esophageal varices in hilarzial cirrhosis: Futher studies with a report of 355 operations. *Surgery*, 61: 169, 1967
- 5) SUGIURA, M., FUTAGAWA, S.: Further evaluation of the Sugiura procedure in the treatment of esophageal varices. *Arch. Surg.*, 112: 1317, 1977
- 6) TANNER, N. C.: Direct surgical operations for portal hypertension. *The Liver* p 393, Colston Papers No 19, Butturworths, London, 1967