

Congenital Cystic Disease of the lung : An Autopsy Case

KIOKO KAWAI, TAKESHI MATSUO and TOSHIAKI IKEDA

*1st Dept. of Pathology, Nagasaki University School of Medicine
Nagasaki, Japan*

Received for publication. August 10, 1969

Many varieties of cysts occur in the lung : it includes not only true cysts but all lesions which mimic them. Recently congenital cystic disease of the lung has become widely observed and reported in literature.

This is an autopsy case of congenital cystic disease of the lung of a new born.

CASE REPORT

The infant was an 18 day-old female full term new born, whose birth weight was 3,740 gm. She was the second child. The neonatal period and early development was normal. At the age of 12 days, however, she was noticed to have cyanosis and dyspnea and was

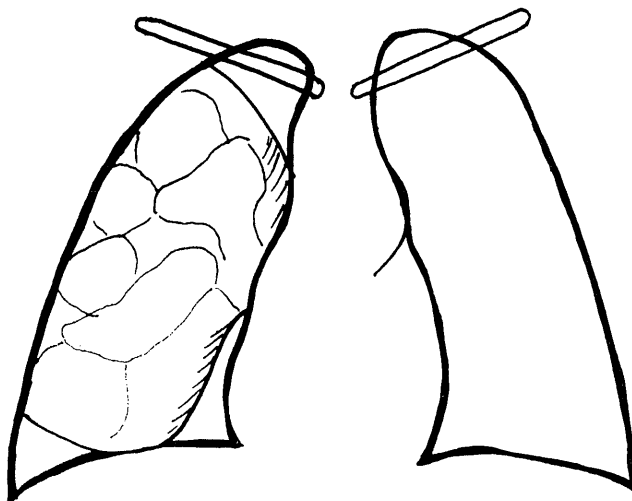


Fig. 1. Drawing of chest x-ray showing large multiple bullous appearance

admitted to the hospital. On the admission, she was cyanosed and dyspneic. There were no breath sounds in the right lung and a few rales were heard in the left lung. She was placed in an incubator and although the cyanosis improved, she developed tachypnea. At the age of 17 days, cyanosis increased, dyspnea also became severe and she expired the following day.

Hematology was negative except for a leucocytosis (15,000-20,000). Chest x-ray revealed bullous lesions in the right lung (Fig. 1) and she was diagnosed as pulmonary emphysema.

AUTOPSY

The postmortem examination revealed a well developed new born female infant. The body measured 50 cm. long and weighed 3,000 gm. The left lung weighed 27.5 gm and the right 31.0 gm. The right middle lobe contained a large lobulated cyst measuring 6×5 cm and the right upper and lower lobes were atelectatic. On sectioning, the right upper and lower lobes were rather solid and congested. The right middle lobe was honeycombed with many well-defined large and small cysts. (Fig. 2) The lining of the cysts was dark brown to gray brown, thin and glistening. Grossly there were no contents in the cysts. The area near the hilus in the right middle lobe showed compressed lung tissue. The cysts had no communication with the bronchial tree. There were no abnormalities of the bronchi or vessels

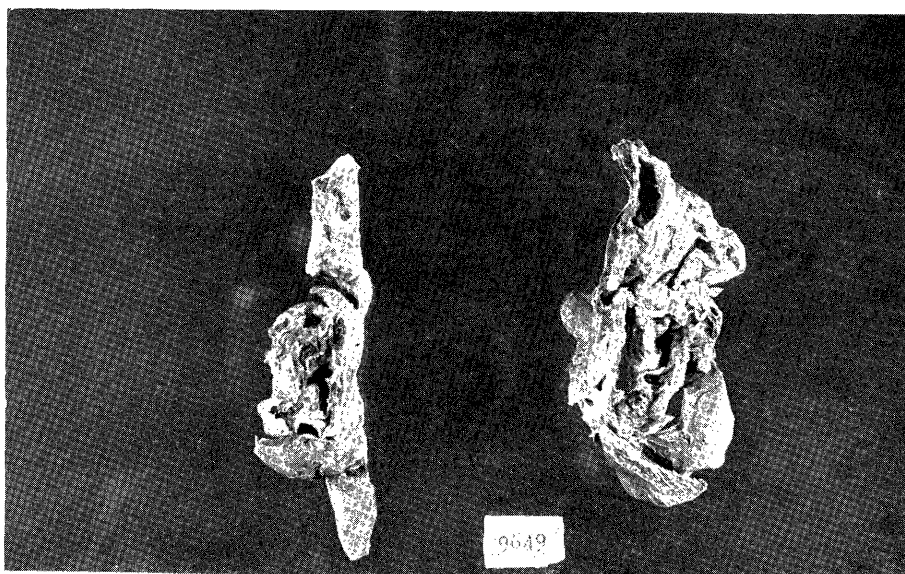


Fig. 2. Large multiple bronchogenic cysts and atelectatic lung parenchyma

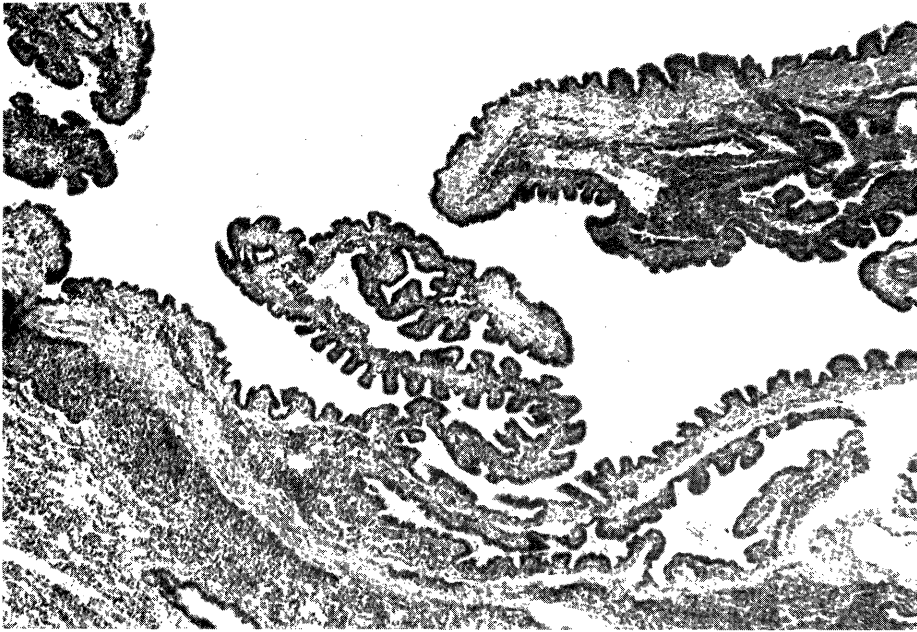


Fig. 3. A low power view of the cyst wall which is lined by ciliated columnar epithelium

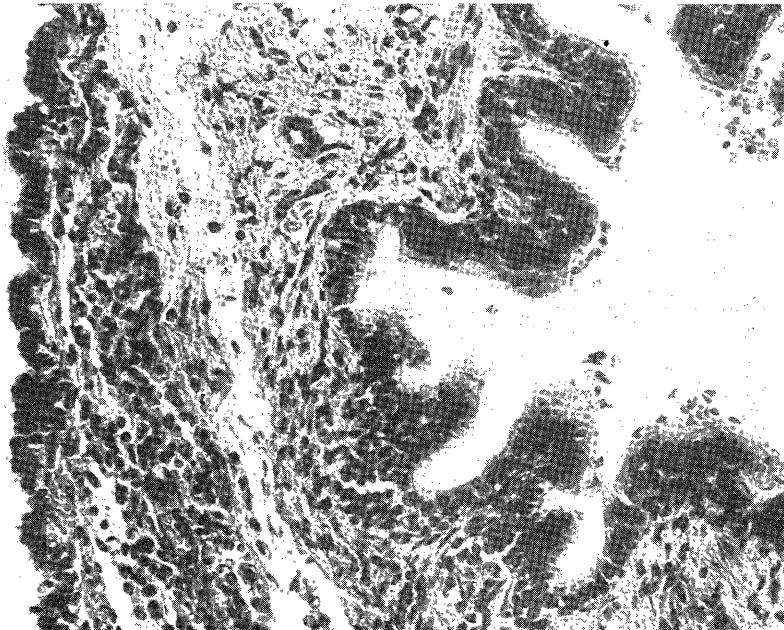


Fig. 4. A high-power view of the cyst wall surrounding by fine fibrous connective tissue

of the lungs.

No other abnormalities were present in the other organs.

Microscopically the cysts had a simple ciliated columnar lining which was similar to the bronchial epithelium. (Fig. 3, 4) The wall of the cysts was composed of fine fibrous connective tissue and muscle, however there was an absence of any cartilage or mucous glands in the wall. In the lumen of the cysts and also in the alveolar spaces there was edematous fluid and squamous cells with no evidence of an inflammatory cellular infiltrate.

The left lung was atelectatic and incompletely expanded.

The thymus and adrenal glands were atrophic. There was no evidence of visceral congestion in the liver, kidneys and spleen.

DISCUSSION

The cystic disease of the lung was first reported by NICOLAUS Fontanus in 1638. In 1607 THOMAS Bartholinus reported an autopsy case of a 4 year-old girl with air cyst of the lung.

In 1925 KOONTZ was able to summarize 108 cases of congenital cystic disease of the lung. Since then numerous publications⁽⁵⁾ on the subject have been reported. In Japan, however, there are only reports of 21 cases ⁽¹⁾⁽⁴⁾⁽⁸⁾⁽¹⁰⁾⁽¹⁴⁾ of the cystic disease of the lung in new-born infants.

There is still no clear definition or classification of congenital cystic disease of the lung. KUMAGAWA'S⁽³⁾ definition was as follows : Cysts or cystic dilatation in the lung, with air or fluid in them.

He excluded the cavities secondary to tuberculosis, abscess, tumors or parasites, and also classified the congenital cystic disease of the lung as shown in Table I because of the difference of developmental nature.

SPENCER⁽¹²⁾ in his classification of congenital bronchial cysts divided them into central and peripheral cysts mainly because of the differences

Table I

1. Bronchogenic cysts
 - a) Isolated cysts
 - b) Multiple cysts
 - c) Polycystic lung
 - d) Sequestration cysts
2. Alveolar cysts
 - a) Bulla
 - b) Bulla (including pneumatocele and vanishing lung)

Table II

1. Pulmonary bronchogenic cysts
 - a) Isolated
 - b) Multiple
2. Pulmonary bronchial cysts (Intraparenchymal solitary bronchial cyst)
 - a) Adenomatoid cystic disease
 - b) Ballon cysts
3. Mediastinal bronchogenic cysts

in the clinical picture and structure.

Recently, NIINOMI⁽⁷⁾ classified congenital disease of the lung as shown in table II.

The present case is considered to be multiple bronchogenic cysts as classified as table I, and pulmonary bronchial cyst-adenomatoid cystic disease as in table II. The congenital nature of lung cysts with infection may be difficult to prove. In this case, the cysts are considered as congenital lesions because clinical symptoms were noted 12 day after birth and there was no evidence of infection within the cysts.

Numerous theories have been proposed to account for the growth of congenital cysts: Most of the cysts are developmental anomalies in nature. KUMAGAYA⁽³⁾ stated that the frequent association of such cysts with other congenital abnormalities of the bronchial tree supports the view that they arise from arrested bronchial growth, and that bronchial pulmonary diseases in childhood may result due to development of the cysts. SPENCER⁽¹²⁾ also stated that congenital cysts have been thought to result from a local arrested development of the bronchial system.

POTTER'S⁽⁹⁾ description of cystic diseases of the lung is more typical in fetuses who are dead at birth or infants who live but a short time.

The sign and symptoms of this disease are extremely varied with the size of the cysts or presence of complications. If extensive, the disease may be incompatible with life. The remainder sometimes develop symptoms after birth and approximately one-half are asymptomatic until adult life. Most of the symptoms are of respiratory nature such as cough, dyspnea or tachypnea, and in our case cyanosis and other symptoms were severe and acute. The complications frequently seen in this disease are as follows: infection, pressure on the cardio respiratory organs due to an intra-thoracic expanding air space occupying lesion, rupture of cysts with formation of a tension pneumothorax and malignant change.

The present case developed symptoms the 12th day after birth. Grossly there was no evidence of communication of the cysts with the tracheobronchial tree. Histologically, however, there was evidence of amniotic fluid in the cysts, suggesting that the cysts communicated with the bronchial system.

The small single cyst with no symptoms, the cysts with no communication with the bronchial system, and the cysts with no infection nor overexpanding may be harmless, and thus surgical intervention may not be necessary. However, surgical treatment must be considered in cases with various complications such as infection or compression of the adjacent organs. Recently there have been many case reports^{(2),(6),(13)}, in which surgical procedures had good results.

SUMMARY

The clinical history and pathological findings in a case of an 18 day old new-born of the congenital cystic disease of the lung are described.

Clinically the child developed cyanosis, and dyspnea, and was thought to be due to pulmonary emphysema. The significant histopathological findings were multiple bronchial cysts in the right middle pulmonary lobe.

The case may be considered as the first one with congenital cystic disease of the lung found in new-born in Japan.

ACKNOWLEDGEMENT

The author's thanks are due to Dr. J. D. KIRSHBAUM, Senior Pathologist, ABCC, Nagasaki.

REFERENCES

- 1) ABE, T. and YAMAMOTO, M. : *Shonika Shinryo* 26 : 1424, 1964.
- 2) DENDA, T. and AKIYAMA, H. : *Jap. J. Chest Disease* 27 : 388-392, 1968.
- 3) KUMAGAYA, T. : *Tohoku Igaku Zasshi* 63 : 247-268, 1961.
- 4) MIYAMOTO, S. et al : *Jap. J. Thoracic Surg.* 18 : 930-933, 1965.
- 5) MOFFAT, A. D. : *J. Path. Bact.* 79 : 361-372, 1960.
- 6) MORIYA, A. and TAMURA, S. : *Jap. J. Thoracic Surg.* 18 : 435-439, 1965.
- 7) NIINOMI, F. et al : *Mie Med. J.* 16 : 93-103, 1966.
- 8) OISHI, T. and YAMADA, M. : *Shonika Shinryo* 26 : 1263-1267, 1963.
- 9) POTTER, E. L. : *Pathology of Foetus and Infant* : p. 305, 1962.
- 10) SATO, R. : *Jap. Med. J.* 2171 : 11-15, 1965.
- 11) SCHAFFER, A. J. : *Disease of the New Born* : p. 172, 1965.
- 12) SPENCER, H. : *Pathology of the Lung* : p. 86, 2nd Ed. 1968.
- 13) TAKEUCHI, K. : *Jap. J. Thoracic Surg.* 13 : 294-298, 1960.
- 14) TAKEUCHI, K. and HIROTA, S. : *J. Jap. Soc. Int. Med.* 52 : 1387, 1964.