

Case Report

Successful Management of an Elderly Patient with Dementia Using a Dual Gastric Tube After Surgical Treatment of Gastroduodenal Ulcer

Fumio KITAOKA¹⁾, Akio KAWAHARA¹⁾, Kaname ISHIZU²⁾, Yoshikazu NAKASHIMA¹⁾

1) Department of Surgery, Jikei-Sone Hospital

2) Department of Surgery, Youmeikai Obase Hospital

We describe a technique which was employed for simultaneous drainage and enteral nutrition using a dual gastric tube from a gastrostomy for postoperative management of a gastroduodenal ulcer. Gastrostomy was performed and a 18 Fr. gastric drainage tube was inserted into the body of the stomach intraoperatively. A second tube was inserted into the jejunum through the gastric tube postoperatively. Use of the gastric tube for drainage and the second tube for feeding enabled an early start of enteral nutrition without consideration of the gastric condition. The technique is simple and could be beneficial for patients who experience complications such as minor leakage and severe pylorus stenosis, particularly those in older age group with dementia.

ACTA MEDICA NAGASAKIENSIA 48 : 183–184, 2003

Key Words: *gastric tube, gastroduodenal ulcer, postoperative management*

Introduction

Continuous drainage of the stomach is very important for patients who undergo laparotomy for gastroduodenal ulcers, especially for those with complications of minor leakage and pylorus stenosis. An early initiation of enteral nutrition is also important.

We described a technique for conducting simultaneous drainage and enteral nutrition using a dual gastric tube.

Address Correspondence: Fumio Kitaoka, M.D.
Department of Surgery Jikei-Sone Hospital 4-2-19 Numahon-mach, Kokuraminami, Kitakyushu City 800-0208 Japan
TEL: +81-93-471-2881, FAX: +81-93-473-2921
E-mail: jikeisone@jikeikai.or.jp

A Case Report and Technique

A 96-year-old woman, with dementia was admitted to our hospital because of severe upper abdominal pain. An endoscopic examination revealed a large perforated ulcer in the posterior wall of the antrum. The ulcer was associated with infiltration and edema, resulting in severe stenosis of the pylorus. An emergency laparotomy was carried out. After trimming of the margins ulcer was sutured with an additional omental patch. Intraoperatively, a gastrostomy was done for drainage of gastric juice from the stomach body using an 18 Fr. naso-gastric tube (Terumo Co., Ltd., Tokyo, Japan). In addition, a second tube was in-

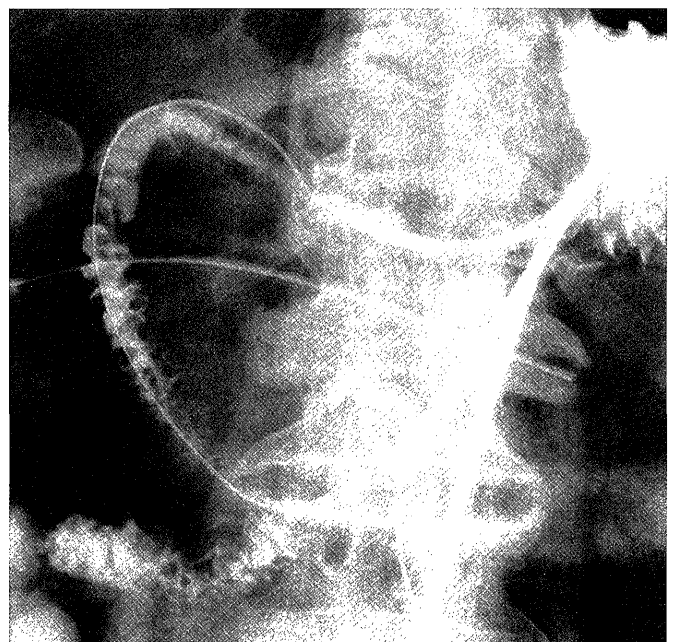


Figure 1. A duodeno-jejunoscopy from the second tube at 2 days postoperative.

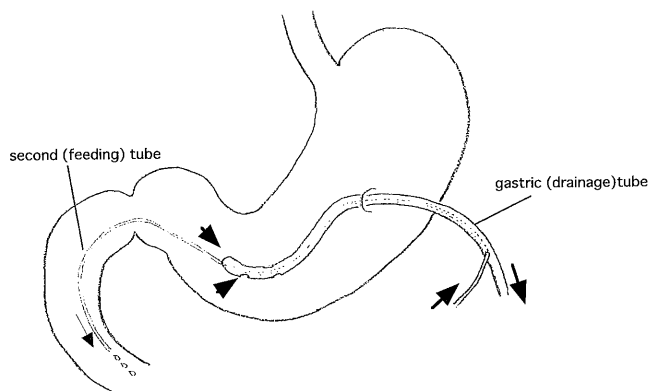


Figure 2. Schematic drawing of the double gastric tube.

serted into the gastric tube two days after surgery using a 5 Fr. silicone tube (Kaneka Co., Ltd., Osaka, Japan) Its tip was placed in the jejunum with a guide wire under fluoroscopic guidance (Figure 1). The second tube exited out of the middle part of the gastric tube. Enteral nutrition was started soon after insertion of the second tube (Figure 2). Although pylorus stenosis continued after surgery, the patient was managed without total parenteral nutrition (TPN). She was discharged on 12th postoperatively, and remained healthy at the time of this writing.

Discussion

Recently, less invasive surgical techniques such as patching with greater omentums and lavages have become standard for treating perforated gastroduodenal ulcers^{1, 2)} This has resulted in shortened postoperative hospital stay and early start of feeding, enabling postoperative treatment without TPN. In elderly or high-risk patients, however, postoperative complications such as leakage from a closed ulcer or pylorus stenosis often occur and tend to prolong duration of

gastric drainage and TPN. Early enteral nutrition is encouraged from the perspective of protection of the mucosal barrier system³⁾. However, drainage with naso-gastric tubes or enteral nutrition with a long jejunal tube is so stressful that it is not accepted for high-risk patients, especially elderly patients with dementia⁴⁾.

Dual gastric tube could be an alternative in such situation (1) It has advantage of being less stressful for patients compared to naso-gastric tubes, and in also less invasive because of its two-way activity in just one tube. (2) It also enables early instituhm of enteral diet without considering the gastric condition. In this procedure, second tube was inserted postoperatively. Second tube could also be inserted thorough the pylorus ring intraoperatively, if severe pylorus stenosis is noticed peroperatively.

We used a 5 Fr. silicone tube as the feeding tube, through a 6 Fr. or larger tube may be necessary for smoother feeding. Although the dual tube technique employed by us has not been reported before the 'catheter-in-catheter' concept has recently been reported⁵⁾. We believe that this technique offers possibilities not only for postoperative treatment of gastroduodenal ulcers, but also for pylorus-preserving pancreaticoduodenostomy.

References

1. Michelet I, Agresta F: Perforated peptic ulcer: laparoscopic approach. *Eur J Surg.* 2000; 166:405-8.
2. Naesgaard JM, Edwin B, Reiertsen O, Trondsen E, Faerden AE, Rosseland AR: Laparoscopic and open operation in patients with perforated peptic ulcer. *Eur J Surg.* 1999;165:209-14.
3. Bengmark S: Enteral nutrition in HPB surgery: past and future. *J Hepatobiliary Pancreat Surg.* 2002; 9: 448-58.
4. Hollands MJ, Fletcher JP, Young J: Percutaneous feeding gastrostomy. *Med J Aust.* 1989; 18:330-1.
5. Hauenschild A, Schnell-Kretschmer H, Teichmann J, et. al. Prospective evaluation of novel system for jejunal feeding. *Surg. Endosc.* 2003;17: 452-6.