

## Case Report

# Spontaneous Pneumomediastinum: Report of a Case and Review of Literature

Kengo KANETAKA<sup>1,4)</sup>, Kenichiro TSUJI<sup>2)</sup>, Toshihiko TSUDA<sup>2)</sup>, Hiroaki TAMURA<sup>3)</sup>, Junji KITAJIMA<sup>3)</sup>, Takashi KANEMATSU<sup>4)</sup>

1) Department of Surgery, Naru Hospital

2) Department of Internal Medicine, Naru Hospital

3) Department of Surgery, Goto Central Hospital

4) Second Department of Surgery, Nagasaki University School of Medicine

**Spontaneous pneumomediastinum, defined as the presence of free air in the mediastinal structures, is a rare disease that usually take a good course with conservative therapy. However, clinicians are usually unfamiliar with the disease because of its infrequency. We report herein a case of spontaneous pneumomediastinum following an episode of violent cough. The patient was treated conservatively after hospitalization and got well without any medical problems. In addition we reviewed characteristics of spontaneous pneumomediastinum reported so far in the Japanese literature. The result of our review suggests that the typical patient with spontaneous pneumomediastinum is a young man with a slender build. In most patients, spontaneous pneumomediastinum occurs in conjunction with condition causing high airway pressure. None of the patients described in the literature developed serious complications such as cardiac insufficiency or airway compromise, and none of the cases without concomitant pneumothorax required any medical care. In conclusion, familiarity with this rare disease is crucial to provide appropriate treatment.**

ACTA MEDICA NAGASAKIENSIA 48 : 67–70, 2003

**Key Words:** spontaneous pneumomediastinum

## Introduction

Spontaneous pneumomediastinum (SPM) may be defined as the presence of free air in the mediastinal structures without apparent precipitating cause. The

condition is caused by a sustained increase in the intraalveolar and intrabronchial pressure with extravasated air dissecting along the perivascular spaces of the mediastinum.<sup>1)</sup>

SPM is a rare disease that usually takes a good course with conservative therapy.<sup>2)</sup> However, clinicians are usually unfamiliar with the disease because of its infrequency. This unfamiliarity sometimes results in a missed or delayed diagnosis.

We report herein a case of SPM following an episode of violent cough. To improve clinical recognition of this disease, we reviewed characteristics of SPM presentation as reported in the Japanese literature.

## Case Report

A 15-year-old male presented to Naru hospital complaining of sudden dyspnea and chest pain following a violent cough. There was no history of recent trauma or aspiration of a foreign body. The patient had no prior history of medical or surgical disease. He was a healthy-looking boy with a body weight of 47 kg and a height of 1.68 m. Upon examination, there was obvious subcutaneous emphysema of his upper chest and neck with palpable crepitation. Hamman's crunch was not detected on auscultation of the heart. The patient had a slight fever, but his other vital signs were quite stable. Chest x-ray showed extensive subcutaneous emphysema and pneumomediastinum, but no pneumothorax (Fig. 1). A CT scan of the chest confirmed extensive subcutaneous emphysema in the neck, the left axillary portion, and the pneumomediastinum (Fig. 2). Laboratory data showed no abnormality except for a white blood cell count of 16100 and CRP of 0.76. Although the most appropriate diagnosis appeared to

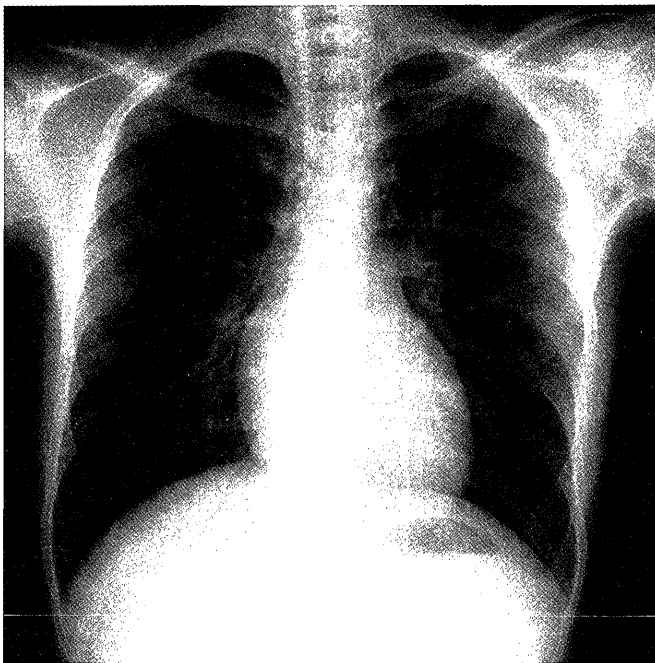
**Address Correspondence:** Kengo Kanetaka, M.D.

Department of Surgery, Naru hospital, 1644 Urago, Minamimatsuura-gun, Nagasaki 853-2201

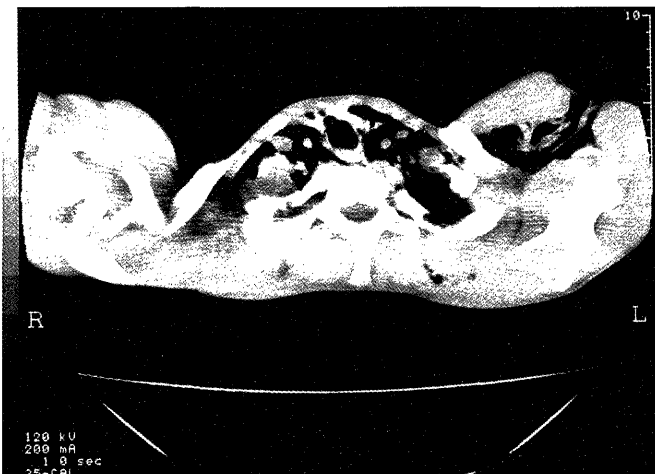TEL: +81-959-64-2014 FAX: +81-959-64-3447

E-mail address: naru hosp@bronze.ocn.ne.jp

be spontaneous pneumomediastinum, we could not rule out the possibility of secondary pneumomediastinum. The patient was therefore placed on bed rest with prophylactic antibiotic therapy after hospitalization. The next day, his clinical symptoms disappeared so invasive medical check-up such as gastroscopy and bronchoscopy were not carried out. On the sixth hospital day, the follow-up CT scan of the chest showed complete resolution of pneumomediastinum: The disease did not recur in 6 months of follow-up.



**Figure 1.** Chest x-ray showed extensive subcutaneous emphysema in the left axillary portion and pneumomediastinum. No pneumothorax was found.



**Figure 2.** Chest CT scan confirmed extensive subcutaneous emphysema in the neck, the left axillary portion, and the pneumomediastinum.

## Discussion

SPM, which is thought to result from a wall laceration of the alveoli caused by a sudden increase in intrapulmonary pressure, develops in patients with no serious underlying pulmonary disease. This clinical entity was increasingly recognized after Hamman described a series of cases in 1939.<sup>3)</sup> However, in Japan it is a rare condition, with clinicians having encountered only approximately 100 reported cases. To increase clinical awareness of this condition, we searched for case reports of spontaneous pneumomediastinum in the Japanese literature between 1983 and 2001 through the Japana Centra Revuo Medicina searching system. One-hundred-three patients diagnosed as SPM were identified and reviewed.

The characteristics of the SPM patients are listed (Table. 1). Similar to recent reports,<sup>4)</sup> we found the typical SPM patient to be a young man, in his 20s, with a relatively slender build. Predisposing factors for SPM development could be identified in 72 patients (70.0 %). Among these identified factors, strained utterance was most frequent. This prevalence is in clear contrast with that reported by Panacek, who identified the most frequent cause as abuse of an inhalational drug.<sup>5)</sup> As regards the etiology of SPM, Matsushima et al. have suggested that strained utterance during mass training might be a primary cause of SPM in Japanese society.<sup>6)</sup> Many clinicians have considered SPM as an emergency setting; however, 39 patients (40.2 %) among 97 well-documented cases have reportedly come to the hospital more than 24 hours after onset. This relatively long period between onset and going to the hospital implies that the symptoms of some patients are so subtle that they could possibly recover at home without any medication.

**Table 1.** The characteristics of the patients with spontaneous pneumomediastinum

Mean age (yr) (range)	19.5	(7-65)
Male : Female	80 : 23	
BMI(range) *	19.7	(15.1-30.0)
Conditions at onset (%)		
Not particular	31	(30.0)
Strained utterance	24	(23.3)
Athletic Activity	23	(22.3)
Vomiting	6	(5.8)
Working	6	(5.8)
Coughing	3	(2.9)
Other	10	(9.7)
Came to hospital (%)		
Within a day after onset	58	(59.8)
More than 24 hours after onset	39	(40.2)

\*BMI: The body mass index, calculated with formula of "body weight (kg)/ height (m)<sup>2</sup>"

The presenting symptoms and signs of patients with SPM are listed (Table. 2). At presentation, all patients had one or more symptoms that could be related to the presence of a pneumomediastinum. Chest pain was the predominant symptom (68.0 %). Sixty-five patients had symptoms of discomfort related to their neck or throat (neck pain, neck swelling, or swallowing pain). Thirty-five patients complained of dyspnea of varying severity. On physical examination, 11 cases (10.7 %) had neither subcutaneous emphysema nor Hamman's crunch, which is spontaneous mediastinal crepitation occurring with each heartbeat. In these cases, the diagnosis of SPM was made roentgenographically. Therefore, we must emphasize the importance of obtaining a chest radiograph in patients suspected of SPM. The chest radiograph is not only crucial to making the diagnosis of SPM, and but is necessary to rule out the possibility of a concomitant pneumothorax, which may occur if the mediastinal pressure rises abruptly. Bouwen et al. have reported that in 10-18 % of cases, SPM is associated with a pneumothorax.<sup>7</sup> However in our review, pneumothorax appears to be a relatively uncommon complication (3.9 %).

**Table 2.** The presenting symptoms and signs of patients with spontaneous pneumomediastinum

Symptoms (%)		
Chest pain	70	(68.0)
Dyspnea	35	(34.0)
Neck pain	34	(33.0)
Swallowing pain	32	(31.1)
Chest discomfort	10	(9.7)
Neck swelling	9	(8.7)
Signs (%)		
Subcutaneous emphysema	83	(83.8)
Localized at the neck	50	(60.2)
Extending beyond the neck	33	(40.0)
Hamman's crunch	36	(41.0)
None	11	(10.7)
Concomitant pneumothorax (%)	4	(3.9)
Fever elevation (%)	27	(26.2)

It must often be difficult to differentiate SPM from other secondary causes of pneumomediastinum, which may require specific aggressive medical therapy. When encountering pneumomediastinum, the physician must consider esophageal rupture, particularly in patients with chest pain after vomiting, which accounts for 5.8 % of the etiology of SPM. We have therefore attempted to identify differences between SPM and esophageal ruptures. Flynn et al. have reported that 59 % of patients with esophageal rupture have a temperature greater than 38.0 °C at diagnosis.<sup>8</sup> In this review, only 2 cases were identified as having such a high temperature, although 27 patients were described to have had mild to low-grade fever elevations. Hence, high fever might strongly indicate the necessity of further examination

such as gastroscopy or a Gastrographin esophagogram to exclude esophageal rupture. On the other hand, a high grade fever does not always indicate bacterial contamination in SPM. It is believed that as introduction of air into subcutaneous or mediastinum tissues is limited to a single episode in SPM, bacterial contamination is unlikely.<sup>9</sup> In fact, we found no reported cases having developed secondary suppurative mediastinitis.

The clinical course and outcome of patients with SPM are summarized (Table. 3). Sixty-eight patients with SPM were admitted to the hospital for close observation. The length of the hospital stay ranged from 1-39 days, with a mean of 9.4 days. Another 14 cases were followed in an outpatient setting without any medical problems. None of the reported patients developed related complications such as secondary mediastinitis, cardiac insufficiency, or airway compromise.

**Table 3.** The clinical course and outcome of patients with spontaneous pneumomediastinum

Admitted to hospital (%)	68	(82.9)
Outpatient follow-up (%)	14	(17.1)
Mean length of hospital stay (range)	9.4	(1-39)
Mean duration of symptoms (range)	4.8	(1-14)
Mean duration of abnormal chest radiograph (range)	7.9	(1-30)
Therapy (%)		
Conservative	97	(94.2)
Interventions	6	(5.8)

Six patients had interventions: four required placement of a chest tube for pneumothorax, and one of these underwent endotracheal intubation for bilateral pneumothoraces. One underwent surgery for a suspected esophageal rupture, while the other underwent a tracheotomy for decompression of air.

Our patient was admitted to make a close observation. However almost all patients in the literature did not require a specific intervention directly relating to the presence of pneumomediastinum, and none of the uncomplicated cases required any medical care. Macklin and Macklin have emphasized potential complications such as cardiac compression and reduction in cardiac output caused by tension pneumomediastinum and an inability to exchange air due to increased air within the pulmonary interstitial tissue.<sup>11</sup> We believe that patients developing such serious complications are extremely rare, although our study looked only at cases of SPM reported in Japanese.

Because of the scarcity of individual experience with this uncommon entity, many researchers have recommended close observation of patients, especially after hospitalization. We suggest that SPM usually does not require hospitalization if the diagnosis is secure and concomitant pneumothorax is not present. With the recent increased awareness of this disease, reports of

SPM after exercise and voice training have been increased. Familiarity with the disease is crucial to appropriate treatment.

#### References

1. Macklin, MT, Macklin CC. Malignant interstitial emphysema of the lungs and mediastinum as an important occult complication in many respiratory diseases and other conditions: interpretation of clinical literature in light of laboratory experiment. *Medicine* 23: 281-358, 1994
2. Abolnik, I, Lossos IS, Breuer R. Spontaneous pneumomediastinum. A report of 25 cases. *Chest* 100: 93-5, 1991
3. Hamman, L. Spontaneous mediastinal emphysema. *Bull Johns Hopkins Hosp* 64: 1-21, 1939
4. Fallon, KE, Foster K. Pneumomediastinum in a surf lifesaver. *Br J Sports Med* 30: 359-60, 1996
5. Panacek, EA, Singer AJ, Sherman BW, Prescott A, Rutherford WF. Spontaneous pneumomediastinum: clinical and natural history. *Ann Emerg Med* 21: 1222-7, 1992
6. Matsushima, T, Yoneyama H, Yano T. Spontaneous mediastinal emphysema caused by strained utterance. Is it characteristic of the Japanese? *Chest* 108: 885-6, 1995
7. Bouwen, L, Bosmans E. Posttraumatic pneumomediastinum: not always cause for alarm. *Acta Chir Belg* 97: 145-7, 1997
8. Flynn, AE, Verrier ED, Way LW, Thomas AN, Pellegrini CA. Esophageal perforation. *Arch Surg* 124: 1211-4; discussion 1214-5, 1989