

Surgical Strategy for Low Imperforate Anus in Girls -Cutback Anoplasty, Anal Transplantation or Limited Posterior Sagittal Anorectoplasty?-

Masayuki OBATAKE, Hideki YAMASHITA, Hisakazu SHINDO, Norihisa SUMIDA, Tohru NAKAGOE

Division of Surgical Oncology, Department of Translational Medical Sciences, Nagasaki University Graduate School of Biomedical Sciences

From 1991 to 2001, we performed 5 re-operations with limited posterior sagittal anorectoplasty (PSARP) for low imperforate anus in girls who had anteriorly located anus after primary surgery. Four girls were diagnosed with anocutaneous fistula and one girl with anovestibular fistula. Primary operations were one cutback anoplasty and four anal transplantation. None of them underwent colostomies before re-operation with the limited PSARP. The sphincter muscle was cut through a median perineal skin incision and then the rectum was placed at the center of the complex muscles. This limited PSARP could give good anal function and satisfactory cosmetic appearance .

ACTA MEDICA NAGASAKIENSIA 48 : 51–54, 2003

Key Words: low imperforate anus, cutback anoplasty, anal transplantation, posterior sagittal anorectoplasty

Introduction

Cutback anoplasty and anal transplantation (Potts transfer anoplasty) are commonly used as simple and safe procedures in the surgical repair of patients with low imperforate anus with good bowel function during the infantile period. Creating an anal opening by cutback anoplasty is apt to be close to the vaginal vestibule and the posterior perineal commissure. However, anal transplantation is usually performed in a more or less blind manner. Therefore, it is not always certain whether the rectum has been accurately passed through the sphincter muscle or not. Both procedures may cause anteriorly located anus, and may result in problems

Address Correspondence: Masayuki Obatake, M.D.

Division of Surgical Oncology, Department of Translational Medical Sciences, Nagasaki University Graduate School of Biomedical Sciences 1-7-1 Sakamoto, Nagasaki 852-8501 Japan
TEL: +81-95-849-7304 FAX: +81-95-849-7306
E-mail: mobatake@net.nagasaki-u.ac.jp

with continence during long-term follow-up. In girls, an anteriorly located anus may produce vaginal soiling and urinary tract infections.

We report our experience with 5 girls who had anteriorly located anus after primary surgery of cutback anoplasty or anal transplantation for low imperforate anus.

Patients and Methods

Between 1991 and 2001, 17 girls underwent operative repair at our institution for low imperforate anus. In the operative repair, cutback anoplasty and anal transplantation was performed. Of these two operative repair, cutback anoplasty was used only in patients with an anocutaneous fistula close to the center of the sphincter muscle. Anal transplantation was performed for patients with an anovestibular fistula or an anocutaneous fistula close to the vestibulum. Post-operatively, all patients were followed at the outpatient clinic. Five girls (ranging in age from 8 months to 9 years) (table 1) had persistent complications of anteriorly located anus, mucosal prolapse or constipation, and these five patients are the subjects in this study.

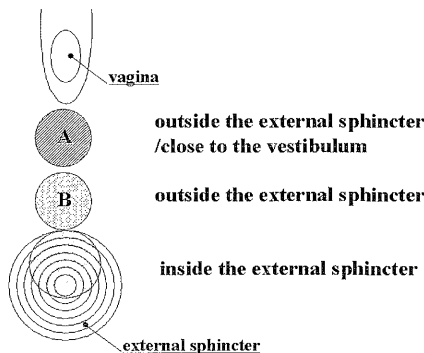
We classified the anteriorly located anus into two groups: (A) and (B). An anal opening of both groups was located outside the external sphincter muscle. The anal opening in group (A) was located close to the vestibulum. The anal opening in group (B) was located between the external sphincter muscle and area (A). Three patients were belong to the group (A), and other two patients were group (B) (Fig. 1).

At initial presentation, four girls were diagnosed with anocutaneous fistula and one girl with anovestibular fistula. One girl with anocutaneous fistula underwent cutback anoplasty at the first operation. Four girls with anocutaneous fistula and one girl with anovestibular

Table 1. Profiles of Patients who had persistent complications of anteriorly located anus.

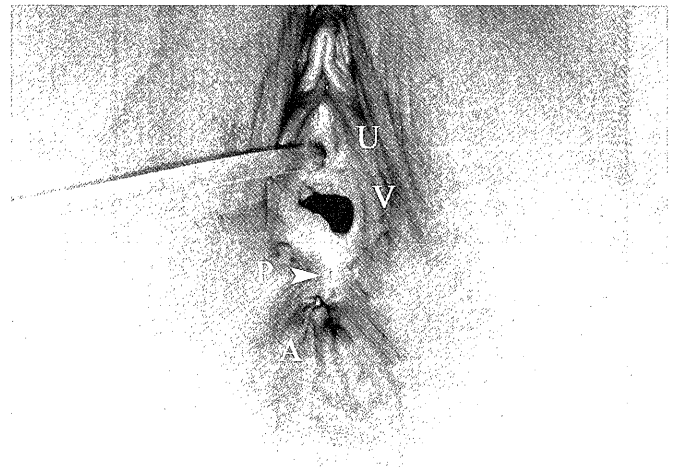
Case No.	diagnosis	Primary operation				Reoperative anooplasty with limited PSARP*
		age	procedure	postoperative course	anal position	age
1	Ano-vestibular fistula	4mo	anal transplantation	anteriorly located anus, constipation	A	9yr3mo
2	Ano-cutaneous fistula	1y4mo	anal transplantation	anteriorly located anus	A	5yr1mo
3	Ano-cutaneous fistula	3mo	anal transplantation	anteriorly located anus, constipation	A	3yr4mo
4	Ano-cutaneous fistula	9mo	anal transplantation	anteriorly located anus, anal stenosis, constipation	B	1yr2mo
5	Ano-cutaneous fistula	1day	Cut back	anteriorly located anus, mucosal prolapse	B	8mo

*PSARP; posterior sagittal anopectoplasty

**Figure 1.** Anal position after initial operation

fistula underwent anal transplantation. Post-operatively, one of the girls with anovestibular fistula (case 1) developed a rectovaginal fistula and underwent diverting colostomy. Secondary anal transplantation was done 2 months later. The one girl who underwent cut-back procedure had an anteriorly located anus and mucosal prolapse at the anterior edge of the created anus. At primary operation, the newly created anus of the four girls who underwent anal transplantation was made at the center of the external sphincter muscle which was detected by electrical stimulation. However, it was gradually displaced anteriorly, close to the posterior perineal commissure (Fig. 2). Two girls had constipation and irregularly took medications. One girl received post-operative anal dilatation and used daily bowel enemas.

No colostomies were performed before any of the five re-operations. The bowel was prepared by polyethylene glycol and a cleansing enema the day prior to surgery. The operation began with the patient being held in a jackknife position. A circular incision was made in the

**Figure 2.** Outward appearance of the anal region at operation. The arrow shows the narrow perineal body. U; urethra, V; vagina, A; anus

mucocutaneous junction at the opening of the already created anus. This incision extended posteriorly along the median line to the posterior margin of the external sphincter muscle, which was previously detected by electrical stimulation. The anterior rectal wall was carefully separated from the posterior vaginal wall. The length of the fistula to be dissected was 3 cm. The fistula underwent reconstruction by surrounding it with complex muscle. Two weeks after the operation, daily gentle dilatation was performed using Hegar dilators.

Results

Postoperative anal appearance (case 1) is shown in Fig 3. An anal opening was located inside the external

sphincter muscle, and there was adequately spaced from the posterior perineal commissure.

Two girls experienced partial wound dehiscence. In one patient, re-suturing of the rectal wall to the skin was performed 3 weeks after the operation. All patients had post-operative anal stricture and needed daily anal dilatation by Hegar for 4 to 8 weeks after surgery. Follow-up period after the limited PSARP was for 3 months to 2 years. Four of 5 patients are still too young to evaluate the outcome of the operation. All patients have voluntary bowel movements without laxatives.

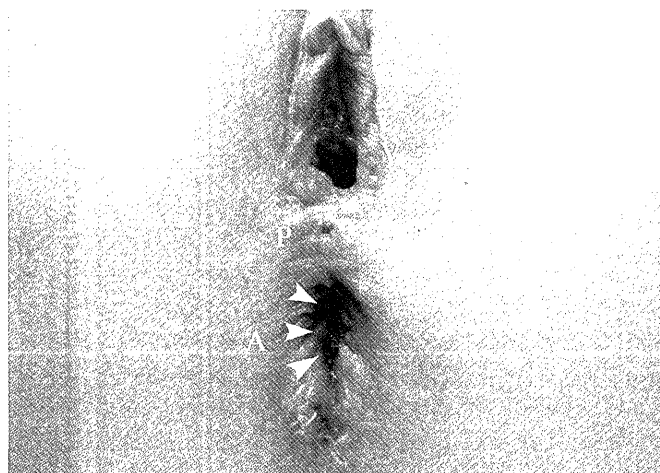

Figure 3. Anal appearance of 4 weeks postoperation (same patient as fig 1). The arrows show the newly created anus. P; perineal body showed enough space between the vagina (=V) and the anus (=A).

Conclusions

Cutback anoplasty and anal transplantation are well accepted procedures for their simplicity and safety in the treatment of low imperforate anus.^{1),2),3)} In recent years, cutback anoplasty has been abandoned in favor of anal transplantation. However, this simple method still has the advantage of safety, reliability and is less invasive for neonates as a primary surgery in low type anal malformation, especially in anocutaneous fistula. On the other hand, cutback anoplasty had been reported to have the disadvantage of contaminating the vagina and urethra and causing soiling or staining due to mucosal prolapse.⁴⁾ In adulthood, there may be a potential for laceration of the narrow septum between the vagina and the anal opening during vaginal delivery.⁴⁾ Mucosal prolapse may result, in that the anterior edge of an anal opening made by cutback anoplasty located outside the external sphincter muscle (Fig 4). Furthermore, this anal opening looks longer than wider

and is close to the vaginal vestibule and the posterior perineal commissure. There are many studies which have reported on post-operative anal function, but few have described sexual functions.^{5),6),7)} Rintala et al. reported on sexual functions in adult patients who had been operated on for low imperforate anus. 13 percent of the patients, including both males and females, had difficulties with sexual functions.⁷⁾ Perineal morphologic abnormality in female patients after cutback procedure may be a primary factor for avoidance of sexual intercourse.

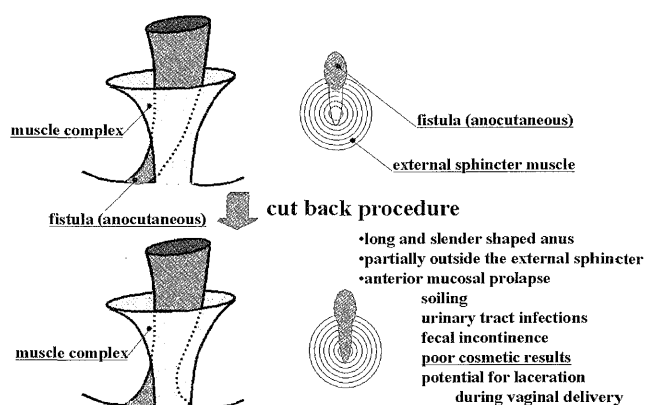


Figure 4. Operative technique: cutback anoplasty

The anal openings in anal transplantation are made at an estimated position using the electric muscle stimulator.⁸⁾ It has excellent cosmetic results, without visible operative scars, and provides a sufficient length of the perineal body, which prevents contamination of vagina and urethra. Some authors have reported complications, such as stenosis and refistulization.⁴⁾ In our study, refistulization was found in only one patient. Careful colon preparation and postoperative parenteral nutrition was performed in place of colostomy. Despite positioning the newly created anus inside the external sphincter muscle, anterior anal displacement has been reported.⁶⁾ One explanation for this displacement may be that insufficient separation of the anterior rectal wall from the posterior vaginal wall induced anterior traction of the newly created anus. In addition to this, it is not always certain that the rectum is completely passed through inside the muscle complex in an anatomically proper way (Fig 5).

Low imperforate anus in girls can be successfully managed with cutback anoplasty and anal transplantation without colostomy, with minimal operative complications. Although most patients acquire good anal function after these procedures, some continue to have problems with constipation, soiling, mucosal prolapse and an unsightly perineum caused by anterior located

anus. Especially for girls, the anterior located anus happened contamination to the urethra and vagina. Once the anterior located anus has happened after cutback anoplasty and anal transplantation, limited PSARP is an excellent approach for reconstruction and placement of the anus and rectum in the best position.

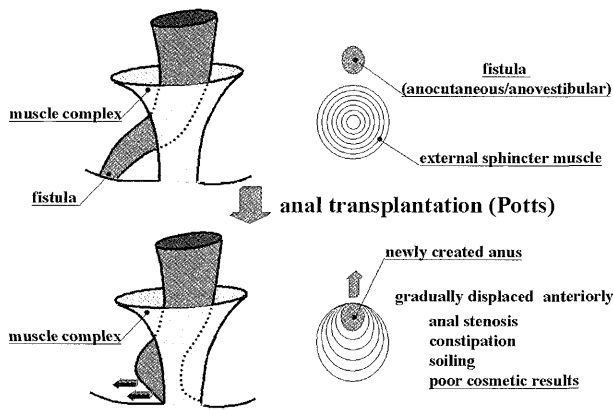


Figure 5. Operative technique: anal transplantation (Potts)

Our strategy for low imperforate anus in the neonatal period is fistula dilatation for creating the anus. Then, we perform limited PSARP^(9),10) at the age of six months, when both the vaginal and rectal walls are

thick and firm enough for manipulating, resulting in good bowel function and satisfactory cosmetic appearance in the perineum.

References

1. Nixon HH, Puri P: The results of treatment of anorectal anomalies: a thirteen to twenty year follow-up. *J Pediatr Surg* 12: 27-37, 1977
2. Partridge JP, Gouch MN: Congenital absence of the anus and rectum. *Br J Surg* 99: 37-50, 1961
3. Stephens FD, Smith ED. Operative management of rectal deformities. In *anorectal malformations in children* (Year Book, Chicago) pp 212-257, 1971
4. Templeton J, O'Neill J. Anorectal malformations. In *Welch KJ (ed) Pediatr surgery, 4th edn.* (Year Book Medical Publisher, Chicago) pp 1027-1035, 1986
5. Javid PJ, Barnhart DC: Immediate and long-term results of surgical management of low imperforate anus in girls. *J pediatr Surg* 33: 198-203, 1998
6. Okada A, Kamata S: Anterior sagittal anorectoplasty for rectovestibular and anovestibular fistula. *J Pediatr Surg* 27: 85-88, 1992
7. Rintala R, Mildh L: Fecal continence and quality of life in adult patients with an operated low anorectal malformation. *J Pediatr Surg* 27: 902-905, 1992
8. Saxena N, Bhattacharyya CN: Perineal anal transplantation in low anorectal anomalies. *Surgery* 90: 464-467, 1981
9. Pena A: Surgical management of anorectal malformations: a unified concept. *Pediatr Surg Int* 3: 82-93, 1988
10. Pena A: Posterior sagittal anorectoplasty: results in the management of 332 cases of anorectal malformations. *Pediatr Surg Int* 3: 94-104, 1988