

# Utilization of Jejunal Segment has Benefit for Reconstruction of the Extrahepatic Bile Duct in the Canine

Takashi FUJIWARA, Tsutomu TOMIOKA, Yoshitsugu TAJIMA, Takashi KANEMATSU

Second Department of Surgery, Nagasaki University School of Medicine

The feasibility of utilization of the jejunal segment or appendix as the substitute for reconstruction of the common bile duct in biliary surgery was investigated in the canine. Four dogs were used the appendix for biliary reconstruction, and 3 died within 3 months because of cholangitis associated with a stenosis of the anastomotic portion. Nevertheless, 9 dogs, which were replaced by the jejunal segment, survived with no serious complications. Values of serum chemistries were within the normal range during the observation period of 12 months after surgery. No bile leakage, anastomotic stenosis or dilatation of the common bile duct were observed on fistulography from the T-tube examined after surgery. Postmortem histological examination of the graft tissue showed presence of clear distinction between the mucosa of the bile duct and the small intestine. In addition, the epithelium of the small intestine was atrophic and resemble to the adjacent biliary epithelium. Thus, replacement of the intestinal segment reformed by absorbable autosuture appears to be clinically useful for reconstructive biliary surgery which can preserve the function of the papilla in selected patients.

ACTA MEDICA NAGASAKIENSIA 48 : 45–50, 2003

**Key Words:** biliary tract surgery, extrahepatic bile duct, surgical reconstruction, jejunal segment

## Introduction

The iatrogenic bile duct injury during operations of the biliary tract<sup>1,2)</sup>, especially during laparoscopic cholecystectomy<sup>3,4)</sup>, has been increasing in patients undergoing biliary reconstruction. Usually, a Roux-en-Y hepaticojejunostomy and hepaticoduodenostomy are procedures of choice in such traumatic or benign stricture cases<sup>5-7)</sup>. However, a Roux-en-Y hepatico-jejunostomy and hepaticoduodenostomy are not always the ideal recon-

struction procedure regarding both physiological and anatomical aspects. Food and digestive juice refluxed into the jejunal loop, which sometimes causes cholangitis. Moreover, the reflux of pancreatic and duodenal juice into the biliary tract might also be a risk factor for intra- or extrahepatic bile duct carcinoma<sup>8)</sup>. The condition of the patients after a Roux-en-Y hepaticojejunostomy and hepaticoduodenostomy might be similar to that of a pancreato-biliary maljunction<sup>9,10)</sup>. We previously pointed out the risk of pancreatic and duodenal juice for developing carcinogenesis of the biliary tract<sup>11)</sup>. Thus, Roux-en-Y hepaticojejunostomy and hepaticoduodenostomy for reconstruction of the extrahepatic bile duct, should be carefully selected, especially in young patients.

A graft of the jejunal segment in animals has been described by several workers as being ideal for either a total or partial replacement of the extrahepatic bile duct<sup>12,13)</sup>. However, a small intestinal segment was usually grafted across the longitudinal axis of the common bile duct as an end to side anastomosis because of the technical difficulties. These techniques do not allow for bile duct replacement at the different lengths needed to bridge the defect. Most animals could not tolerate the procedure because of persistent cholangitis after surgery. In the present study, the small intestinal segment was utilized longitudinally to the axis of the common bile duct by using an absorbable autosuture to match the diameter of the jejunum and to avoid the development of bile stasis and cholangitis.

## Materials and Methods

### Animals

Thirteen mixed-breed male dogs, weighting 9-12kg, were used. The animals were housed in cages and kept under standard laboratory conditions at the Laboratory Animal Center for Biochemical Research, Nagasaki University School of Medicine. The animals were given a standard pellet diet and water ad libitum throughout the experiment. All the experiments were done in accor-

**Address Correspondence:** Takashi Fujiwara, M.D.  
Second Department of Surgery, Nagasaki University School of Medicine, 1-7-1 Sakamoto, Nagasaki 852-8501, Japan  
TEL: +81-95-849-7316, FAX: +81-95-849-7319

**Table 1.** Characteristics of the appendix and intestinal segment groups

Groups	No. of animals examined	Observations periods ( month )	Bacteriologic examination (positivity)	Cholangiography	Superior mesenteric arteriography	Histologic findings
Appendix group	4	4.5	N.D.	N.D.	N.D.	stenosis and cholangitis
Intestinal segment groups ( 3 months after operation )	5	3	0%	No leakage No stenosis	Scant blood flow was shown.	No stenosis No signs of cholangitis Atrophy of the epitherium
( 12 months after operation )	4	12	0%	No leakage No stenosis	Blood supply was decreased in all animals.	No stenosis No signs of cholangitis Atrophy of the epitherium

dance with the Guidelines for Animal Experimentation bacteriologically.

#### *Bacteriologic Examination*

The intraoperative smears of bile from the all animals, as well as the smears of bile obtained during percutaneous transhepatic cholangiography after initial surgery, were bacteriologically examined.

#### *Laboratory parameters*

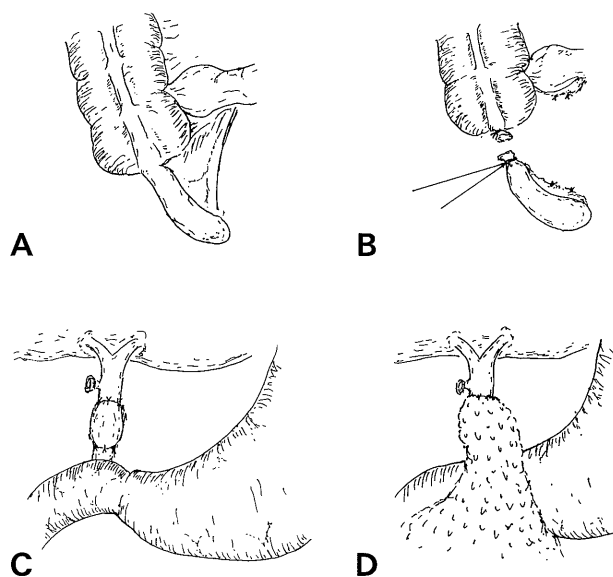
The serum levels of glutamic oxalacetic transaminase (GOT;normal<50IU/L), glutamic pyruvate transaminase (GPT;normal<50IU/L), alkaline phosphatase (ALP;normal<6KAU), total bilirubin (TB;normal <1.0mg/dl), and amylase (Amy;normal < 4000IU/L) were evaluated on the day of the first operation, one month after the operation and on the day of the second operation in each group. If the parameters were abnormal, then the plasma was thereafter checked monthly.

#### *Surgical Techniques and Experimental Protocol*

Following the intravenous administration of Nembutal anesthesia (25mg/kg of body weight), an upper abdominal midline incision was made and a cholecystectomy was done in all animals, and then, the abdomen was closed. The cholecystectomy was done in order to induce the spontaneous dilatation of the common bile duct. Two months later, the common bile was grossly dilated. Thus, 2 months after the primary operation the second operation was given. When the abdomen was re-opened, under satisfactory general anesthesia, the extrahepatic bile duct was exposed. The center of

the bile duct was surgically resected in 1-2 cm in length. These procedures were done in 13 dogs and those were divided into two groups according to the replacement materials i.e., 4 animals underwent a biliary reconstruction using the appendix (Appendix group), while 9 animals underwent a reconstruction using the intestinal segment (Intestinal group).

In the appendix group, one cm of the appendix was grafted into the common bile duct and was covered with the greater omentum in order to protect against bile leakage and to feed the wall of the bile duct by perfusion without arterial anastomosis (Fig 1A-D).

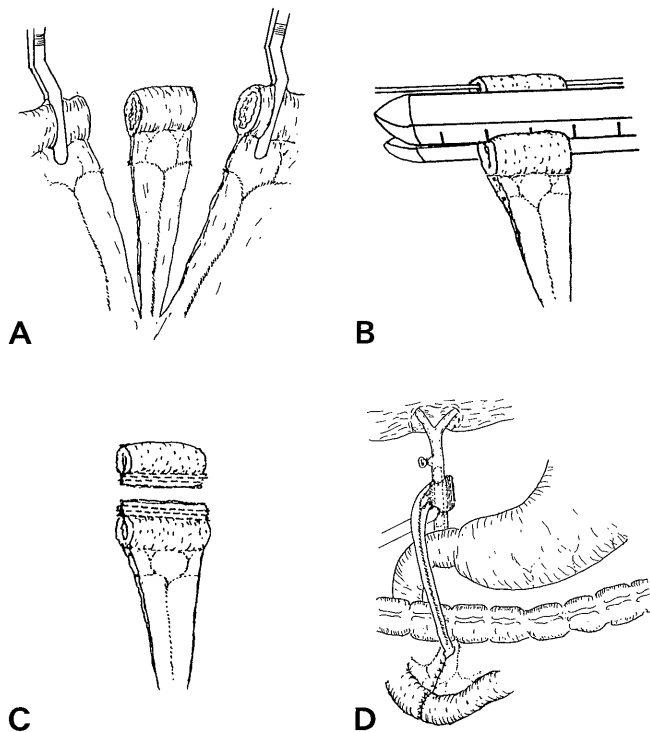


**Figure 1.** Operative technique of common bile duct reconstruction using the appendix group (A-C). The replaced appendix was covered by the greater omentum (D).

In the intestinal segment group, preparations were then made to graft a small intestinal segment across the same length of the resected ducts (Fig 2-A). The small intestinal segment, which was cut on the aboral side of the pedicle with an absorbable autosuture (Poly GIA-75, United States Surgical Co., Norwalk, USA), in order to obtain the same caliber as the extrahepatic bile duct, was then placed longitudinally in the defective portion of the common bile duct (Fig 2-B, C).

The proximal and distal posterior walls of the choledoco- jejunostomy were approximated with 5-0 Dxon II (Absorbable, DAVIS-GECK Co., Wayne, NJ, USA). Once the posterior wall of the anastomosis was sutured, the proximal arm of the T-tube (R-C T type drain, Create Medic Co., Yokohama, Japan) was then inserted unto the proximal choledocus segment. The overlapping grafted portion was resected, and the anterior wall was sewn seromuscularly using a single knot technique with 5-0 Dxon II (Fig 2-D). All T-tubes were removed 30 days after operation.

The animals were sacrificed under complete anesthesia on the 3rd or 12th month after the second operation, respectively.



**Figure 2.** Operative technique of common bile duct reconstruction using the intestinal segment group (A). The small intestinal segment was cut on the aboral side of the pedicle with the absorbable autosuture in order to obtain the same caliber as that for the extrahepatic bile duct (B,C). The proximal arm of the T-tube was inserted into the proximal common bile duct segment (D).

### *Roentgenographic Examination*

Five days after the second operation, fistulography was done in all but three dogs, while superior mesenteric arteriographic examinations were also done three and twelve months after the second operation.

### *Microscope Examination*

At autopsy, the hepatoduodenal ligament was removed en bloc with the liver, pancreas and part of duodenum, and fixed in 10% buffered formalin. The common bile duct with a replaced intestinal segment was cut into 2 or 3 blocks and embedded so that each section contained the hepatic hilus, a common bile duct and replaced intestinal segments. All sections were stained with hematoxylin and eosin (H&E), and Masson trichrome and Weigert's fibrin stains were made to confirm the presence of either fibrosis or cholangitis.

## **Results**

### *Surgical Results*

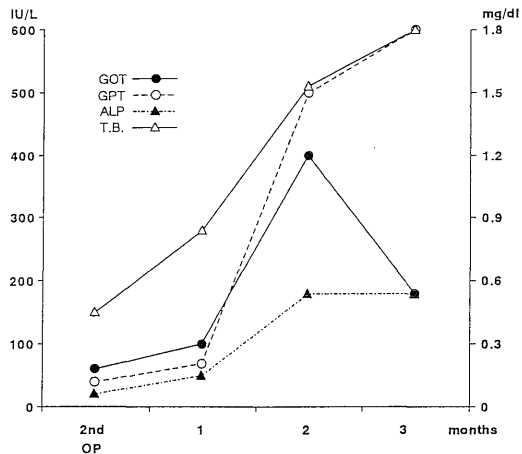
All the dogs tolerated the primary and second operations. The average body weight of the dogs in intestinal group increased one kg compared with that observed at 3 months after the beginning of the experiment. None of the dogs had any postoperative complications, such as infections according to examinations for bile leakage and bowel obstruction. All the dogs in intestinal group survived during the experimental protocol. On the contrary, all the dogs, except one, in appendix group died within 3 months. The cause of death in these dogs was cholangitis, which was probably related to stenotic changes in the anastomotic portion.

### *Laboratory Parameters*

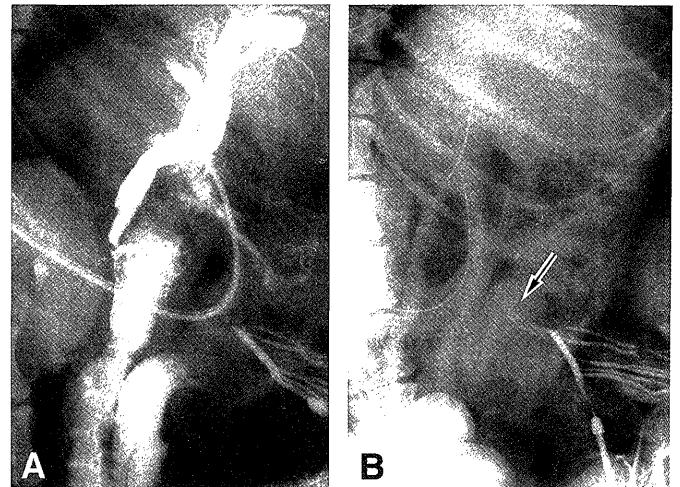
In appendix group, all the laboratory data gradually rose during the observation period (Fig 3). In intestinal group, however, the laboratory data were within the normal limits throughout the experiment (Fig 4).

### *Roentgenographic Findings*

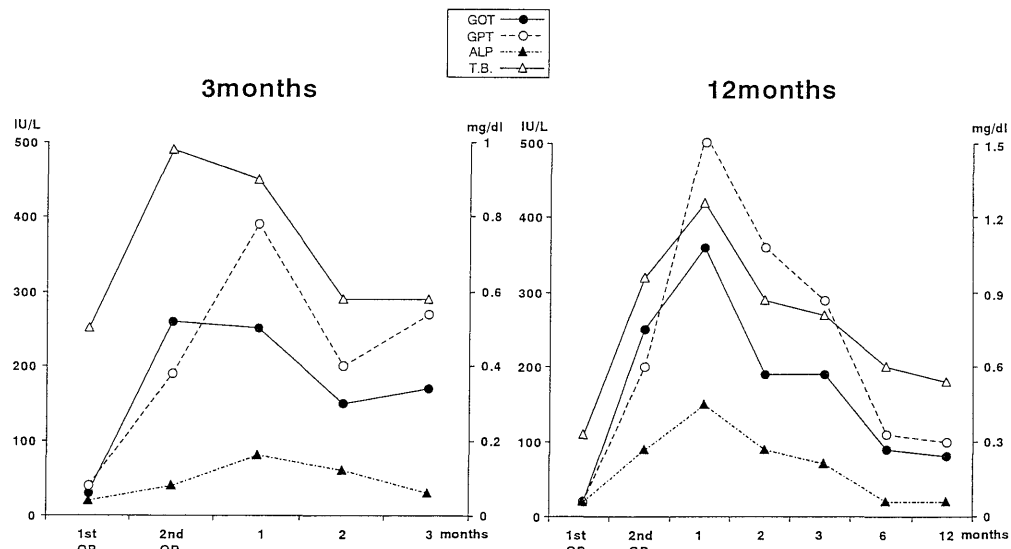
Five days after the second operation, fistulography was done in 6 dogs in intestinal group. None of the dogs showed any evidence of bile leakage, stenosis or dilatation of the common bile duct (Fig 5-A). After 3 or 12 months, roentgenograms of all dogs on the day



**Figure 3.** The laboratory parameters in dogs common bile duct reconstruction using the appendix group. The levels of GOT, GPT, ALP and T.B all gradually rose during the observation period.



**Figure 5.** Cholangiography and superior mesenteric arteriography of a case of common bile duct reconstruction using the intestinal segment group. Cholangiography after 3 months shows no sign of either leakage, stenosis or dilatation (A). Superior mesenteric arteriography, after 3 months shows a scant blood flow (arrow, B).




**Figure 4.** The laboratory parameters of cases of common bile duct reconstruction using the intestinal segment group. The levels of GOT, GPT, ALP and T.B temporarily rose after the cholecystectomy, but afterwards decreased to the normal range.

of sacrifice showed no evidence of stenosis at either the proximal or distal anastomosis. No dilatation of the bile ducts proximal to the graft was observed. On superior mesenteric arteriography 3 months later, blood supply to the graft was minimum (Fig 5-B).

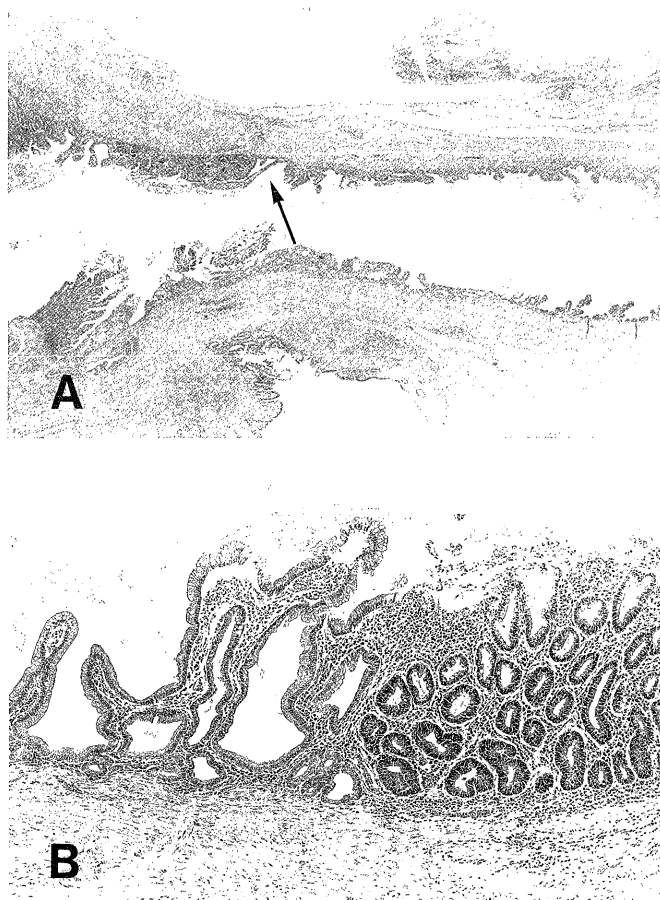
#### Microscopic findings

No bile duct injury, cystic duct deformation similar to Mirizzi syndrome, cystic dilatation of the stump of the cystic duct or biloma was observed. A microscopical

examination of the animals in intestinal group, at 3 and 12 months, respectively, after primary surgery showed the pedicle of the small intestinal segment to have healed without complications. No ulceration of the mucosa was observed (Fig 6). In each dog, there was also a distinct division between the mucosa of the biliary tract and the graft. A clear division was also proven histologically (Fig 7-A, B). There was also no sign of a chronic inflammation or mucosal dysplasia, even in the transition area between the mucosa of the bile duct and the intestinal segment. The findings



**Figure 6.** Macroscopic findings of a case of common bile duct reconstruction using the intestinal segment group. No dilatation of the intrahepatic bile duct and no stenosis of the small intestinal segment were observed.



**Figure 7.** Microscopic findings of a case of common bile duct reconstruction using the intestinal segment group. In this case, at 12 months after surgery, the epithelium of the small intestinal segment was atrophy (Fig 7-A). Allow shows transitional point from the intestinal (right side) to biliary epithelium (left side). Fig 7-B shows high magnification of allow point.

showed a morphologic correlation to the contraction seen on roentgenography. A liver biopsy showed a normal parenchyma in all animals without any signs of cholangitis, cholestasis, or biliary cirrhosis. The region stapled with absorbable sutures changed into dense fibrous tissue 12 months after operation without any inflammatory changes.

## Discussion

Initially, many surgeons in the field believed that end to end bile duct repair of the bile duct or a graft replacement were preferable procedures because it preserved the papilla and ampullary function and therefore minimized cholangitis<sup>14,15</sup>.

A large series with end to end repair of the bile duct reported from the Lahey Clinic<sup>16</sup>, and others<sup>17,18</sup>, however, suggest that end to end repair showed only 40-50% of success rates after long-term follow-up. The high complication rates might be due to inadequate preparations of the extrahepatic bile duct to permit tension free anastomosis. For decades, some surgeons tried to apply suitable prosthetic materials including Teflon vitallium<sup>19</sup> and Goretex<sup>20</sup> to replace an injured segment of the common bile duct, which was unsuccessful because of stenosis or occlusion with debris. Artificial materials without the mucosal epithelium seems to be inadequate for as a bile duct replacement. In the present study, we confirmed that the appendix could not remain viable only by perfusion like a skin graft, even when the graft is very small.

The jejunal pedicle graft has well-preserved blood supply, which lead to prevent occurrence of stenotic change in the graft itself. Thus, the usefulness of the jejunal pedicle graft was reported theoretically<sup>21</sup> and experimentally<sup>12,13</sup>. However, such methods of bile duct replacement are no longer pursued and have not yet been performed because of the high rate of complications due to the debris of the bile duct. Bottger and Junginger<sup>22</sup> also tried to use a small bowel segment for extrahepatic bile duct replacement in pigs, even though in their experiment the common bile duct was dilated. Before absorbable suture materials became available, non-absorbable ones should be applied in such cases. When non-absorbable materials were utilized, however, stenotic changes might occur in the jejunal pedicle because of foreign body reaction by suture materials, which led to induction of cholangitis. In the present study, absorbable autosuture was successfully used to prevent foreign body reaction in the jejunal pedicle graft.

Concerning the blood supply, angiography showed a

weak blood supply to the anastomotic portion from the mesenteric artery, at 3 months after biliary reconstruction. These findings suggest that the blood supply to the bile duct wall was established 3 months after operation. Bile duct like epithelialization of the intestine was more pronounced in the dogs observed for 12 month than those in the 3 month. Giancarlo et al.<sup>23)</sup> created model of choledochoplasty using an autologous vascular graft under microscope surgery. They also showed the epithelialization of venous and arterial grafts. The biliary epithelium may thus colonize the intestine to a greater extent than the endothelial epithelium, and thus resume cell specialization and function as in the normal biliary epithelium, Namely, we might have to wait a certain period of time before removing the stent tube until the intestinal epithelium become like a bile duct epithelium.

Grafting of intestinal segment is a very promising potential alternative to a partial replacement of the extrahepatic biliary duct. Moreover, many other conditions such as extensive biliary tract strictures or choledocal cysts after a resection of adenomas and small carcinomas may thus be indications for this method. Thus, our new approach proved to be useful in selected patients.

## References

1. Rutledge RH: Methods of repair of non circumferential bile duct defects. *Surgery* 93: 333-342, 1983
2. Blumgart LH, Kelley CJ, Benjamin IS: Benign bile duct stricture following cholecystectomy: critical factors in management. *Br. J. Surg* 71: 836-843, 1984
3. Fracosis PG S, Peter MNFHG, Dirk J G: Outcome of 49 repairs of bile duct injuries after laparoscopic cholecystectomy. *World J Surg* 19: 753-757, 1995
4. Mark R B, David B A, Joseph P S, John TC, Management of biliary strictures due to laparoscopic cholecystectomy. *J Surg Res* 58: 86-89, 1995
5. Ricardo LR, Jane IT: Biliary reconstruction. *Surg Clin Nor America* 74: 825-841, 1994
6. J. Michael M, Ronald KT, Michael JZ, William PLJ, Joel JR: Management of bile duct strictures. *Arch Surg* 127: 1077-1084, 1992
7. McDonald ML, Farnell MB, Nagorney DM, Ilstrup DM, Kutch JM: Being biliary strictures: Repair and outcome with a contemporary approach. *Surgery* 118: 582-591, 1995
8. Tajima Y, Eto T, Tsunoda T, et al: Induction of extrahepatic biliary carcinoma by N-Nitrosobis (2-oxopropyl) amine in hamsters given cholestydo- duodenostomy with dissection of the common duct. *Jpn J Cancer Res* 85: 780-788, 1994
9. Nagata E, Saeki K, Kinoshita H: Choledocal cyst: Complication of anomalous connection between the choledocus and pancreatic duct and carcinoma of the biliary tract. *World J Surgery* 10: 102-110, 1986
10. Todani T, Watanabe Y, Toki A: Carcinoma related to choledocal cysts with internal drainage operation. *Surg Gynecol Obstet* 164: 61-64, 1987
11. Ikematsu Y, Tomioka T, Yamanaka S, et al: Bilioenterostomy enhances Biliorycarcinogenesis in hamsters. *Carcinogenesis* 17: 1505-1509, 1996
12. Kibry CK, Fitts WT: Reconstruction of the bile ducts with an isolated segment of jejunum. *Arch Surg* 61: 462-468, 1950
13. Wallensten S, Hormstrom B: Reconstruction of the common duct with an isolated segment of jejunum. *Acta Chir Scand* 117: 316-321, 1959
14. Dunphy JE, Stephens FO: Experiment study of the effect of grsfts in the common duct on biliary and hepatic function. *Ann Surg* 155: 906-914, 1962
15. Madden JL, McCann WJ: Reconstruction of the common bile duct by end-to end anastomosis without the use of an internal splint or stent support. *Surg Gynecol Obstet* 112: 305-314, 1961
16. Warren KW, Mountain JC, Midell AI: Management of strictures of the biliary tract. *Surg Clin Noth Am* 51: 711-731, 1971
17. Genest JF, Nacos E, Grundfest-Broniatowski S, et. Al: Benign biliary strictures: An analytic review (1970 to 1984). *Surgery* 99: 409-413, 1986
18. Brooks DC, Becker JM, Connors PJ, et al: Management of bile leaks following laparoscopic cholecystectomy. *Surg Endosc* 7: 292-295, 1993
19. Thomas JP, Meteoropol HJ, Myers RT: Teflon patch graft reconstruction of the extrahepatic bile ducts. *Ann Surg* 160: 967-970, 1984
20. Mendelowitz DS, Beal JM: Expanded polytetrafluoroethylene in reconstruction of the canine biliary system. *Am J Surg* 143: 221-224, 1982
21. Warren KW, McDonald WM: Facts and fiction regarding strictures of the extrahepatic bile ducts. *Ann Surg* 159: 996-1010, 1964
22. Bottger TC, Junginger T: A small-bowel segment as a total extrahepatic bile duct replacement. *Arch Surg* 127: 1424-1427, 1992
23. Flati G, Flati D, Porowska B, Rossi G, Francavilla S, Santoro E, Carboni M: Circumferential choledochoplasty with autologous venous and arterial grafts *Microsurgery* 14: 628-633, 1993