

Cognitive Dysfunction, MRI Findings and Manganese Levels in Alcoholics

Tsutomu ITOH¹⁾, Katsurou TAKAHASHI²⁾, Masaki SHIMANAGA²⁾, Yoshibumi NAKANE¹⁾

1) Division of Neuropsychiatry, Department of Neurosensory Medicine, Nagasaki University School of Medicine

2) Department of Psychiatry, National Nagasaki Medical Center

Alcoholic patients have been known to have brain atrophy and cognitive dysfunction. However, recent studies have reported bilateral signal hyperintensities of the globus pallidus on T1-weighted magnetic resonance imaging (MRI) in liver failure, findings that are typically associated with manganese intoxication. The present study compared brain atrophy on T1-weighted MRI, signal intensity ratios of the globus pallidus on T1-weighted MRI, whole blood manganese levels, and Wechsler Adult Intelligence Scale-Revised (WAIS-R) IQ parameters between alcoholics with and without liver cirrhosis, to investigate cognitive dysfunction, MRI findings and manganese levels in alcoholics.

Pallidal hyperintensity was visually identified in 80% of alcoholic patients with liver cirrhosis. In addition, a significant correlation was seen between pallidal signal intensity (P.S.I.) ratio and blood manganese level. However, no significant correlations were found between pallidal signal intensity ratio and any of the WAIS-R parameters. These findings suggest that no direct connection exists between cognitive dysfunction and pallidal hyperintensity in alcoholic patients with liver cirrhosis. We confirmed that brain MRI in alcoholics could detect pallidal signal hyperintensity, suggesting severe liver dysfunction. In addition to diagnosis, brain MRI is useful for therapeutic psychoeducation to alcoholic patients with liver cirrhosis, visualizing the severe liver dysfunction.

ACTA MEDICA NAGASAKIENSIA 47 : 149–154, 2002

Key Words: alcoholism, liver cirrhosis, magnetic resonance imaging, manganese, cognitive dysfunction, Wechsler Adult Intelligence Scale-Revised (WAIS-R)

Address Correspondence: Tsutomu Itoh, M.D.

Division of Neuropsychiatry, Department of Neurosensory Medicine, Nagasaki University School of Medicine, 1-7-1 Sakamoto, Nagasaki 852-8501, Japan

TEL: +81-95-849-7293 FAX: +81-95-849-7296

Introduction

Alcoholic patients have been known to have brain atrophy and cognitive dysfunction. These conditions can result not only from alcohol, but also from malnutrition, electrolyte abnormality or liver dysfunction. As far as imaging of the brain in patients with liver failure is concerned, brain computed tomography (CT) in patients with non-alcoholic cirrhosis has revealed atrophy of the brain, predominantly the cerebral cortex. This atrophy has been attributed to the effects of toxins such as ammonia, suggesting that brain atrophy in patients with alcoholic cirrhosis may also result from the effects of such toxins, in addition to the effects of alcohol¹⁾. However, recent studies have reported bilateral signal hyperintensities of the globus pallidus on T1-weighted magnetic resonance imaging (MRI) in liver failure, findings that are typically associated with manganese intoxication²⁾. Regarding cognitive dysfunction in liver failure, a study using the Wechsler Adult Intelligence Scale (WAIS) confirmed that cirrhotic alcoholics demonstrated lower cognitive function than non-cirrhotic alcoholics³⁾.

The present study compared brain atrophy on T1-weighted MRI, signal intensity ratios of the globus pallidus on T1-weighted MRI, whole blood manganese levels, and WAIS-R IQ parameters between alcoholics with and without liver cirrhosis, to investigate cognitive dysfunction, MRI findings and manganese levels in alcoholics.

Subjects and Methods

Subjects were alcoholics who visited the National Nagasaki Medical Center between February 1999 and April 2001, received explanation of the details of the present study and provided consent to participate. ICD-10 guidelines for dependence syndromes were used to diagnose alcoholism⁴⁾. In addition, liver cirrhosis was diagnosed on the basis of blood chemistry,

diagnostic imaging and laparoscopy by collaborators specializing in internal medicine. The LC group comprised alcoholics with liver cirrhosis (n=10), and the non-LC group comprised alcoholics without liver cirrhosis (n=10).

MRI was performed using a RESONA Vectra (Yokogawa) with field strength of 0.5 T to capture transaxial and sagittal T1-weighted scans (TR/TE=300 ms/16 ms) and transaxial and coronal T2-weighted scans (TR/TE=3700 ms/110 ms) using the spin echo sequences. Matrix size was 192×256, and slice width was 7 mm. A 21 mm² region of interest (ROI) was established by a collaborator, who was not informed of clinical symptoms or test results, in the globus pallidus and putamen on each T1-weighted scan, excluding infarct areas. Since the T1 relaxation time of the globus pallidus depends on imaging conditions, absolute values are difficult to assess. As a result, pallidal signal intensity (P.S.I.) ratios were calculated based on the formula of Geis et al (globus pallidus signal - putamen signal/globus pallidus signal + putamen signal)⁵, and left and right values were averaged. Brain atrophy was assessed in terms of increased ventricle, by calculating ventricle index (width of the choroid plexuses/maximum width of the frontal horns at the same level)⁶ and third ventricle width. In addition, severity of cortical atrophy was assessed by measuring maximum width of the margin of the cingulate sulcus on each paramedian sagittal scan. Whole blood manganese assays were performed by Kitasato Biochemical Laboratories using atomic absorption spectroscopy and were verified by repeat analysis. All blood samples were collected in an identical fashion and no clinical information was provided to the laboratory. Furthermore, WAIS-R was carried out by a clinical psychologist who was not informed of the results of brain MRI or liver function tests, to ascertain IQ scores of all patients. For statistical analyses, a t-test was used to compare results between the two study groups, and Pearson's correlation coefficients were used to assess correlations between two variables.

Results

1. Patient backgrounds

All patients were males. The LC group displayed a mean age of 58.0±10.32 years (range: 43-74 years) and the non-LC group displayed a mean age of 59.3±11.93 years (range: 46-77 years). No significant difference in mean age was observed between the two

groups (p=0.797). In addition, the mean levels of education for the LC and non-LC groups were 10.7±3.16 and 10.4±2.01 years, respectively, again with no significant difference existing between the two groups (p=0.803).

2. Whole blood manganese levels

Mean whole blood manganese levels for the LC and non-LC groups were 2.88±1.266 and 1.37±0.320 mg/dl, respectively, representing a significant difference between the two groups (p<0.02) (Table 1).

Table 1. Whole blood manganese(Mn) level and MRI parameters of the studied patients.

	Case	Age	Mn (μg/dl)	P.S.I. Ratio	III VW (mm)	Ventricle index	WS (mm)
Cirrhotic. (LC)	1	51	5.1	0.134	7.2	1.798	6.6
	2	73	2.2	0.020	8.8	1.676	2.8
	3	43	1.3	0.047	8.8	1.786	3.5
	4	55	4.4	0.125	9.1	1.709	7.5
	5	64	2.4	0.089	7.5	1.658	6.8
	6	54	3.2	0.126	10.0	1.991	6.6
	7	74	1.5	0.064	10.6	1.714	4.4
	8	53	1.9	0.055	9.7	1.729	5.6
	9	49	3.9	0.103	7.5	2.060	4.0
	10	64	2.9	0.077	12.2	1.675	6.0
	means.	58.0	2.88	0.084	9.14	1.780	5.38
	SD	±10.32	±1.266	±0.0381	±1.561	±0.1382	±1.598
Non-Cirrhotic (non-LC)	11	46	1.4	0.027	7.5	1.586	2.5
	12	57	1.9	0.038	6.9	1.692	6.3
	13	63	1.1	0.042	10.6	1.708	3.3
	14	52	1.2	0.039	6.3	1.892	5.0
	15	76	1.3	0.048	10.6	1.719	3.5
	16	50	1.0	0.016	10.0	1.400	4.5
	17	53	1.8	0.008	10.6	1.634	5.8
	18	77	1.2	0.019	6.3	1.685	5.8
	19	47	1.1	0.014	8.4	1.776	2.0
	20	72	1.7	0.028	8.8	1.808	5.8
	means.	59.3	1.37	0.028	8.60	1.690	4.45
	SD	±11.93	±0.320	±0.0135	±1.786	±0.1339	±1.536

P.S.I.ratio:Pallidal signal intensity ratio

III VW:Third ventricle width. Ventricle index(normal:>1.6;slight dilatation:1.4-1.6; moderate dilatation:1.0-1.3;marked dilatation:<1.0)

WS:Width of sulci(normal:<5mm;increased:>5mm)

3. Pallidal signal intensity ratios on brain T1-weighted MRI scans

In 8 of the 10 LC patients, brain T1-weighted MRI revealed bilateral signal hyperintensities in the globus pallidus, but corresponding T2-weighted images for these patients were normal (Figure 1). No abnormal signals were observed in the non-LC group. Mean pallidal signal intensity (P.S.I.) ratios for the LC and

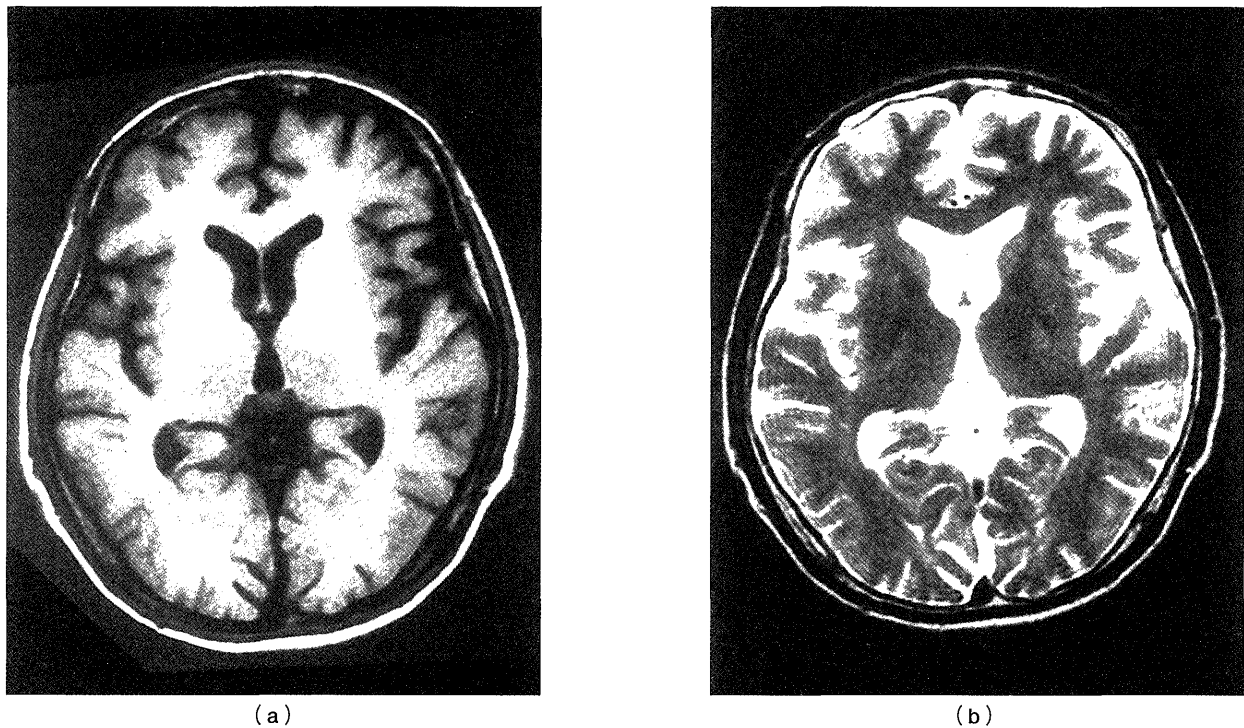


Figure 1. T1-weighted MRI of a cirrhotic patient revealed bilateral signal hyperintensity in the globus pallidus(a), but corresponding T2-weighted image for same patient was normal (b).

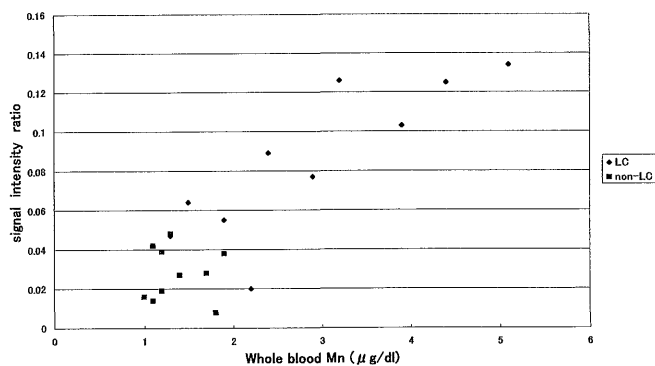


Figure 2. Whole blood manganese(Mn) levels and pallidal signal intensity ratio ($r=0.869, p<0.005$).

non-LC groups were 0.084 ± 0.0381 and 0.028 ± 0.0135 , respectively, and a significant difference was observed between the two groups ($p<0.01$). In addition, a significant correlation was identified between blood manganese level and pallidal signal intensity ratio ($r=0.869, p<0.005$) (Figure 2).

4. Brain atrophy assessment using MRI

No significant difference in third ventricle width (central atrophy) was observed between the LC and non-LC groups, with mean widths of 9.14 ± 1.561 and 8.60 ± 1.786 mm ($p=0.481$), respectively. A width of 8 mm has been reported as normal for the third ventricle⁶⁾,

so mild enlargement was present in both groups. In addition, normal ventricle index is reportedly $1.6^{6)}$, and mean ventricle indexes for the LC and non-LC groups were higher at 1.780 ± 0.1382 and 1.690 ± 0.1339 , respectively, but no significant difference was observed between the two groups ($p=0.158$). The mean widths of the sulcus (cortical atrophy) for the LC and non-LC groups were 5.38 ± 1.598 and 4.45 ± 1.536 respectively, with no significant difference observed between the two groups ($p=0.201$). However, mean width for the LC group was slightly greater than the reported normal width of less than 5 mm⁶⁾ (Table 1). No significant correlations were observed between age and either third ventricle width ($r=0.1991, p>0.25$), ventricle index ($r=-0.1317, p>0.5$), or sulcus width ($r=0.0948, p>0.5$).

5. Subtest scores and Full IQ (FIQ) as assessed by WAIS-R

Mean FIQs for the LC and non-LC groups were 80.5 ± 16.64 and 80.8 ± 12.65 , respectively, revealing no significant difference ($p>0.5$). Mean Verbal IQs (VIQs) for the LC and non-LC groups were 87.6 ± 16.74 and 87.2 ± 13.16 , respectively, again demonstrating no significant difference. Mean Performance IQs (PIQs) for the LC and non-LC groups were 75.5 ± 14.70 and 76.2 ± 11.88 , respectively, demonstrating no significant difference. Mean FIQ for the LC and non-LC groups were

Table 2. Means and standard deviations for summary IQ scores.

IQ score	Cirrhotic mean±SD	Non-Cirrhotic mean±SD	Ttest
Verbal	87.6±16.74	87.2±13.16	n.s.(p>0.5)
Performance.	75.5±14.70	76.2±11.88	n.s.(p>0.5)
Full Scale	80.5±16.64	80.8±12.65	n.s.(p>0.5)

Table 3. Means and standard deviations of WAIS-R subtest scores.

Subtest	Cirrhotic means±SD	Non-Cirrhotic means±SD	Ttest
Informaion	8.9±3.67	8.6±2.99	n.s.(p=0.843)
Digit span	7.8±2.94	8.5±3.34	n.s.(p=0.625)
Vocabulary	8.1±3.31	8.3±2.75	n.s.(p=0.885)
Arithmetic.	7.1±1.66	6.8±1.03	n.s.(p=0.635)
Comprehension	8.2±3.12	9.0±3.68	n.s.(p=0.607)
Similarities.	8.1±4.04	6.7±3.40	n.s.(p=0.413)
Picture completion	8.3±2.50	7.5±3.92	n.s.(p=0.594)
Picture arrangement	6.2±3.26	7.2±1.62	n.s.(p=0.400)
Block design.	6.3±3.06	5.9±2.33	n.s.(p=0.746)
Object assembly.	5.1±3.00	5.5±2.59	n.s.(p=0.753)
Digit symbol	5.6±2.50	5.5±2.80	n.s.(p=0.934)

Table 4. No significant correrations existed between any of the three IQ parameters and any of the MRI findings.

	P.S.I.ratio	III VW(mm)	ventricle index	WS(mm)
FIQ	r=-0.131,p>0.50	r=0.137,p>0.50	r=0.012,p>0.50	r=-0.272,p>0.10
VIQ	r=-0.118,p>0.50	r=0.197,p>0.25	r=0.130,p>0.50	r=-0.262,p>0.25
PIQ	r=-0.126,p>0.50	r=0.069,p>0.50	r=-0.120,p>0.50	r=-0.282,p>0.10

80.5±16.64 and 80.8±12.65, respectively, demonstrating no significant difference (p>0.5) (Table 2). In addition, no significant differences in any of the subtest scores were observed between the two groups (Table 3). Furthermore, no significant correlation was found between pallidal signal intensity ratio and any of the IQ parameters: FIQ (r=-0.131, p>0.5), VIQ (r=-0.118, p>0.5) and PIQ (r=-0.126, p>0.5). Moreover, as shown in Table 4, no significant correlations existed between any of the three IQ parameters (FIQ, VIQ and PIQ) and any of the MRI findings (third ventricle width, ventricle index or sulcus width).

Discussion

Alcoholic patients have been known to have brain atrophy and cognitive dysfunction. Pfefferbaum et al performed MRI on alcoholics and found that severity

of cortical atrophy was dependent on length of alcohol abuse and amount of alcohol consumption⁷⁾. Kishimoto documented a significant correlation between alcohol consumption and enlarged lateral and third ventricles, suggesting the effects of alcohol on brain⁸⁾. Conversely, Victor et al did not observe any specific neuropathological findings in the cerebral cortex of alcoholics, and concluded that brain atrophy in alcoholics was not caused by alcohol, but rather by factors such as malnutrition⁹⁾. Akai et al emphasized the importance of the correlation between alcoholic encephalopathy and physical disorders, particularly liver dysfunction¹⁰⁾. Zeneroli et al found that atrophy of the brain, predominantly the cerebral cortex, was observed significantly in patients with non-alcoholic cirrhosis, suggesting that brain atrophy is caused by exposure to not only alcohol, but also other toxins such as ammonia¹⁾. In the present study, mean sulcus width for the LC group was slightly greater than the published norm of 5 mm, but no significant difference was observed between LC and non-LC groups. Similarly, mean third ventricle width and ventricle index for the LC group slightly exceeded the published norms, but no significant differences were observed between the two groups. Consequently, we did not observe any significant differences in the severity of brain atrophy between alcoholics with and without liver cirrhosis. This issue warrants further investigation in a larger subject population.

Brain T1-weighted MRI on patients with liver cirrhosis reveals bilaterally symmetrical signal hyperintensities in the globus pallidus^{11) 12)} in 56-75% of cases¹³⁾. In the present study, pallidal hyperintensity was visually confirmed in 8 of the 10 alcoholics with liver cirrhosis, but in none of the 10 alcoholics without liver cirrhosis. Hence, the visual detection rate of pallidal hyperintensity for the LC group (80%) was higher when compared to published reports. The detection rate of pallidal hyperintensity in alcoholic cirrhosis should be comparable or higher than that in liver cirrhosis caused by other factors. In addition, a significant difference in mean globus pallidus-putamen signal intensity ratio was observed between LC and non-LC groups, empirically confirming a significantly higher incidence of pallidal hyperintensity for alcoholic patients with liver cirrhosis. Numerous studies have investigated the causes and clinical significance of pallidal hyperintensity. Kulisevsky et al confirmed a strong correlation between pallidal hyperintensity and plasma ammonia level, and concluded that pallidal hyperintensity resulted from high ammonia concentrations in the brain¹⁴⁾. Pujol et al reported a significant correlation between pallidal hyperintensity

and factors such as prothrombin time, ICG clearance and past episodes of variceal bleeding¹⁵). Iwasa et al confirmed a significant correlation between pallidal signal intensity ratio and parameters such as serum albumin level, cholinesterase level, prothrombin level, ICG-R15, ammonia level and Fischer ratio in liver cirrhosis patients without a past history of hepatic encephalopathy¹³.

Since the pallidal hyperintensity associated with alcoholism closely resembles the MRI findings associated with manganese intoxication², the relationship between pallidal hyperintensity and manganese has been investigated. Manganese is a paramagnetic metal that exerts a potent T1-reducing effect, and manganese accumulation is seen as a high signal intensity area on T1-weighted scans in a dose-dependent manner¹⁶. In the brain, the affinity of manganese is particularly high in the globus pallidus¹⁷. When ingested orally, 1-3.5% of ingested manganese is absorbed through the blood, while about 98% is metabolized in the liver and excreted in bile¹⁸. However, when manganese is ingested parenterally¹⁹ or when a portosystemic bypass is present²⁰, manganese enters the systemic circulation without passing through the liver, allowing it to accumulate in the globus pallidus, reflected as a signal hyperintensity on MRI. Krieger et al reported that blood manganese levels for patients with liver cirrhosis were significantly higher than those for healthy individuals, and demonstrated a significant correlation between pallidal hyperintensity and blood manganese level²¹. In the present study, mean blood manganese level was significantly higher for the LC group than for the non-LC group, and a significant correlation was observed between blood manganese level and globus pallidus/putamen signal intensity ratio, confirming the results obtained by Krieger et al. Regarding the histopathological findings associated with the brains of patients with chronic manganese intoxication, findings such as atrophy and wasting of nerve cells, increased glial cells, and increased glial fibers, have been documented in the globus pallidus²². It has been generally accepted that type II Alzheimer cells appear in the globus pallidus and putamen of patients with hepatic encephalopathy²³. Ihara documented marked atrophy and wasting of nerve cells and increased glial cells in the globus pallidus of patients with liver cirrhosis, and stated that the histopathological findings in the brains of liver cirrhosis patients resembled those in chronic manganese intoxication patients²⁴. In addition, one study observed that levels of pallidal manganese were high in post-mortem brains of patients with liver cirrhosis²⁵. The fact that the present study confirmed a correlation

between pallidal signal intensity ratio and whole blood manganese level suggests that due to hepatic dysfunction, manganese was not metabolized in the liver and excreted. This caused an increase in levels of manganese in the systemic circulation, and manganese deposition in the globus pallidus subsequently rose in a dose-dependent manner. Increased manganese levels resulted in brain alterations, seen as signal hyperintensities on T1-weighted MRI. The neuropsychiatric symptoms associated with chronic manganese intoxication include apathy, agitation, insomnia and extrapyramidal signs²⁶, while those associated with hepatic encephalopathy include mild disturbance of consciousness, agitation, emotional instability and apathy. Although there are similarities between chronic manganese intoxication and hepatic encephalopathy, the relationships between pallidal hyperintensity and conditions such as cognitive dysfunction and neuropsychiatric symptoms have yet to be fully clarified. Brunberg et al found no correlation between MRI findings and hepatic encephalopathy¹¹. Krieger et al reported no correlation between pallidal hyperintensity and brain or subcortical motor function²⁷. However, some studies have found that pallidal hyperintensity correlated to the presence or severity of hepatic encephalopathy^{13, 15}.

Harold et al used WAIS to assess cognitive function in alcoholic patients with and without liver cirrhosis, and reported that cognitive function of the alcoholics with liver cirrhosis was lower³. According to their report, the VIQ, PIQ and FIQ for alcoholic patients with liver cirrhosis were significantly lower than scores for alcoholics without liver cirrhosis, and although no significant differences were observed in information and vocabulary scores, significant differences were found in other subtest scores, suggesting a close relationship between hepatic and cognitive functions in alcoholic patients. Since we thought that pallidal hyperintensity was involved in the difference in cognitive functions between these two groups of patients as reported by Harold et al, we decided to investigate this relationship in the present study. However, no significant differences in VIQ, FIQ, PIQ and the various subtest scores, as assessed by WAIS-R, were observed between alcoholic patients with and without liver cirrhosis. In addition, pallidal signal intensity ratios did not correlate to any of the WAIS-R parameters (VIQ, PIQ, FIQ and the various subtest scores). These findings suggest that no direct connection exists between cognitive dysfunction and pallidal hyperintensity in alcoholic patients with liver cirrhosis.

Conclusions

Pallidal hyperintensity was visually identified in 80% of alcoholic patients with liver cirrhosis. The detection rate of pallidal hyperintensity in alcoholic cirrhosis should be not less than that in non-alcoholic cirrhosis. A significant difference in globus pallidus / putamen signal intensity ratio was observed between the LC and non-LC groups, empirically confirming the higher incidence of pallidal hyperintensity in the LC group. In addition, a significant correlation was seen between pallidal signal intensity ratio and blood manganese level. When WAIS-R was used to compare cognitive function in alcoholics with and without liver cirrhosis, no significant differences were observed in VIQ, PIQ, FIQ and the various subtest scores. Furthermore, no significant correlations were found between pallidal signal intensity ratio and any of the WAIS-R parameters (VIQ, PIQ, FIQ and the various subtest scores). These findings suggest that no direct connection exists between cognitive dysfunction and pallidal hyperintensity in alcoholic patients with liver cirrhosis. We confirmed that brain MRI in alcoholics could detect not only brain atrophy, but also pallidal signal hyperintensity, suggesting severe liver dysfunction. In addition to diagnosis, brain MRI is useful for therapeutic psychoeducation to alcoholic patients with liver cirrhosis, visualizing the severe liver dysfunction.

Acknowledgement

We would like to express our deepest gratitude to the radiologists and internists at the National Nagasaki Medical Center for their invaluable assistance in conducting the present study.

References

- Zeneroli MN, Cioni G, Vezzelli C, et al: Prevalence of brain atrophy in liver cirrhosis patients with chronic persistent encephalopathy: Evaluation by computed tomography. *J Hepatology* 4:283-292,1987
- Nelson K, Golnick J, Korn T, et al: Manganese encephalopathy: Utility of early magnetic resonance imaging. *Br J Ind Med* 50:510-513,1993
- Harold H, Smith J, Sikorski L, et al: WAIS functioning of cirrhotic and non-cirrhotic alcoholics. *J Clin Psychology* 33:309-313,1977
- World Health Organization: The ICD-10 Classification of Mental and Behavioural Disorders: Clinical Descriptions and Diagnostic Guidelines. WHO Geneva, 1992
- Geis RJ, Hendrick RE, Lee S, et al: White matter lesions: Role of spin density in MR imaging. *Radiology* 170:863-868,1989
- Meese W, Lanksch W, Wende S. Cerebral atrophy and computerized tomography: Aspect of a qualitative and quantitative analysis. In *Cranial Computerized Tomography* (Springer-Verlag, Berlin, Heidelberg, New York) pp.222,1976
- Pfefferbaum A, Sullivan EV, Rosenbloom MJ, et al: A controlled study of cortical gray matter and ventricular changes in alcoholic men over a 5-year interval. *Arch Gen Psychiatry* 55:905-912,1998
- Kishimoto H: Brain imaging in alcoholism. *Japan J Clin Psychiatry* 29:715-719,2000
- Victor M, Adams RD, Collins EH. The Wernicke-Korsakoff syndrome and related neurologic disorders due to alcoholism and malnutrition, 2nd ed. FA Davis,1989
- Akai J: Neuropathological aspects on alcoholism. *Japan J Clin Psychiatry* 29:731-735,2000
- Brunberg J, Kanal E, Hirsch W, et al: Chronic acquired hepatic failure: MR imaging of the brain at 1.5T. *AJR* 157:1111-1116,1991
- Zeneroli ML, Cioni G, Crisi G, et al: Globus pallidus alterations and brain atrophy in liver cirrhosis patients with encephalopathy: An MR imaging study. *Magnet Res Imaging* 9:295-302,1991
- Iwasa M, Kawamura N, Hiranuma K, et al: Clinical significance of the globus pallidus signal intensity ratio in patients with liver cirrhosis. *Acta Hepatologica Japonica* 37:626-631,1996
- Kulisevskiy J, Pujol J, Balanzo J, et al: Pallidal hyperintensity on magnetic resonance imaging in cirrhotic patients: Clinical correlations. *Hepatology* 16:1382-1388,1992
- Pujol A, Pujol J, Graus F, et al: Hyperintense globus pallidus on T1-weighted MRI in cirrhotic patients is associated with severity of liver failure. *Neurology* 43:65-69,1993
- Kang YS, Gore JC: Studies of tissue NMR relaxation enhancement by manganese: Dose and time dependences. *Invest Radiol* 19:399-407,1984
- Newland MC, Ceckler TL, Kordower JH, et al: Visualizing manganese in the primate basal ganglia with magnetic resonance imaging. *Exp Neurol* 106:251-258,1989
- Larsen NA, Pakkenberg H, Damsgaard E, et al: Topographical distribution of arsenic, manganese and selenium in the normal human brain. *J Neurol Sci* 42:407-416 1979
- Mirowitz SA, Westrich TJ, Hirsh JD: Hyperintense basal ganglia on T1-weighted MR imaging in patients receiving parenteral nutrition. *Radiology* 181:117-120,1991
- Maeda H, Sato M, Yoshikawa A, et al: Brain MR imaging in patients with hepatic cirrhosis: Relationship between high intensity signal in basal ganglia on T1-weighted images and elemental concentration in brain. *Neuroradiology* 39:546-550,1997
- Krieger D, Krieger S, Jansen O, et al: Manganese and chronic hepatic encephalopathy. *Lancet* 346:270-274,1995
- Yamada M, Ohno S, Okayasu I, et al: Chronic manganese poisoning: A neuropathological study with determination of manganese distribution in the brain. *Acta Neuropathol* 70:273-278,1986
- Butterworth RF: Portal-sytemic encephalopathy: a disorder of neuronastrocytic metabolic trafficking. *Dev Neurosci* 15:313-319, 1993
- Ihara H: High signal intensity of globus pallidus on T1-weighted MRI in liver cirrhosis patients: clinical and pathological study. *Nippon Acta Radiologica* 58:479-488,1998
- Layrargues GP, Shapcott D, Spahr L, et al: Accumulation of manganese and copper in pallidum of cirrhotic patients: Role in the pathogenesis of hepatic encephalopathy? *Metab Brain Dis* 10:353-356,1995
- Haung CC, Chu NS, Lu CS, et al: Chronic manganese intoxication. *Arch Neurol* 461:1104-1106,1989
- Krieger S, Jauss M, Jansen O, et al: Neuropsychiatric profile and hyperintense globus pallidus on T1-weighted magnetic resonance images in liver cirrhosis. *Gastroenterology* 111:147-155,1996