

## Case Report

# Magnetic Resonance Imaging of Kernohan's Notch in Chronic Subdural Hematoma: Significance of Coronal Images for Preoperative Diagnosis

Yasuyuki EZAKI, Keisuke TSUTSUMI, Ken HIU, Tamotsu TOBA, Hiroaki YOKOYAMA

Department of Neurosurgery, Nagasaki Rosai Hospital

A 67-year-old man presented with headache and gait disturbance. On admission, he was mildly confused but aroused by verbal stimulus, with normal motor function. A CT scan showed bilateral subdural hematomas (right >> left) and a midline shift to the left. One hour after admission, he suddenly became somnolent and developed right hemiparesis. While repeated CT examinations failed to reveal new findings, coronal MRI clearly depicted the left cerebral peduncle pressed against the free edge of the tentorium. Craniotomy was immediately performed to remove the right chronic subdural hematoma. Soon after the operation, neurological functions were markedly improved. When paradoxical (ipsilateral to the lesion) motor deficit is observed in patients with head injuries, including cases of chronic subdural hematomas, coronal MR imaging and magnetic resonance angiography should be immediately performed to detect Kernohan's notch and to rule out other possible complications, such as diffuse axonal injury or cerebral stroke.

ACTA MEDICA NAGASAKIENSIA 47 : 57–59, 2002

**Key Words:** Kernohan's notch, chronic subdural hematoma, magnetic resonance image

## Introduction

Due to a supratentorial mass, the contralateral cerebral peduncle is occasionally pressed against the free edge of the tentorium, resulting in paradoxical (ipsilateral to the lesion) hemiparesis<sup>7)</sup>. While this phenomenon is well known as Kernohan's notch (KN), few radiological examinations have been reported<sup>1), 4)-6), 9), 10), 12), 14)-16)</sup>. Preoperative conventional magnetic resonance imaging (MRI) studies are particularly difficult to perform, because KN is

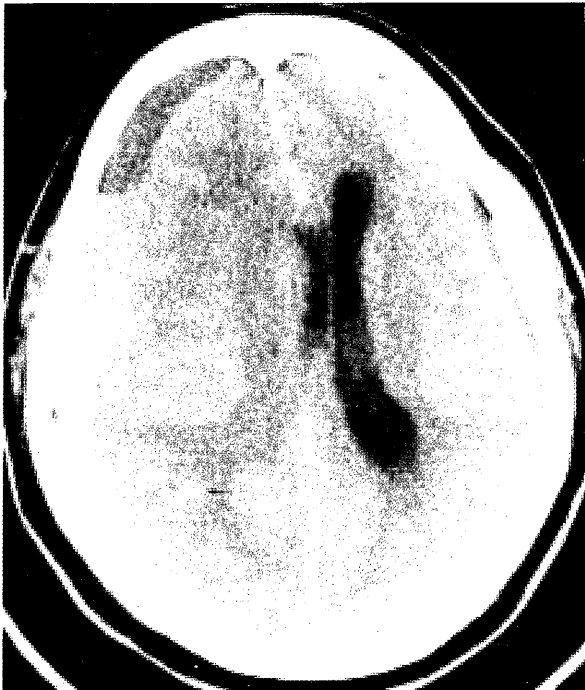
usually only seen in emergency cases with severe head injury, such as large acute epidural hematomas (AEDH) or acute subdural hematomas (ASDH). KN is relatively rare to observe in cases of chronic subdural hematomas (CSDH)<sup>3), 4), 15)</sup>. In this study, we report on an unusual case of KN secondary to bilateral CSDH, distinctly identified by preoperative coronal MRI.

## Case report

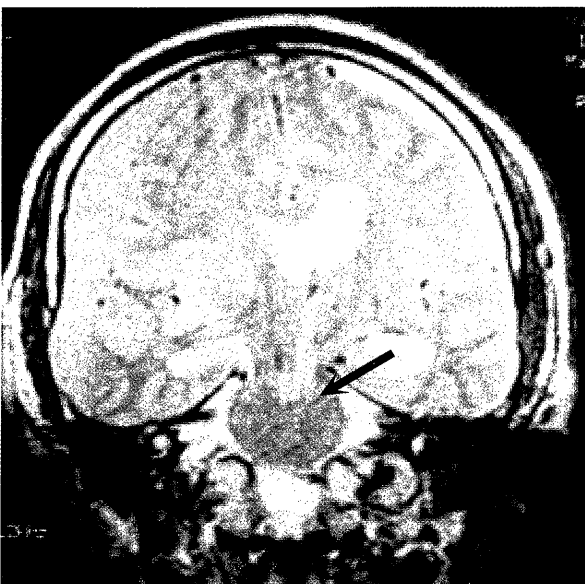
A 67-year-old man was admitted to our hospital on 31 May 2000, with headache and difficulty of walking. On admission, the patient was mildly confused, rating a Glasgow Coma Scale (GCS) of 14/15 (E3V5M6). Pupils were isocoric and no definite hemiparesis was evident. The initial CT scan revealed bilateral subdural hematoma with a 10-mm-shift of the septum pellucidum to the left. The right hematoma was 15-mm-thick and appeared as a two-layer pattern of subdural collection (figure 1 A). The patient was hospitalized the same day for surgery. One hour after admission, the patient suddenly developed drowsiness with a GCS of 8/15 (E2V1M5) and right (ipsilateral to the lesion) hemiparesis. Pupils became slightly anisocoric (right > left). Repeated CT studies failed to determine any new findings. Therefore, we postulated that Kernohan's notch might play a role in this paradoxical motor deficit. To confirm this hypothesis and to exclude the possibility of cerebral ischemia, MRI and MRA studies were immediately performed. Coronal MRI clearly demonstrated the left cerebral peduncle pressed against the free edge of the tentorium (figure 1 B). The signal patterns observed suggested the recurrence of hemorrhaging in the subdural hematomas. No significant ischemic lesions were observed in MR studies, including diffusion-weighted images and MRA. Directly after MR studies, a craniotomy was performed to remove the right subdural hematoma, which was a typical chronic hematoma with outer and inner membranes. Following surgery,

**Address Correspondence:** Yasuyuki Ezaki, M.D.  
Department of Neurosurgery, Nagasaki University School of Medicine, 1-7-1 Sakamoto, Nagasaki 852-8501, Japan  
TEL: +81-95-849-7375, FAX: +81-95-849-7378  
E-mail: ezaki@mars.dti.ne.jp

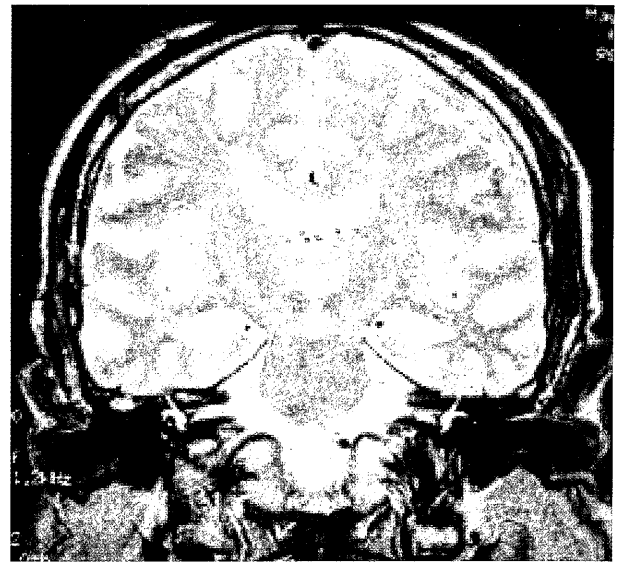
neurological functions improved considerably, and after 25 days the patient was discharged with no significant motor deficit. A postoperative MRI examination revealed marked improvement in the deformity of the left cerebral peduncle (figure 1 C).



**Figure 1 A.** CT scans on admission, shows a large subdural hematoma in the right frontotemporoparietal area with a midline shift to the left. A small subdural hematoma is also observed on the left.



**Figure 1 B.** A T2-weighted coronal MR image 1 hour after admission, clearly shows the compressed lateral part of the left brain stem by tentorial edge (arrow).



**Figure 1 C.** Three months after surgery coronal T2WI reveals improvement in the deformity of the left cerebral peduncle and no T2-elongated lesion in the left brainstem.

## Discussion

Kernohan's notch (KN) has been well known as a possible cause of paradoxical (ipsilateral to the lesion) motor deficits usually seen in patients with severe head injury. Few MRI studies of these lesions have been reported<sup>1), 4)-6), 9), 10), 12), 15), 16)</sup>, probably due to the serious condition of the patients and rapid deterioration of the clinical course. We were able to find ten reports of KN demonstrated by MR imaging (Table 1)<sup>1), 4)-6), 9), 10), 12), 15), 16)</sup>, including two cases of CSDH<sup>4), 15)</sup>. In most cases, postoperative axial images revealed T2 elongated lesions in the contralateral cerebral peduncle. Itoyama et al<sup>4)</sup>, described a deformity of the cerebral peduncle in preoperative T1-weighted axial MR images. In the present case, however, axial images would not have provided sufficient diagnostic information. While several reports<sup>5), 6), 15)</sup> emphasized the significance of coronal MR images for detecting KN, their imaging data were postoperative,

**Table 1.** Summary of MRI findings in reported cases of Kernohan's notch

Author	Sex/Age	Diagnosis	MR Images
1990 Cohen	M/19	AEDH	T2 hyperintensity
1991 Jones	M/25	ASDH	T1 hypointensity, T2 hyperintensity
1992 Iwama	M/39	ASDH	T1 hypointensity, T2 hyperintensity
1995 Itoyama	M/69	CSDH	deformity of the crus cerebri
1997 Yamasaki	M/43	CSDH	T2 hyperintensity
1997 Namura	F/16	ASDH	T2 hyperintensity
1997 Zafonte	M/42	ASDH	T1 hypointensity
	M/16	ASDH	T1 hypointensity
1998 Takehara	F/27	ASDH	T1 hypointensity, T2 hyperintensity
1999 Mastronardi	F/73	ASDH	T1 hypointensity, T2 hyperintensity

M: male, F: female, AEDH: acute epidural hematoma, ASDH: acute subdural hematoma, CSDH: chronic subdural hematoma

to explain the mechanism of paradoxical motor deficit. To our knowledge, this report is the first demonstration of preoperative coronal MR images for diagnosing KN. In the left cerebral peduncle, no pathological signals were observed even in the diffusion-weighted images, suggesting reversibility of the lesion as previously reported<sup>4)</sup>. In present case study, sudden deterioration in neurological status first led us to suggest ischemic complications in the contralateral brain, because there were no significant changes in the hematoma and a midline shift appeared on repeated CT scans. Counter pressure from the contralateral CSDH might produce a minimal shift and higher ICP than typically expected. As a result, relatively little renewed hemorrhaging may cause KN in the absence of definite changes in CT images.

In such cases, serial examinations by MRI and MRA are necessary, and should be immediately performed in order to determine the next option of the treatment, such as thrombolysis or surgical removal of the hematoma.

In general, neurological symptoms in CSDH gradually progress over several weeks following head injuries<sup>2), 8), 11)</sup>. However, Kotwica and Brzezinski<sup>8)</sup> reported cases of sudden onset and rapid deterioration suggesting cerebral stroke, observed in 14 (11%) of 131 adult patients with CSDH. Further, in 9 (7%) patients<sup>8)</sup>, CSDH led to transtentorial herniation within a very short period. Of particular interest, 10% of their patients presented focal signs ipsilateral to CSDH. These observations suggest that atypical clinical pictures of CSDH as encountered in this case are not as uncommon as expected, and should always be taken into consideration in the management of CSDH.

## References

1. Cohen AR, Wilson J. Magnetic resonance imaging of Kernohan's notch. *Neurosurgery* 27: 205-207, 1990
2. Ernestus R-I, Beldzinski P, Lanfermann H, Klug N. Chronic subdural hematoma: surgical treatment and outcome in 104 patients. *Surg Neurol* 48: 220-225, 1997
3. Fujita K. MRI of the impending cerebral herniation caused by chronic subdural hematoma. *No to shinkei* 51: 648-649, 1999 (Jpn, with Eng abstract)
4. Itoyama Y, Fujioka S, Ushio Y. Kernohan's notch in chronic subdural hematoma: findings on magnetic resonance imaging. *J Neurosurg* 82: 645-646, 1995
5. Iwama T, Kuroda T, Sugimoto S, Miwa Y, Ohkuma A. MRI demonstration of Kernohan's notch : case report. *Neuroradiology* 34: 225-226, 1992
6. Jones KM, Seeger JF, Yoshino MT. Ipsilateral motor deficit resulting from a subdural hematoma and a Kernohan notch. *AJNR* 12: 1238-1239, 1991
7. Kernohan JW, Woltman HW. Incisura of the crus due to contralateral brain tumor. *Arch Neurol Psychiatry* 21: 274-277, 1929
8. Kotwica Z, Brzezinski J. Clinical pattern of chronic subdural haematoma. *Neurochirurgia* 34: 148-150, 1991
9. Mastronardi L, Puzzilli F, Ruggeri A, Guiducci A. Magnetic resonance imaging findings of Kernohan-Woltman notch in acute subdural hematoma. *Clinical Neurology and Neurosurgery* 101: 122-124, 1999
10. Namura S, Kang Y, Matsuda I, Kamijyo Y. Magnetic Resonance Imaging of Sequelae of Temporal lobe herniation secondary to traumatic acute subdural hematoma: Kernohan's notch and posterior cerebral artery territory infarctions contralateral to the supratentorial lesion. *Neurol Med Chir (Tokyo)* 37: 32-35, 1997
11. Sambasivan M. An overview of chronic subdural hematoma : Experience with 2300 cases. *Surg Neurol* 47: 418-422, 1997
12. Takehara S, Miyamoto T, Sugiura Y, Hiramatsu H, Akamine S. Kernohan notch. *No to Shinkei* 50: 774-775, 1998 (Jpn, with Eng abstract)
13. Wolf RFE, Weeme CA, Krikke AP. Kernohan's notch and misdiagnosis. *Lancet* 345: 259-260, 1995
14. Yamanaka M, Migita K, Uozumi T. A case of acute subdural hematoma with Kernohan's notch verified by CT scan. *Hiroshimaigaku* 48: 35-38, 1995 (Jpn)
15. Yamasaki F, Kodama Y, Hotta T, et al. Magnetic resonance imaging of Kernohan's notch in chronic subdural hematoma. *No to Shinkei* 49: 563-566, 1997 (Jpn, with Eng abstract)
16. Zafonte RD, Lee CY. Kernohan-Woltman notch phenomenon: An unusual cause of ipsilateral motor deficit. *Arch Phys Med Rehabil* 78: 543-545, 1997