

## Case Report

# Adenomyoepithelioma of the Breast

## A Case Report with an Immunohistochemical Study

Chun Yang WEN<sup>1)</sup>, Masahiro ITO<sup>2)</sup>, Toshiyuki NAKAYAMA<sup>1)</sup>, Masahiro NAKASHIMA<sup>3)</sup>, Toshimitsu NISHIMURA<sup>4)</sup>, Tetsuro HAYASHI<sup>4)</sup>, Toshinobu IMAIZUMI<sup>4)</sup>, Ichiro SEKINE<sup>1)</sup>

1) Department of Molecular Pathology, Atomic Bomb Disease Institute, Nagasaki University School of Medicine, Nagasaki

2) Department of Pathology, National Nagasaki Medical Center, Omura

3) Tissue and Histopathology Section Division of Scientific Data Registry, Atomic Bomb Disease Institute, Nagasaki University School of Medicine, Nagasaki

4) Department of Pathology, Isahaya General Hospital, Isahaya, Nagasaki

Adenomyoepithelioma is a rare primary tumor of the breast in women. It is characterized by a bicellular pattern consisting of both ductal and myoepithelial elements. We report here an additional case of adenomyoepithelioma in a 57-year-old woman. The aspiration cytology revealed atypical cell clusters, and the simple mastectomy was performed under the diagnosis of ductal carcinoma. Macroscopically, the tumor presented as a well-defined mass. Histologically, the tumor demonstrated the characteristic bicellular growth pattern consisting of ducts and a periductal proliferation of mainly polygonal neoplastic cells. Immunohistochemically, epithelial cells lining the glandular structures were strongly positive for cytokeratin and epithelial membrane antigen (EMA). Polygonal myoepithelial cells gave negative reactions with cytokeratin and EMA. Most polygonal myoepithelial cells were positive for  $\alpha$ -smooth muscle actin (SMA) and S-100 protein. Our case was a representative example of a typical adenomyoepithelioma, but the cytological diagnosis needs a deep attention to avoid overdiagnosis.

ACTA MEDICA NAGASAKIENSIA 46 : 73–76, 2001

**Key Words:** adenomyoepithelioma, breast, myoepithelial cell

### Introduction

Adenomyoepithelioma is a rare primary tumor of the breast in women. It consists of epithelial cells ac-

companied by myoepithelial cells. Both cell types are normally present in glandular tissue of the breast. It is characterized by a bicellular pattern consisting of both ductal and myoepithelial elements. In 1970, Hamperl<sup>1)</sup> first described a primary breast adenomyoepithelioma. Since then, reported cases have frequently been presented as single case reports<sup>2)</sup> or in small numbers<sup>3)</sup> and occasionally in large series<sup>4)</sup>. We report here an additional case of adenomyoepithelioma of the mammary gland bearing distinctive biphasic differentiated features.

### Case report

A 57-year-old woman noted a small mass in the lower interior quadrant of the right breast one month prior to admission. The mass was painless, and there had been no history of abnormal nipple discharge. The axillary lymph nodes were not enlarged. The aspiration cytology of the tumor revealed large and/or acinous cell clusters with nuclear atypia, and the cytologically class V was diagnosed. Simple mastectomy was performed for the diagnosis of ductal carcinoma.

The resected tissue was fixed in 10% buffered formalin and was embedded in paraffin. Sections of 4  $\mu$  m thick were stained with hematoxylin & eosin. Immunohistochemical staining was performed using the avidin-biotin-peroxidase complex (ABC) method and antibodies for cytokeratin, EMA, SMA, and S-100 protein.

The excisional specimen contained a well circumscribed tumor measuring 1.5x1.5cm. The cut surface was nodular and pale grayish. Microscopically, the

**Address Correspondence:** Chun Yang Wen, M.D.

Department of Molecular Pathology, Atomic Bomb Disease Institute, Nagasaki University School of Medicine, 1-12-4


Sakamoto, Nagasaki 852-8523 Japan

TEL: +81-95-849-7107 FAX: +81-95-849-7108

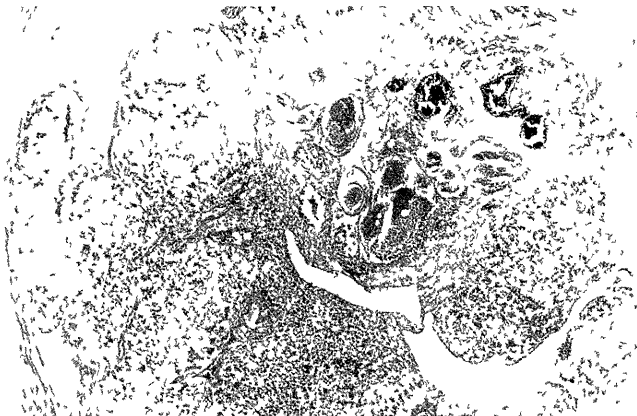
E-mail: d398008z@stcc.nagasaki-u.ac.jp

neoplasm had thick fibrous capsule and was composed of tumor cells arranged predominantly to form lobules separated by connective tissue septa (Fig 1) Each lobule was consisted of bicellular growth pattern of ducts and a periductal proliferation of mainly polygonal neoplastic cells (Fig 2) Cuboidal and columnar epithelial cells with eosinophilic cytoplasm and conspicuous nucleolus were arranged to form ductal structure, or occasionally formed small nests (Fig 3) Polygonal cells with abundant eosinophilic cytoplasm proliferated in sheets and often surrounded the ducts Round cells with abundant clear cytoplasm and round nuclei were intermingled with the eosinophilic cells (Fig 3)


By the immunohistochemical examinations, many cuboidal and columnar epithelial cells lining the glandular structures were strongly positive for cytokeratin (Fig 4) Positive staining for EMA was observed at the luminal surface of epithelial cells, with lesser or absent staining in the cytoplasm (Fig 5) Polygonal and clear myoepithelial-like cells showed negative reactions for cytokeratin and EMA Most polygonal and



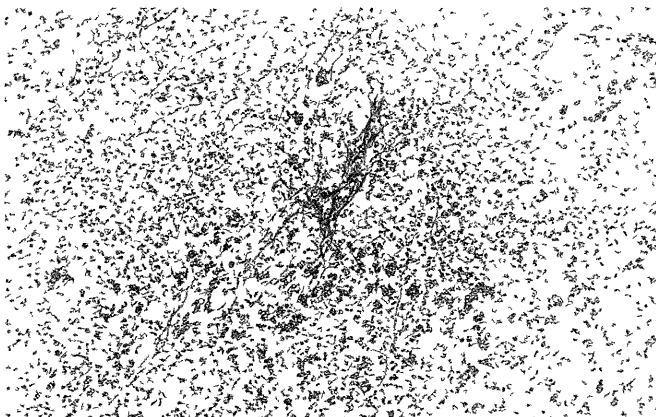
**Figure 3.** Cuboidal and columnar epithelial cells with eosinophilic cytoplasm and conspicuous nucleolus are arranged to form ductal structure, or occasionally form small nests Polygonal cells with abundant eosinophilic cytoplasm proliferate in sheets and often surround the ducts Clear cells with abundant hydropic cytoplasm and round nuclei are intermingled with the eosinophilic cells Hematoxylin & eosin, x200




**Figure 1.** The tumor with thick fibrous capsule is composed of tumor cells arranged predominantly to form lobules separated by connective tissue septa Hematoxylin & eosin, x40



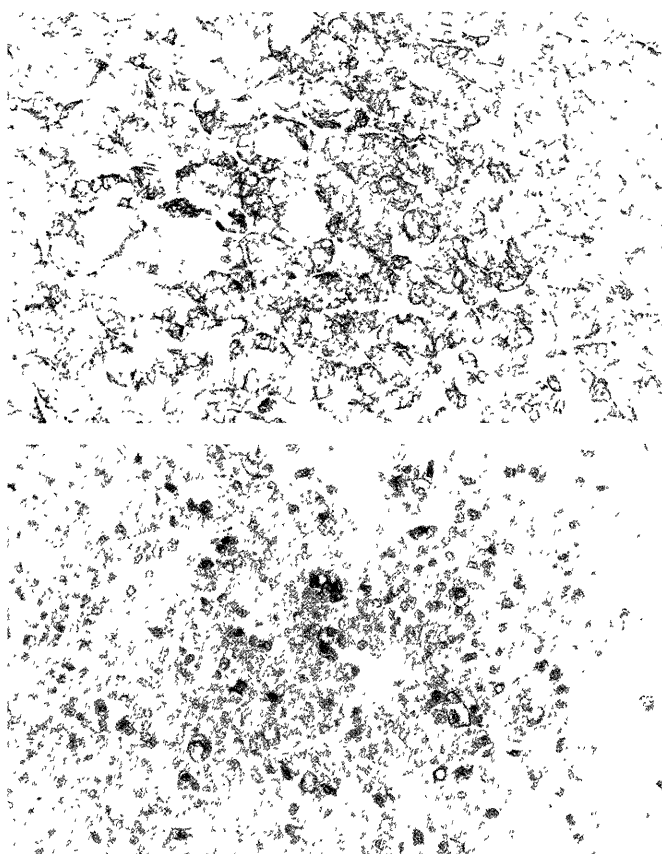
**Figure 4** Cuboidal and columnar epithelial cells lining the glandular structures were strongly positive for cytokeratin Cytokeratin, x200



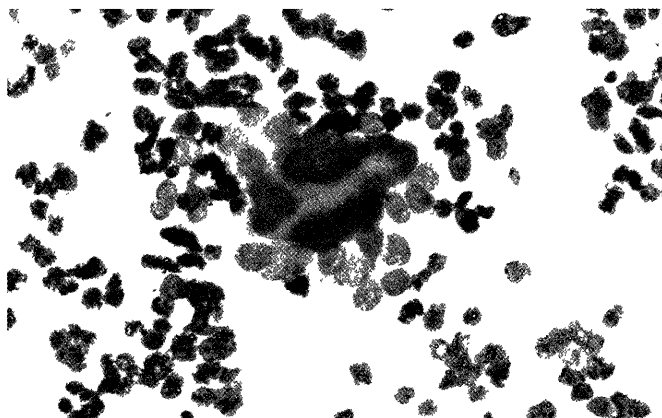
**Figure 2.** The tumor shows a bicellular growth pattern consisting of ducts and a periductal proliferation of mainly polygonal neoplastic cells Hematoxylin & eosin, x100



**Figure 5.** Positive staining for EMA was at the luminal surfaces of epithelial cells, with lesser or absent staining of the cytoplasm EMA, x200



**Figure 6.** Most polygonal and clear myoepithelial cells were positive for SMA (A, SMA, x200 ) and S-100 protein ( B, S-100 protein, x200 ), and these positive reactions were seen throughout the cytoplasm.



**Figure 7.** FNAB of Giemsa staining showed two cell pattern clearly. In the center of a cluster an hyperchromatic epithelial cells are present. Pale myoepithelial cells are arranged in the outer side of a cell cluster. (May Grunwald-Giemsa stain x400)

clear cells were positive for SMA and S-100 protein, and these positive reactions were seen throughout the cytoplasm (Fig 6A, B), indicating myoepithelial nature. In contrast, cuboidal and columnar epithelial cells lining the glandular structures or nests manifested no

positive staining for these proteins. Result of immunohistochemical staining is summarized in Table 1.

**Table 1.** Immunohistochemical characteristics of adenomyoepithelioma

	Epithelial cells	Myoepithelial cells
Cytokeratin	+	-
EMA	+	-
SMA	-	+
S-100 protein	-	+

+: positive, -:negative

## Discussion

Adenomyoepitheliomas appear to be formed by a proliferative process that includes a conspicuous contribution from the myoepithelium as well as the glandular epithelium. They frequently appear in the salivary glands and the skin. So far, a total of 123 cases have been described in the breasts of women<sup>5</sup>. Only two cases have been described in men<sup>6,7</sup>. The age of the patients ranged from 27 to 80 years (average 60 years)<sup>8</sup>. Patients with an adenomyoepithelioma of the breast usually present with a palpable painless mass. The grossly measured size of adenomyoepitheliomas has varied from 0.5 to over 5.0 cm, with a median size of 1.5 cm<sup>8</sup>. With rare exceptions, the tumors have been described as well circumscribed, firm or hard; lobulation is often noted. Small cysts were observed in a few cases<sup>4,9</sup>. Upon microscopic examination, the tumor can be found to be delineated by a true or pseudo-capsule and is composed of an epithelial and myoepithelial component. The epithelial component may form solid nests or ducts, cystic, trabecular, pseudo-papillary, or papillary structure. The epithelial cells usually have a cuboidal or cylindrical shape. Their cytoplasm is mostly eosinophilic, but can also be clear or amphophilic. A PAS-positive, diastase-resistant, secretion can be seen at the luminal side of the cytoplasm and/or in the lumen. The epithelial cells may also show apocrine features and may show squamous or mucinous metaplasia. Occasionally, a sebaceous cell population may be seen. Nuclear atypia has been described. Mitoses are usually scanty, but a mitotic count of up to 10 per 10 HPF has been

reported<sup>5</sup>). The myoepithelial component is arranged surrounding the epithelial component and can form solid strands, trabeculae, or even larger sheets. The myoepithelial cells are embedded in or surrounded by a basal lamina. They are usually polygonal or spindle shaped. Their cytoplasm is usually clear, but may also be eosinophilic, pale, pink, or amphophilic. PAS-positive, diastase-digestible, granular staining of the cytoplasm representing glycogen is often seen, especially in the cells with clear cytoplasm. Mitotic counts ranging from 0 to 16 per 10 HPF have been reported, and nuclear atypia may be present as well. There are only a few descriptions of fine-needle aspiration biopsy (FNAB). FNAB of adenomyoepithelioma is sometimes difficult to distinguish from a malignancy, because atypical/suspicious cytology is occasionally encountered<sup>10</sup>.

This case showed cell clustering and nuclear atypia by FNAB. But two cell pattern was hardly recognized with Papanicolaou staining. Retrospectively Giemsa staining clearly demonstrated a two-cell pattern in FNAB (Fig.7). To avoid misreading of atypical cell cluster as malignant, Giemsa staining is recommended. Immunohistochemistry is also helpful in distinguishing the two cell types (Table 1).

Most of the reported adenomyoepitheliomas were benign that can be treated by local excision. Local recurrence was rare and may be attributed to incomplete excision. The multinodular character of the lesion and peripheral intraductal extension are contributory factors. The metastases have been described in the literature. The sites of metastases were axillary lymph nodes<sup>11,12</sup>, lungs<sup>13,14</sup>, brain<sup>14</sup>, bones<sup>10</sup>, and thyroid gland<sup>5</sup>. Because of potential for local recurrence and subsequent malignant progression, adenomyoepitheliomas should preferably be treated by wide local excision. Although this case underwent simple mastectomy, case accumulation is important to establish surgical treatment.

We reported here a representative example of adenomyoepithelioma, and the cytological diagnosis is sometimes difficult to differentiate a malignancy.

## Reference

- 1) Hamperl H. The myoepithelia ( myoepithelial cells ). Normal state; regressive changes; hyperplasia; tumours. *Curr Top Pathol* 53: 161-220, 1970
- 2) Tamura S, Enjoji M, Toyoshima S, Terasaka R. Adenomyoepithelioma of the breast; a case report with an immunohistochemical study. *Acta Pathol Jpn* 38 (5): 659-665, 1988
- 3) Young RH, Clement PB. Adenomyoepithelioma of the breast; a report of three cases and review of the literature. *A. J. C. P* 89 (3): 308-314, 1988
- 4) Rosen PP. Adenomyoepithelioma of the breast. *Hum Pathol* 18 (12) 1232-1237, 1987
- 5) Bult P, Verwieel J M M, Wobbes T, et al: Malignant adenomyoepithelioma of the breast with metastasis in the thyroid gland 12 years after excision of the primary tumor; case report and review of the literature. *Virchows Arch* 436: 158-166, 2000
- 6) Berna J D, Arcas I, Ballester A, Bas A. Adenomyoepithelioma of the breast in a male. *Am J Roentgenol* 169: 917-918, 1997
- 7) Tamura G, Monma N, Suzuki Y, Satodate R, Abe H. Adenomyoepithelioma (myoepithelioma) of the breast in a male. *Hum Pathol* 24: 678-681, 1993
- 8) Rosen P P, Oberman H A. adenomyoepithelioma. In *Tumors of the Mammary Gland (AFIP, Third Series, Washington, D. C.)* pp.91-96, 1992
- 9) Gusterson B A, Sloane J P, Middwood C. Ductal adenoma of the breast-a lesion exhibiting a myoepithelial/epithelial phenotype. *Histopathology* 11: 103-110, 1987
- 10) Aydin O, Cinel L, Egilmez R, Ocal K, Ozer C. Adenomyoepithelioma of the breast. *Diag Cytopathol* 25:194-196, 2001
- 11) Chen P C, Chen C-K, Nicastrì A D, Wait R B. Myoepithelial carcinoma of the breast with distant metastasis and accompanied by adenomyoepithelioma. *Histopathology* 24: 543-548, 1994
- 12) Tavassoli F A. Myoepithelial lesions of the breast. Myoepitheliosis, adenomyoepithelioma, and myoepithelial carcinoma. *Am J Surg Pathol* 15: 554-568, 1991
- 13) Foschini M P, Pizzicannella G, Peterse J L, Eusebi V. Adenomyoepithelioma of the breast associated with low-grade adenosquamous and sarcomatoid carcinoma. *Virchows Arch* 472: 243-250, 1995
- 14) Loose J H, Patchefsky A S, Hollander I J, et al: Adenomyoepithelioma of the breast: a spectrum of biologic behavior. *Am J Surg Pathol* 16: 868-876, 1992