

Case Report

Stenting with Coil Embolization for Dissecting Restenosis of the Internal Carotid Artery after Balloon Angioplasty

Masanari ONIZUKA¹⁾, Makio KAMINOGO²⁾, Kazuhiko SUYAMA¹⁾, Tatsuya MINAGAWA¹⁾, Shingo MIZOTA¹⁾, Akira SHIBAYAMA¹⁾, Hisaya MIYAZAKI¹⁾

1) Department of Neurosurgery, Sankoukai Miyazaki Hospital

2) Department of Neurosurgery, Nagasaki University School of Medicine

We report here the successful use of endovascular stenting combined with coil embolization for dissective restenosis of the internal carotid artery after balloon angioplasty. The patient was a 76-year-old man with a history of frequent transient right hemiparesis. Angiogram showed severe stenosis in the cervical portion of both internal carotid arteries. The left lesion was treated initially by percutaneous transluminal angioplasty, which resulted in satisfactory dilatation. However, three months later, angiogram revealed restenosis and subintimal dissection at the original region. Stent implantation was performed to reconstruct the true arterial lumen, then packed the false lumen with Guglielmi detachable coils through the stent mesh. Despite anticoagulation therapy, right leg monoparesis developed two days after coiling but disappeared after a week. Nine months later, complete obliteration of the false lumen and patency of the internal carotid artery were confirmed on angiogram. This combined technique may be useful to better manage dissecting restenosis in the cervical portion of the left internal carotid artery after balloon angioplasty.

ACTA MEDICA NAGASAKIENSIA 46 : 73–76, 2001

Key Words: dissecting restenosis, internal carotid artery, percutaneous transluminal angioplasty, stent, Guglielmi detachable coil

Introduction

The use of percutaneous transluminal angioplasty (PTA) has been reported to treat atherosclerotic lesions in the cervical portion of the internal carotid ar-

tery (ICA). There are some periprocedural complications in PTA, including distal embolism and arterial dissection. Dissection of the cervical ICA is the most difficult issue and can result in acute arterial occlusion, pseudoaneurysm formation. The introduction of stenting has improved safety but stenting alone may not secure an arterial stenosis caused by progressively expanding pseudolumen of the arterial dissection. We report here a case of dissecting restenosis of the cervical ICA after PTA, which we successfully treated using a combination of carotid stenting and embolization with Guglielmi detachable coils (GDCs).

Case Report

A 76-year-old male with a long history of smoking was admitted to our hospital with a history of frequent transient right hemiparesis in August 1998. He had a history of angina pectoris, and he had previously experienced seven cerebral ischemic attacks. Computed tomography (CT) showed no cerebral infarcts, but carotid angiography revealed severe stenosis in the cervical portion of the both ICAs. (Fig.1) On left carotid angiogram, cross-filling via the anterior communicating artery was observed under manual compression of the right carotid artery. Three-dimensional CT angiography showed calcification at the stenotic lesion in the left cervical ICA (Fig.1). The patient refused invasive surgery, but agreed to endovascular treatment¹⁾ and informed consent for using stent was obtained. The stenotic lesion was crossed with a 3 x 20-mm balloon catheter (Stealth, Boston Scientific, Boston, MA) and dilated slowly in 30-second increments to a final maximum of 12 atmospheres. The balloon was then exchanged for a 5 x 20-mm balloon and the lesion was similarly dilated slowly and intermittently to approximately 12 atmospheres. Total occlusion time of the left ICA did not exceed two minutes. Using a local

Address Correspondence: Masanari Onizuka, M.D.

Department of Neurosurgery, Sankoukai Miyazaki Hospital,
1575-1 Kuyama, Isahaya-shi, 854-0066

TEL: +81-957-25-4800 FAX: +81-957-26-7054

E-mail: onizuka@fsinet.or.jp



Fig.1. Right cervical carotid angiogram showing severe stenosis of the internal carotid artery (left). Left cervical carotid angiogram showing severe stenosis of the internal carotid artery (middle). Three-dimensional CT (maximum intensity project image) showing calcification at the stenotic lesion of the left internal carotid artery (right).

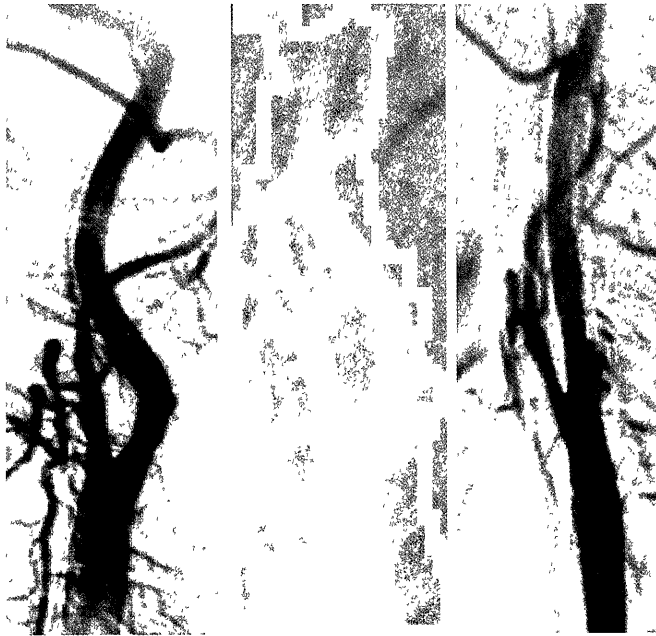


Fig.2. Left cervical carotid angiograms: A satisfactory dilatation of the left internal carotid artery lesion is observed after percutaneous transluminal angioplasty (left). Three months after the angioplasty, the left carotid angiogram showed restenosis and subintimal dissection at the original region of the left internal carotid artery (center). A 70 mm-long Wallstent was placed over the stenotic lesion of the internal carotid artery with the false lumen (right).

anesthetic and a light neuroleptics, continuous neurological monitoring was performed during the procedure,



Fig.3. Lt.carotid arteriogram showing the disappearance of pseudoaneurysm packed with Guglielmi detachable coils (GDCs) through the stent mesh two days after stenting. (GDC10. Soft. 3mm×6cm+2mm×4cm)

and a satisfactory dilatation of the left cervical ICA was obtained. However, an hour later, mild right hemiparesis developed. Distal embolism was suspected, and tissue plasminogen activator (t-PA) was intravenously infused for an hour. No infarct was observed on magnetic resonance images (MRI), and the right hemiparesis gradually improved the next day. The patient remained asymptomatic thereafter with an oral antiplatelet medication, but the left carotid bruit was noted three months after the procedure. Angiogram revealed a restenosis and a subintimal dissection at the original region of the left cervical ICA (Fig.2). Two months later, transient right hemiparesis occurred and he was readmitted. A 70 mm-long self-expanding stent (Wallstent; Schneider AG, Zurich, Switzerland) was placed over the stenotic lesion to reconstruct the true arterial lumen (Fig.2), and the pseudolumen with an aneurysmal formation was packed with GDCs (Boston Scientific) through the 1-mm square mesh of the stent two days after stenting (Fig.3). Despite anticoagulation with heparin (15,000 unit a day), right leg monoparesis developed after coil embolization. Argatrovan, a commercially available thrombin inhibitor, was immediately and continuously administered for five days. Motor disturbance completely disappeared after a week, although a low density area in the left frontal lobe was observed on CT scan. The patient was discharged and showed no neurological deficits postoperatively with an oral antiplatelet medication. Complete obliteration of the false lumen and patency of the left cervical ICA

were confirmed on the follow-up carotid angiogram nine months after stenting (Fig. 4).

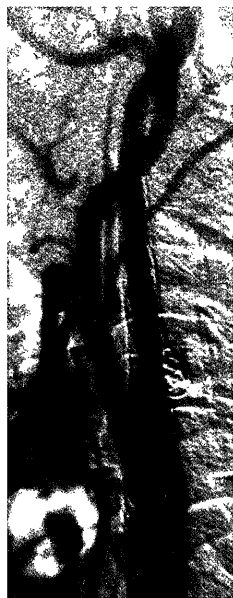

Fig.4. Left cervical carotid angiogram showing the complete obliteration of the false lumen and the patency of the internal carotid artery nine months after the procedure.

Discussion

Using a combination of carotid stenting and embolization with GDCs, we successfully treated for the dissecting restenosis of the cervical ICA after PTA. Stent implantation was first performed to reconstruct the true arterial lumen of the left ICA. Previous studies have demonstrated that dissection with a pseudoaneurysm formation in the cervical ICA could be treated by only stenting²⁻⁶. In the presence of an intimal flap and a small communication between true and false lumina, a self-expanding stent could displace the intimal flap from the lumen of the artery and interfere with the flow into the aneurysm. However, since the dissected site was open, it was difficult to determine whether the false lumen would be decreased in size and secured following stenting. Since we consider that endovascular embolization of the dissected site is among the best management for dissecting restenotic lesion of the cervical ICA, we decided to pack the false lumen with GDCs through the stent mesh^{9, 10, 13}. PTA is generally thought to be a less invasive procedure to treat an atherosclerotic lesion in the cervical ICA than conventional surgery such as carotid endarterectomy especially in elderly patients⁷. However, there is some risk in PTA since dissection of the cervical ICA

occasionally occurs following the procedure because mechanical dilatation with a balloon damages the arterial wall, which may lead to a dissective restenosis. There are some therapeutic approaches proposed for dissecting restenosis of the cervical ICA following PTA and surgery such as carotid endarterectomy or IC ligation with or without extracranial-intracranial bypass is an option. Although conservative therapy using antiplatelet or anticoagulant agents is recommended to prevent embolic events in asymptomatic patients, in the present case, thromboembolic stroke occurred. However, the patient refused invasive surgery and opted for endovascular treatment¹². Distal embolism is another serious problem that often occurs during PTA^{8, 11}. Although many commercially available devices aimed at reducing microembolism are being developed, we did not provide cerebral protection for distal embolism in the present case and intravenous infusion of t-PA exerted a beneficial effect for cerebral protection resulting in an improvement of the ischemic signs. An alternative to this may have been systemic anticoagulation or the use of a protective balloon. Although treatment has been successful for nine months after the procedure, we hope that improvements in vascular stents such as the development of a covered stent with long-term patency will lead to another treatment option for dissecting restenosis of the cervical ICA^{1, 9}. In conclusion, the combined approach of stenting and coiling used in the present case may be useful to better manage dissective restenosis of the cervical ICA after balloon angioplasty.

References

1. Marotta TR, Buller C, Taylor D, et al: Autologous vein-covered stent repair of a cervical internal carotid artery pseudoaneurysm. *Neurosurgery* 42: 408-412, 1998
2. Dorros G, Cohn JM, Palmer LE: Stent deployment resolves a petrous carotid artery angioplasty dissection. *AJNR* 19: 392-394, 1998
3. Kobayashi E, Shimazaki K, Shimoeda N: Stenting for dissecting restenosis of the subclavian artery after balloon angioplasty. *No Shinkei Geka* 27(4): 365-369, 1999
4. Liul AY, Paulsen RD, Marcellus ML: Long-term outcomes after carotid stent placement treatment of carotid artery dissection. *Neurosurgery* 45: 368-374, 1999
5. Bejjani GK, Monsein LH, Laird JR: Treatment of symptomatic cervical carotid dissections with endovascular stents. *Neurosurgery* 44:755-761, 1999
6. Miyachi S, Ishiguchi T, Taniguchi K, et al: Endovascular stenting of a traumatic dissecting aneurysm of the extracranial internal carotid artery. *Neurol Med Chir (Tokyo)* 37 : 270-274, 1997
7. Peralta AG, Mayol A, Marcos JG, et al: Percutaneous transluminal angioplasty of the symptomatic atherosclerotic carotid arteries. *Stroke* 27: 2271-2273, 1996
8. Phatours CC, Higashida RT, Malek AM, et al : Clinical use of stents for carotid artery disease. *Neurol Med Chir (Tokyo)* 39, 809-827, 1999

9. Saito R, Ezura M, Takahashi A, et al: Combined neuroendovascular stenting and coil embolization for cervical carotid artery dissection causing symptomatic mass effect. *Surg Neurol* 53: 318-22, 2000
10. Sekhon LH, Morgan MK, Sorby W, et al: Combined endovascular stent implantation and endosaccular coil placement for the treatment of a wide-necked vertebral artery aneurysm. *Neurosurgery* 43: 380-384, 1998
11. Tanaka M, Taki W, Miyamoto S, et al: Percutaneous transluminal angioplasty (PTA) for stenosis at the subclavian artery and at the origin of the vertebral artery: therapeutic indication and some adjunctive safe methods during PTA. *No Shinkei Geka* 22: 939-46, 1994
12. Vale FL, Fisher WS, Jordan WD: Carotid endarterectomy performed after progressive carotid stenosis following angioplasty and stent placement. *J Neurosurg* 87: 940-943, 1997
13. Yamaura, E, Tani, M, Yokota, A., et al : Endovascular treatment of ruptured dissecting aneurysms aimed at occlusion of the dissected site by using Guglielmi detachable coils. *J Neurosurg* 90:853-856, 1999