

Study of Normal Fissures Seen on Posteroanterior and Left Lateral Chest Radiographs

Aamer AZIZ, Kazuto ASHIZAWA, Kenji NAGAOKI, Hideyuki HAYASHI, Kuniaki HAYASHI

Department of Radiology, Nagasaki University School of Medicine, 1-7-1 Sakamoto, Nagasaki, 852-8501. Japan.

This study included consecutive 318 pairs of posteroanterior (PA) and left lateral (LL) chest radiographs taken under routinely used conditions with the patients in erect position. Major, minor and accessory fissures visualized on these radiographs were described according to their visibility, position, length and shape. On PA chest radiographs, superolateral major fissures in 54 (17%), superomedial major fissures in 20 (6%), minor fissures in 234 (74%), inferior accessory fissures in 19 (6%), superior accessory fissures in 12 (4%), left minor fissures in 16 (5%) and azygos fissure in 2 (0.6%) patients were seen. On LL chest radiographs, 266 (84%) right major fissures, 242 (76%) left major fissures, 210 (66%) minor fissures and 6 (2%) superior accessory fissures were seen. We have described the frequencies of various orientations, shapes and lengths of these fissures. This study not only supports the common knowledge of the appearances of pulmonary fissures but also explains numerically the various frequencies of these common patterns and variations seen in practice.

ACTA MEDICA NAGASAKIENSIA 46 : 67–71, 2001

Key Words: Chest radiography, pulmonary fissures, radiographic anatomy, PA and lateral chest radiographs.

Introduction

The routine posteroanterior (PA) and left lateral (LL) chest radiographs remain the initial studies obtained in the radiologic diagnosis of chest disease. Both the lungs are divided into various lobes by double layers of infolded reflections of visceral pleura called the fissures (1). The major fissure on PA chest radiograph may be visualized as “superolateral major fissure” (2) or “superomedial major fissure” (3). On

the LL radiographs, the right major fissure appears more oblique and ends in a more anterior position inferiorly, merges with the right hemidiaphragm, and often joins with the minor fissure (1).

The minor fissure is more constant in its visualization on PA and LL chest radiographs. Its lateral position is more often seen than the medial (4). Part of the minor fissure may become vertical medially (5)

Various accessory fissures may also be seen on PA or LL chest radiograph. These include azygos (6), inferior accessory (7), superior accessory (8) and left minor fissures (9). The normal appearances of the major fissures and their variants have been described extensively and correlated with the CT findings (10).

To our knowledge, there has been no previous study that has described the pulmonary fissures in quantitative details or the frequencies with which various shapes, orientations, sizes and relationships of various fissures may be seen. The aim of this study was to enumerate the common patterns of visualization of pulmonary fissures and to describe the frequencies with which these patterns are seen on the PA and LL chest radiographs.

Materials and Methods

A total of 412 pairs of PA and LL chest radiographs were studied between August 1999 and July 2000. 94 pairs of radiographs were discarded and not studied further as the patients were either recently operated upon, had diseases that changed the normal anatomy or the chest radiographs were not adequate due to artifacts, poor exposure or inadequate positioning.

The remaining 318 pairs of PA and LL radiographs were included in this study. These radiographs were taken under routinely used conditions on commercially available x-ray machines, with the patients in erect position. Whole of the chest, including the supraclavicular fossae, lower neck and upper abdomen were included in the field of view. The patients were between 18 and 89 years of age with a mean age of 59 years. 158

Address Correspondence: Aamer Aziz, M.D.

Department of Radiology, Nagasaki University School of Medicine, 1-7-1 Sakamoto, Nagasaki 852-8501. Japan

TEL: +81-95-849-7355 FAX: +81-95-849-7357

E-mail: aamer@alpha.med.nagasaki-u.ac.jp

patients were males and 160 were females. Of these patients, 242 did not have any history or symptoms pertaining to a chest disease, while 76 patients had pulmonary disease of mild nature that was not severe enough to cause any anatomical change in the lungs. The pairs of radiographs were thoroughly studied for the visibility, position, length and shape of the major, minor and accessory fissures.

Results

On PA chest radiographs, *superolateral major fissures* were visualized in 54 (17%) patients. They were visualized bilaterally in 12 (4%), only on the right side in 28 (9%) and only on the left side in 14 (4%) patients. They were seen as an interface of lateral opacity and medial lucency in 40 (74 % of the visualized fissures), and as a line in the rest. The fissures were convex facing superolaterally in 48 patients, while the rest appeared as flat facing superolaterally or convex facing laterally. The length of the fissures was 2 to 6 cm with an average of 3.4 cm (Fig 1).

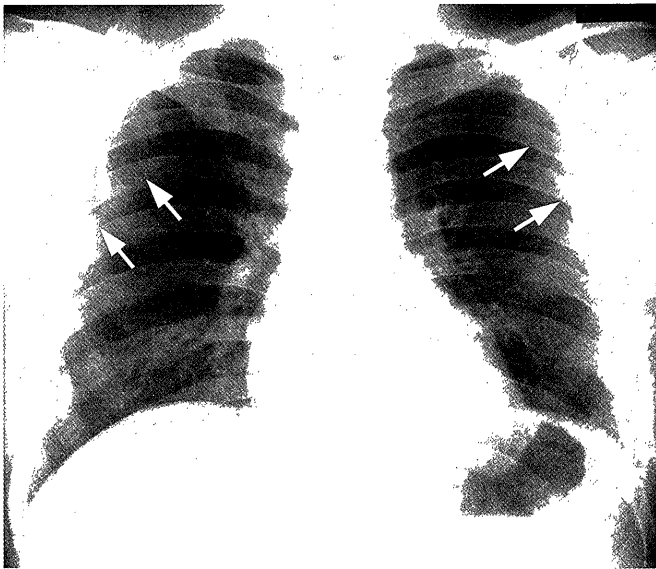

Fig.1. Superolateral major fissures. PA chest radiograph shows the superolateral major fissures on both sides (arrows) as curving contours with lateral opacity and medial lucency. The left fissure extends higher than the right. (Reprinted with permission from Hayashi K et al. (10))

The *superomedial major fissures* were seen in 20 (6%) patients at the level just superior to the hilar regions on the right side in 16 (5%) and on the left side in 4 (1%) patients. They were seen as a convex line facing superolaterally in 10, flat facing superolaterally in 8 and convex facing laterally in 2 patients. They

were 3 to 5 cm in length with an average of 3.6 cm (Fig 2).

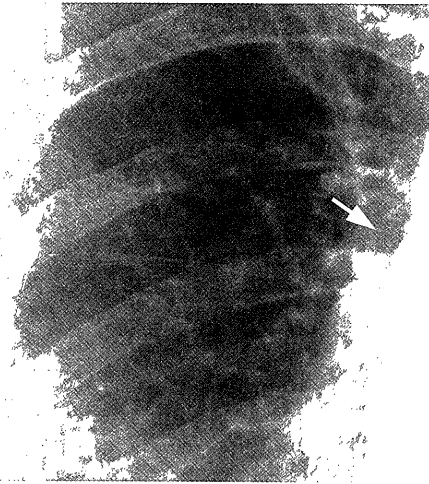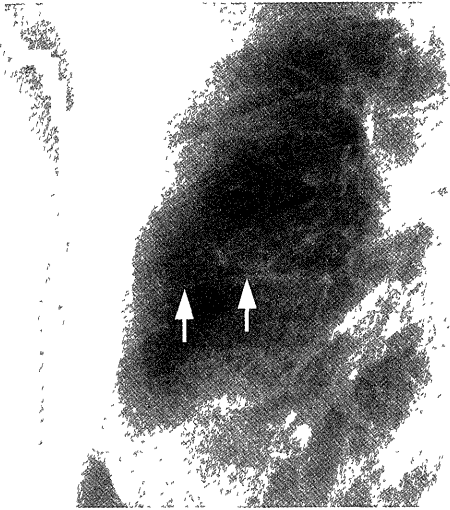


Fig.2. Superomedial major fissure. PA chest radiograph shows the superomedial major fissure on the right (arrow). Incidentally, the minor fissure is seen as double lines. (Reprinted with permission from Hayashi K et al. (10))

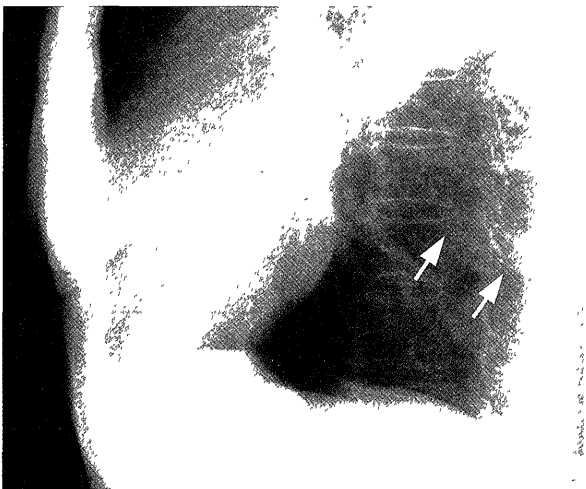
The *minor fissures* were seen in 234 (74%) patients. The lateral end was at the level of right 5th to 7th ribs in 214 (92% of the visualized fissures). The shape of minor fissure was very variable. It was convex facing superomedial in 92 and convex facing superolateral in 70 patients. Rest of the patients showed many varieties of shapes with less than 10% incidence of each. The visible length of minor fissures was also variable, however most (70) were seen between three-fourths from the lateral chest wall to just reaching the mediastinum.

A total of 49 (16%) accessory fissures were visualized on PA chest radiographs. Twelve (4%) *superior accessory fissures*; 8 in the right and 4 in the left middle lung fields, were seen. On the right side they were inferior to the minor fissures (Fig 3). Ten were flat facing superolaterally while 2 were convex facing superolaterally. A total of 19 (6%) *inferior accessory fissures* were seen, of which 14 were in the right and the rest were in the left lower lung fields. They were convex facing superolaterally in 17 patients (Fig 4), while 2 were convex facing inferomedially. Sixteen (5%) *left minor fissures* were seen as convex lines facing superomedially (Fig 5). Only 2 (0.6%) *azygos fissures* were seen in the right upper lung field. These were thin lines, facing convex laterally in the upper medial lung fields (Fig 6). The common patterns of the fissures as visualized on the PA chest radiograph are illustrated in Fig 7.

On LL chest radiographs, the right major fissures were visible in 266 (84%) patients while the left were



(a)



(b)

Fig.3. Superior accessory fissure (arrows): a) on the PA chest radiograph it runs somewhat parallel to and inferior to the minor fissure, b) on the LL chest radiograph it is parallel to but posterior to the minor fissure overlapping the vertebral bodies.

visible in 242 (76%). Both the fissures were very variable in appearance and were visible as convex lines facing posteroinferiorly in infrahilar and inferior portions in 193 patients. In the upper parts, they were convex facing anterosuperiorly in 50 patients. 20 of the major fissures were seen in their entire lengths.

The minor fissures were seen in 210 (66%) patients, 156 being convex facing anterosuperiorly, while 54 were convex facing posterosuperiorly. They were seen for more than three-fourth of the distance between anterior chest wall and the major fissure in 86 patients, while they were seen crossing the major fissure and extending posteriorly in 54 patients.

The 6 (2%) superior accessory fissures were seen on the LL chest radiographs (Fig 2). They were flat lines




Fig.4. Right inferior accessory fissure seen as a line in the right lower lung field convex facing superolaterally (arrows).

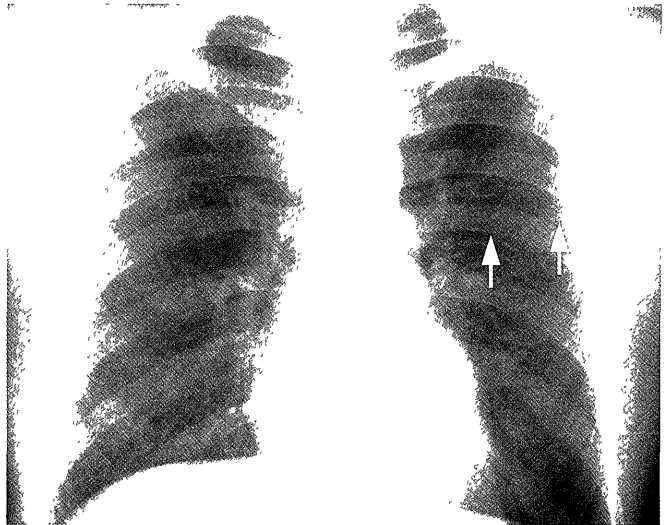

Fig.5. The minor fissure seen on the left side (arrows): it is the mirror image of the normal right minor fissure and is seen convex facing superomedially.

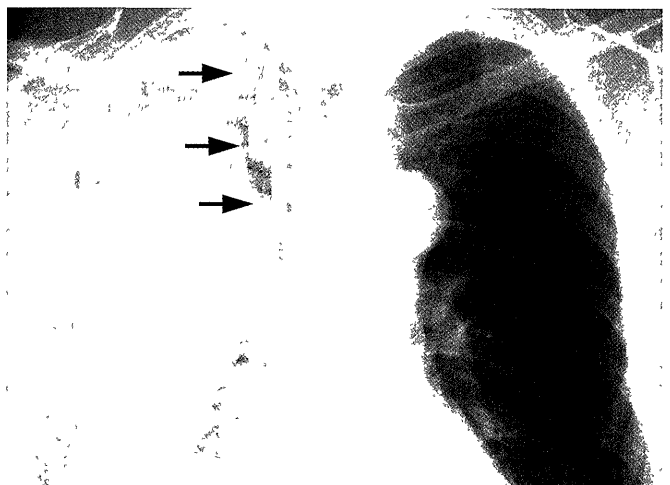


Fig.6. Azygos fissure is seen as a thin curving line, convex facing laterally in the medial part of right upper lobe (arrows).

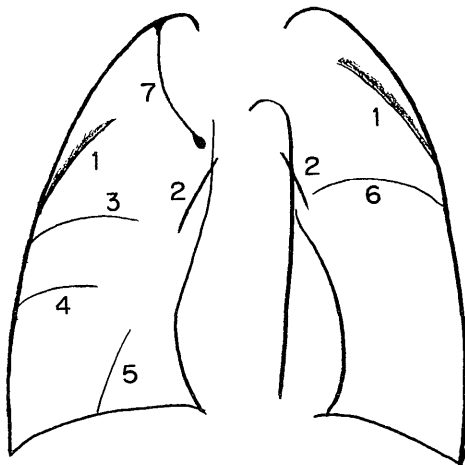


Fig.7. Scheme showing the common orientations of the fissures as seen on the PA chest radiograph. 1=Superolateral major fissures, 2=superomedial major fissures, 3=minor fissure, 4=superior accessory fissure, 5=inferior accessory fissure, 6=left minor fissure, 7=azygos fissure.

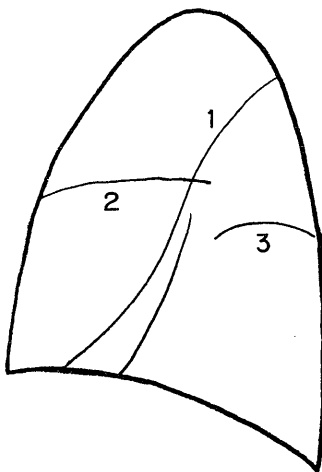


Fig.8. Scheme showing the common orientations of the fissures as seen on the LL chest radiograph. 1=major fissures, 2=minor fissure, 3=superior accessory fissure.

facing posterosuperiorly and overlapped the vertebral bodies. The common orientations of the fissures as seen on the LL chest radiographs are illustrated in Fig 8.

Discussion

The superolateral major fissures were visualized on 17% of the PA chest radiographs in our study, being visible bilaterally in 4%, on the right side in 9% and on the left side in 4% of the cases. This is in agreement with another study in which they were seen in 14% of cases (2). The left superolateral major fissure was situated higher than the right. The fissure was most commonly seen as a convex interface facing superolaterally.

Extension of extrapleural fat into the lips of the major fissure has been proposed as the cause of visualization of superolateral major fissure on PA chest radiograph (2). The curving opacity in the upper outer lung fields may be mistaken for a consolidation or, at times, for a mass lesion. The knowledge of this opacity being produced by the superolateral major fissure is essential to avoid any pitfall in diagnosis.

Our study shows superomedial major fissures in 6% of the cases, which is also in agreement with the already published frequency of 8% (3). They were most often seen on the right side and appeared as lines that were convex or flat facing superolaterally. This shape would be expected considering the anatomy of this part of the major fissure, as has been described in a previous publication illustrating the relation of superomedial major fissure and the sagittal orientation of the major fissure in that part (10). The upper lobe binds this part of the major fissure superiorly, and any opacity bordering the superomedial fissure from above would indicate an upper lobe disease. However extension of pleural effusion in this part of the major fissure may also produce a similar opacity (3).

The LL chest radiograph displayed the major fissures with more clarity than the PA view, as the general orientation of the major fissure is tangential to x-ray beam in the lateral view (10). In our cases, the major fissures were mostly convex facing anterosuperiorly in their upper parts and convex facing posteroinferiorly in their lower parts. This follows the well-known propeller-blade-like shape of the anterior surface of the lower lobe (8), and appears as S-shaped when seen on the LL chest radiograph. Variations in the orientation of the major fissures were also seen. These are due to the fact that the major fissures are undulating and only the portion of the major fissure that is tangential to the x-ray beam is projected on the LL chest radiograph. The completeness of fissures could not be ascertained on PA or LL chest radiographs. At times it was difficult to determine which fissure was being visualized, especially in cases where only one of the major fissures was being seen in its upper part. The right major fissure was more anterior to the left, was less vertical and joined the right hemidiaphragm (1), which helped in its identification.

Minor fissures were visualized better on the PA (74%) rather than the LL chest radiographs (66%). This frequency of visualization, especially on the PA chest radiograph, is slightly higher than the already published frequency of 50 to 60% (3). A wide variety of the appearance of minor fissures was noted, which makes it difficult to ascertain the abnormal shape that might indicate adjacent lobe volume loss or disease.

The part of the minor fissure not visualized does not mean that it is incomplete, but rather the plane of the fissure is not parallel to the x-ray beam. On the LL chest radiograph, the minor fissure was usually seen extending from its anterior end to the major fissure and even crossing it further posteriorly. As the major fissures are undulating in their course, visualization of a more anterior part of major fissure than its attachment to the minor fissure may account for this appearance (3).

The accessory fissures visualized most frequently were the inferior accessory fissures, seen in 6% of patients, which is in agreement with another study in which they were seen in 5 to 10% of cases. The inferior accessory fissures at times bind the consolidation of a part of the lower lobe and would then appear as an interface (7). The other accessory fissures visible were the superior accessory fissures on 4% of PA and 2% of LL chest radiographs. They were more caudal to the minor fissures and extended more posteriorly to be superimposed on the vertebral column, which differentiated them from the minor fissures (1, 7). The azygos fissure was seen on only 2 (0.6%) PA chest radiograph, and is in agreement to known frequencies of 0.4 to 1% (6). The left minor fissures were visualized in 5% of the patients and were the mirror images of the normal right fissures. The frequency of the left minor fissures as seen on the chest radiographs has been reported as 1.6%, however the study based on anatomical models has reported a much higher inci-

dence of 8 to 18% (9). Our study has a frequency of visualization of the left minor fissure that is between the aforementioned two studies.

In conclusion, we have demonstrated the frequencies of visualization of various forms and orientations of major, minor and accessory pulmonary fissures as seen on the PA and LL chest radiographs. Awareness of these variations is important to avoid pitfalls in the diagnosis of various chest diseases.

References

1. Wilson AG: Pleura and pleural disorders, In *Imaging of diseases of the chest.* (Armstrong P, Wilson AG, Dee P, Hansell DM, eds.; 2nd Ed. Mosby, St. Louis, Mo.) pp.641-716, 1995.
2. Proto AV, Ball JB: The superolateral major fissures. *AJR* 140: 431-437, 1983.
3. Proto AV. The chest radiograph: anatomic considerations. *Clinics in chest medicine* 5:213-246, 1984.
4. Felson B: *Chest Roentgenology*, Philadelphia, 1973, WB Saunders.
5. Gross BH, Spizarny DL, Granke DS: Sagittal orientation of the anterior minor fissure: radiography and CT, *Radiology* 166:717-719, 1988.
6. Speckman JM, Gamsu G, Webb WR: Alterations in CT mediastinal anatomy produced by an azygos lobe, *AJR* 137:47-50, 1981.
7. Godwin JD, Tarver RD: Accessory fissures of the lung, *AJR* 144:39-47, 1985.
8. Proto AV, Speckman JM: The left lateral radiograph of the chest, *Med Radiogr Photogr* 55:30-74, 1979.
9. Austin JHM: The left minor fissure, *Radiology* 161:433-436, 1986.
10. Hayashi K, Aziz A, Ashizawa K, Hayashi H, Nagaoki K, Otsuji H, Radiographic and CT appearances of the major fissures in normal and various abnormal conditions. *Radiographics* 2001 (in press).