

# Role of Arterial Blood Supply in Orthotopic Whole and Partial Liver Transplantation in the Rat

Kimiro TANAKA, Takashi KANEMATSU

Department of Surgery II, Nagasaki University School of Medicine, Nagasaki, Japan

**Aims:** The hepatic artery (HA) thrombosis is a serious complication after liver transplantation (LT). In the present study, role of blood supply from HA to the grafted liver was experimentally investigated.

**Methods:** Rats were grouped into 4: Group I-whole LT without HA reconstruction, Group II-partial (30%) LT without HA reconstruction, Group III - whole LT with HA reconstruction, and Group IV - partial (30%) LT with HA reconstruction.

**Results:** In Group III, posttransplant elevation of serum levels of GOT and total bilirubin was minimal. Those levels in Groups I and II were significantly higher, compared to those in Groups III and IV. Dilatation of the bile duct and bile stasis were evident in 60% and 71% of rats in Group I and II, respectively. In Group II, histological examination demonstrated that proliferation of bile duct around the portal triad was prominent at early period after LT. Those findings were mild and there was no histological evidence of destruction of vascular and bile duct structures in Groups III and IV.

**Conclusion:** These findings were suggestive that arterial blood flow to the grafted liver played an important role to feed nutrients to the biliary tree. In order to prevent damage in the biliary tract, successful reconstruction of HA is essential in LT.

---

**Key words:** Liver transplantation, arterial blood supply, biliary tract damage, rats

## Introduction

Liver transplantation (LT) has become a well-established modality for treatment of previously fatal liver disease. Overall survival after LT has dramatically improved (1). The refinement of surgical techniques and advent of new immuno-suppressive agents have accounted for remarkable progress (2).

---

**Address Correspondence:** Kimiro Tanaka, MD.  
Tanaka Clinic, 1324-2 Jikibago, Seihi-cho, Nishisonogi-gun,  
Nagasaki 851-3305, Japan  
TEL:+81-959-27-0035, FAX:+81-959-27-0677

The early posttransplant period is the time with the greatest incidence of death. Shaw et al. (3) reported that 43% of deaths occurred in the first month after LT, and Mora et al. (4) found that 47% of all deaths occurred in the first 3 months. The marked improvement in survival curves of each of the years was primarily in the early posttransplant period (5).

Liver reduction techniques, including reduced-size LT (6), split LT (7) and partial LT from living donors (8) were developed to overcome the shortage of size matched graft for children. Partial LT from living donors is now a procedure of choice even for adult candidates (9). In all these procedures, techniques share the problem of size mismatch between the vessels of the adult liver and the recipient. Rela et al. (7) showed that the hepatic artery (HA) thrombosis was a serious complication related to LT.

The method of LT in rats was developed by Lee et al. (10) and was established by Kamada et al. (11). In rat LT model, reconstruction of HA is not always required, and the grafted liver functions by blood supply only from the portal vein. By "Sleeve's technique", we have successfully established the technique to reconstruct HA in the rat. In the present study, in order to investigate the role of HA in LT, this rat LT model was utilized.

## Materials and Methods

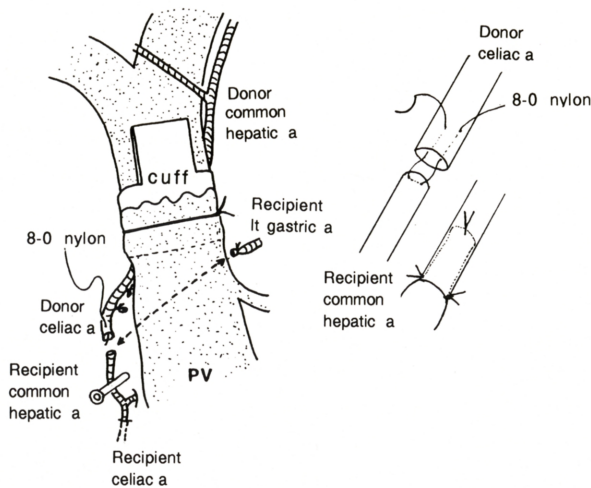
### Animals:

Male, inbred rats (LEW, RT1<sup>t</sup>) weighing 250-350 g were used. The study was performed according to the ethical guidelines of the Animal Care Committee of Nagasaki University.

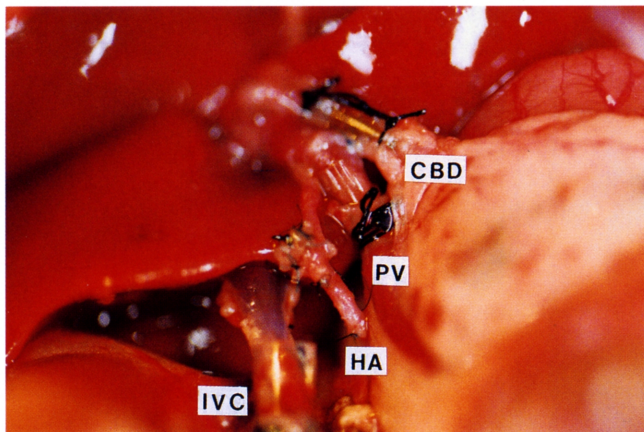
### Surgical Procedures:

Orthotopic LT were carried out using the 2-cuff method by Kamada et al. (11). HA was microscopically reconstructed, using "Sleeve's method". Briefly, the

donor's celiac artery was anastomosed to recipient's common HA. One stitch was given with an 8-0 nylon suture material to approximate the both arteries. And, two stitches were added to complete the anastomosis. The scheme of our method for vascular reconstruction (Fig.1) and photo of completed arterial reconstruction (Fig.2) are shown. Anastomosis of HA was done by one of the authors (K.T.) and it took approximately 14 minutes to complete it. Reconstruction of the portal vein was made by cuff method and bile duct was anastomosed by use of the stent tube.



**Fig. 1.** Technique for vascular reconstruction in rat liver transplantation.



**Fig. 2.** Photo of the completed reconstruction of the hepatic artery. Donor's celiac artery was anastomosed with recipient's common hepatic artery. CBD; common bile duct, PV; portal vein, HA; hepatic artery, IVC; inferior vena cava

#### Experimental Groups:

Rats were divided into the following 4 groups, according to the modes of LT and vascular reconstruction.

Group I (n=10): Whole LT without reconstruction of HA

Group II (n=10): Partial (30%) LT without reconstruction of HA

Group III (n=10): Whole LT with reconstruction of HA

Group IV (n=10): Partial (30%) LT with reconstruction of HA

Postoperatively, food and water were allowed to take ad libitum, and antibiotics were given for 5 days after LT.

#### Evaluation:

Complications and survival of rats after LT were carefully observed. Serum chemistries were serially monitored. When rats died, autopsy was done and the liver was submitted for histological examination. Rats survived over 100 days after LT were killed, and patency of HA in some rats of Groups III and IV was evaluated by angiography or infusion of dye (indocyanine green) immediately after sacrifice. The liver was also histologically examined.

## Results

#### Surgical results:

In Groups III and IV, 5 of the 10 rats in each were evaluated regarding the patency of HA at the time of autopsy or sacrifice. Angiography was made in 4 and infusion test of dye was done in 6. Tables 1 summarizes patency of reconstructed artery in Groups III and IV, and there was no evidence of obstruction of HA in all rats. A representative angiographic finding is shown in Fig. 3.

Survival and causes of death in rats of each Group are demonstrated in Table 2. In Group I, 9 rats survived for over 100 days, but one rat died of liver abscess on 52nd postoperative day (POD). In Group II, postoperative hemorrhage was a cause of death in one rat and bile peritonitis led to death in 2. Another rat was killed on 7th POD for histological evaluation. One rat in Group III died of postoperative bleeding and each one was killed for examination of patency of HA and pathological change of the liver on 14th and 28th POD, respectively. The remaining 7 rats survived for over 100 days. In Group IV, postoperative hemorrhage was a contributing factor for death in 3 rats. Each one rat was sacrificed for evaluation on 14th and 28th POD, respectively, and the remaining 5 rats survived for over 100 days.

In terms of the bile duct complication, accumulation of bile sludge, stone-like formation and/or the dilatation

**Table 1.** Patency of the reconstructed hepatic artery in whole and partial liver transplantation.

modes of LT	Days after LT			Total
	14	28	>100	
Whole (Group III)	1/1	1/1	3/3	5/5
Partial (Group IV)	1/1	1/1	3/3	5/5

No. of rat(s) with patent artery / No. of rat(s) having reconstruction  
LT : liver transplantation

**Table 2.** Survival and causes of death after liver transplantation.

Groups	No. of rats	Causes of death and days after LT	No. of rats survived over 100 days
I	10	1 (liver abscess, 52 days)	9
II	10	2 (bile peritonitis, 4 and 5 days) 1 (hemorrhage, 1 day) 1 (sacrifice, 7 days)	6
III	10	1 (hemorrhage, 1 day) 2 (sacrifice, 14 and 28 days)	7
IV	10	3 (hemorrhage, 1 day) 2 (sacrifice, 14 and 28 days)	5

LT: liver transplantation

**Table 3.** Complications in the biliary tract related to liver transplantation in late period.

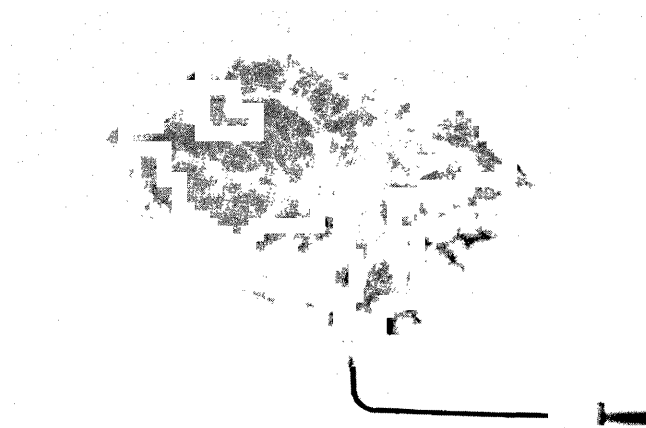
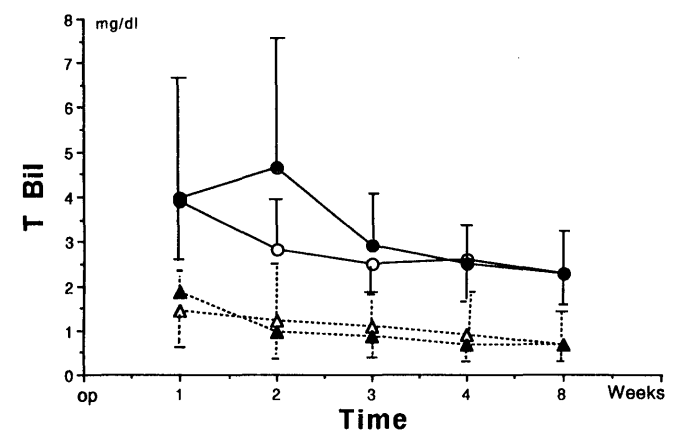
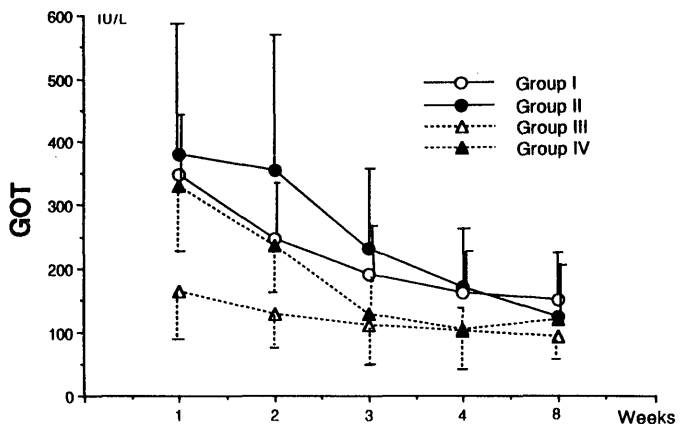
Groups	No. of rats subjected	Complications		
		Dilatation or Stenosis	Bile sludge	Abscess
I	10	6 (60%)	6 (60%)*	2 (20%)
II	7	5 (71%)	5 (71%)	nil
III	9	3 (33%)	nil	nil
IV	7	2 (29%)	nil	nil

Rats died of posttransplant hemorrhage were excluded. (\*One of 6 rats had stone formation)

or stenosis of the bile duct at the peripheral site of the inserted stent tube were noted in 60 % and 71 % of rats in Groups I and II, respectively. On the contrary, dilatation or stenosis of the bile duct was evident only in 33 % in Group III and 29 % in Group IV, and thickening of the duct wall was mild. Bile sludge was also slight in these two groups (Table 3).

*Serum chemistries:*

Mean levels of serum GOT were over 300 IU/L in Groups I, II and IV. In Group IV, levels were decreased to normal within 3 weeks after LT, whereas rats which did not have reconstruction of HA (Groups I and II) showed prolonged elevation of serum GOT levels. On the contrary, serum levels of GOT in rats, having whole LT with reconstruction of HA in Group III, were not increased even after LT. Mean serum levels of total bilirubin were almost normal in Groups III and IV. Nevertheless, those levels were elevated in Groups I and II, Particularly in Group II after LT (Fig. 4).

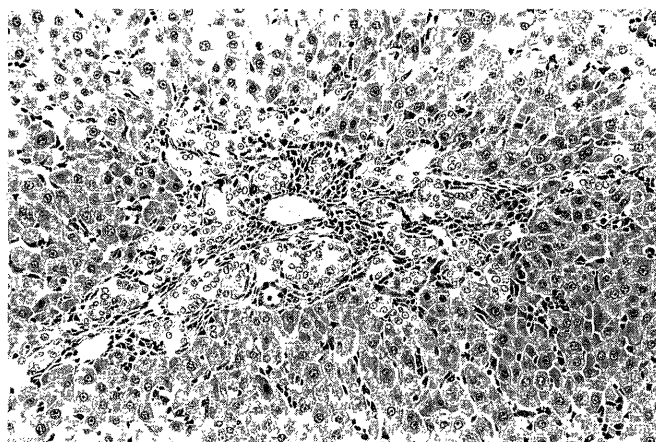


**Fig. 3.** Angiography of the grafted liver after orthotopic partial liver transplantation (319 postoperative days).

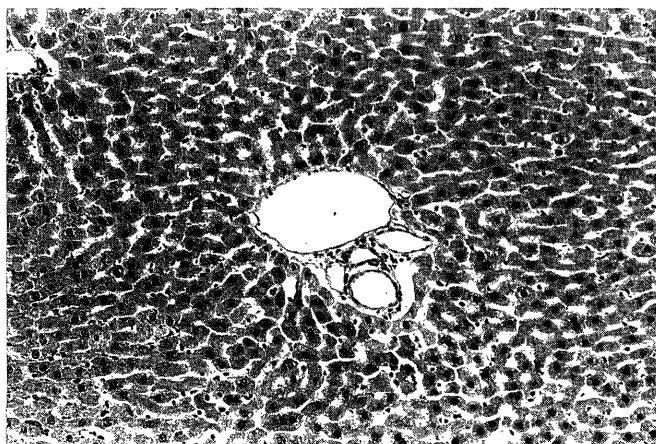
**Fig. 4.** Serial changes in serum levels of GOT and total bilirubin. T Bil: total bilirubin

### Histological examination:

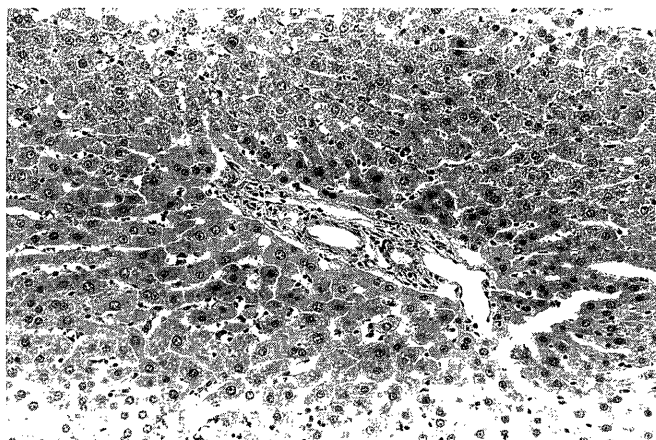
Microscopic study demonstrated that there was an evidence of remarkable proliferation of the bile duct around the portal triad in the liver of rats in Groups I and II. In particular, this finding was prominent at an early period after LT in Group II (Fig. 5a). Obstruction of the artery was also histologically evident in these groups. Contrarily, the liver in rats of Groups III and IV showed it to be in almost normal appearance and no evidence of bile duct proliferation was noted. The peripheral artery was histologically patent (Fig. 5b, c). In addition, the common bile duct showed the mucosa to be normal, although mild dilatation of the duct was observed in gross appearance.



(a)



(b)



(c)

**Fig.5.** Histological findings of the grafted liver.

- (a)-Group II : remarkable bile duct proliferation around the portal triad (7 postoperative days).  
 (b)-Group III : almost normal (316 postoperative days).  
 (c)-Group IV : almost normal (319 postoperative days).

### Discussion

The present study demonstrated that arterial blood supply to the grafted liver played an important role in maintenance of normal structure of the hepatic parenchyma and hepatocellular function in partial LT as well as whole LT. Particularly, damage against the biliary tract was found to occur when the hepatic arterial flow was occluded.

In association with the introduction of partial LT, several complications have been noted (12). Bile duct trouble, which had been one of the complications in whole LT harvesting from heart-beating cadaver, has become to be serious in pediatric patients (13, 14).

It is well known that rats undergoing LT without reconstruction of HA can tolerate the procedure well and survive for a long time. This is depended on formation of new arteries from the greater omentum at the site of anastomosis of the bile duct, which feeds the grafted liver. As shown in the present study, however, posttransplant elevation of serum bilirubin levels and increased rates of bile duct complication were evident in rats, in which reconstruction of HA was not given.

When comparison was made between whole LT and partial LT, prolonged elevation of serum levels of GOT and total bilirubin was also noted in the rat transplanted the small sized partial liver. The reasons of this delayed normalization of biochemical data were considered as follows; (I) in partial LT, the volume of the grafted liver is small and it must take a time to regenerate, (II) the drainage of the bile was disturbed by decreased bile secretion, (III) the ischemic change of the

epithelium of the bile duct because of interruption of arterial feeding.

When large animals such as porcine or canine are used in experimental study of LT, maintenance of arterial supply to the graft liver is absolutely needed. In clinical LT, it is also well known that the occluded HA leads to fetal outcome (15). Nevertheless, it was difficult to analyse exactly why interruption of blood supply gave fetal damage to the grafted liver. In rats model, animal could survive even when the reconstruction of HA was not given at the time of LT. In the present study, we successfully established microsurgical technique to reconstruct HA in whole and partial LT. Patency of the reconstructed artery was proved to be satisfactory. Using this technique, morphological and biochemical changes in the grafted liver was compared in whole and partial LT among the rats with or without reconstruction of HA. And, it was concluded that the hepatic arterial blood supply was indispensable to maintain the structure of the biliary tree at the early period, particularly in cases of partial LT.

## References

- 1) Kilpe VE, Krakauer H, Wren RE: An analysis of liver transplant experience from 37 transplant centers reported to Medicare. *Transplantation* 56:554-561, 1993.
- 2) Ghobrial RM, Yersiz H, Farmer GD, et al: Predictors of survival after in vivo split liver transplantation. *Ann Surg* 232:312-323, 2000.
- 3) Shaw BWJr, Wood RP, Stratta RJ, et al: Stratifying the causes of death in liver transplant recipients. *Ann Surg* 124:895-900, 1989.
- 4) Mora NP, Klintmalm GB, Solomon H, et al: Survival after liver transplantation in 300 consecutive patients; the influence of age, clinical status and pretransplant disease. *Transplant Proceed* 24:156-157, 1998.
- 5) Sudan DL, Shaw BWJr, Langnas AN, et al: Causes of late mortality in pediatric liver transplant recipients. *Ann Surg* 227:289-295, 1998.
- 6) Goyet DV, Hauseithner V, Reding R, et al: Impact of innovative techniques on the waiting list and results in pediatric liver transplantations. *Transplantation* 56:1130-1136, 1993.
- 7) Rela M, Vougas V, Muiesan R, et al: Split liver transplantation. King's College Hospital experience. *Ann Surg* 227:282-288, 1998.
- 8) Tanaka K, Uemoto S, Tokunaga Y, et al: Surgical techniques and innovations in living related liver transplantation. *Ann Surg* 217:82-91, 1993.
- 9) Kawasaki S, Makuuchi M, Matsunami H, et al: Living related liver transplantation in adults. *Ann Surg* 227:269-274, 1998.
- 10) Lee S, Charters C, Chandler JG, et al: A technique for orthotopic liver transplantation in the rat. *Transplantation* 16:664-669, 1973.
- 11) Kamada N, Calne R: Orthotopic liver transplantation in the rat. *Transplantation* 28:47-50, 1979.
- 12) Broelsch CE, Emond JC, Thistlethwaite JR, et al: Liver transplantation with reduced-size donor organs. *Transplantation* 45:519-523, 1988.
- 13) Heffron TG, Emond JC, Thistlethwaite JR, et al: Biliary complication in pediatric liver transplantation. *Transplantation* 53:391-395, 1987.
- 14) Zajko AB, Campbell WL, Logsdon GA, et al: Cholangiographic findings in artery occlusion after liver transplantation. *AJR* 149:485-489, 1987.
- 15) Stevens LH, Emond JC, Piper JB, et al: Hepatic artery thrombosis in infants. *Transplantation* 53:396-399, 1992.