

In-111-labeled Leukocyte Scintigraphy in Postoperative Joint Infection

Yoji OGAWA, Masataka UETANI, Aamer AZIZ, Kuniaki HAYASHI

Department of Radiology, Nagasaki University School of Medicine 1-7-1 Sakamoto, Nagasaki 852-8501, Japan

To evaluate the role of In-111-labeled leukocyte scintigraphy in the patients with suspected postoperative joint infection, 41 scintigraphic examinations were performed in 24 patients. Scintigrams were interpreted by the degree of accumulation of labeled leukocytes, and were classified into 3 groups: positive, intermediate, and negative. In the cases of positive leukocyte scans, definite diagnosis of infection was made in all cases except one. In the cases of negative scans, there was no evidence of infection. In 13 cases, leukocyte scintigrams were interpreted in conjunction with bone scintigrams. Definite diagnosis of infection was made in all of the cases with positive combined leukocyte/bone scan, and there was no evidence of infection in cases with negative combined leukocyte/bone scan. This study demonstrates that In-111-labeled leukocyte scintigraphy is a useful method in diagnosis of postoperative joint infection, and accuracy of the examination improves when combined with bone scintigraphy.

Key words: leukocyte scintigraphy, indium, Infection, orthopedic surgery

Introduction

Infection is one of the serious complications of reconstructive orthopedic procedures. Various diagnostic modalities including laboratory tests, radiography, aspiration arthrogram, and radionuclide studies have been used for the evaluation of infection. Conventional radiography, that is routinely performed in every patient with suspected postoperative infection, is not sensitive for early-stage infection and may not always be specific. Bone scintigraphy is a highly sensitive method to detect bone and joint infection but lacks specificity.

Address Correspondence: Yoji Ogawa, M.D.

Department of Radiology, Nagasaki University School of Medicine 1-7-1 Sakamoto, Nagasaki 852-8501, Japan
TEL: +81-95-849-7354 FAX: +81-95-849-7357
E-mail: yoogawa@net.nagasaki-u.ac.jp

Detection of infection using radiolabeled leukocytes was introduced in 1970's¹⁾. Indium-111 (In-111)-labeled leukocyte imaging has been reported to be a comparatively sensitive and specific technique²⁾. The purpose of this study is to evaluate the role of radiolabeled leukocyte scintigraphy in the patients with suspected postoperative joint infection by comparing it with the clinical course.

Materials and Methods

Patients

Twenty-four patients (14 men and 10 women) ranging in age from 23 to 78 year (mean: 51yr) underwent scintigraphic examinations. The patients included 10 with osteoarthritis, 6 with bone tumors, 4 with femoral head osteonecrosis, and 4 others. All patients had undergone orthopedic surgery: total arthroplasty in 12, femoral head replacement in 7, and others in 5. Affected joints were hips in 17 and knees in 7. The interval between operation and scintigraphy ranged from 20 days to 3 years.

Scintigraphy

A total of 41 leukocyte scans were performed which included repeat examinations in some patients. For leukocyte separation, 40 ml of venous blood drawn from each patient was mixed with 1 ml of heparin (1000 u.). After 30 to 60 minutes of gravity sedimentation, leukocyte-rich plasma was separated. The plasma was centrifuged at 1,250 rpm for 10 minutes to remove fluid component, and then leukocytes were suspended by adding 4 milliliters of saline. Thirty-seven MBq of In-111-oxine was added, and the mixture was incubated at room temperature for 15 minutes. Subsequently, labeled leukocytes were washed with plasma and 13-20 MBq of In-111-labeled leukocytes were injected intravenously. Twenty-four hours later, whole body image and localized image of affected site were obtained using gamma camera (PRISM-2000, Picker,

U.S.A.) equipped with medium-energy collimator. In 13 patients, technetium-99m hydroxymethylene diphosphonate (Tc-99m HMDP) bone scintigraphy was also performed.

Image interpretation

In-111-labeled leukocyte images were interpreted in two ways. In the first method, the activity at affected joint was evaluated on the leukocyte scintigram alone. Scintigrams showing activity definitely greater than that of normal marrow were classified as positive. Scintigrams showing minimally increased activity compared to that of normal marrow were classified as intermediate. Scintigrams showing no evidence of in-

creased activity were classified as negative (Fig. 1).

In the second method, 15 scans performed in 13 patients who underwent both bone scintigraphy and leukocyte scintigraphy were evaluated. When the activity on leukocyte scintigram exceeded that on bone scintigram or the distribution of the two tracers was spatially incongruent, leukocyte scintigram was interpreted as positive (Fig. 2). When the distribution was congruent and activity on leukocyte scintigram did not exceed that on bone scintigram, leukocyte scintigram was interpreted as negative (Fig. 3). Scintigraphic findings were compared with clinical course after examination.




Fig. 1. Interpretation of leukocyte scintigraphy. (a) Positive. Definitely increased activity is seen in the left hip joint. (b) Intermediate. Slightly increased activity is seen in the medial part of the left acetabulum. (c) Negative. No increased activity is seen.

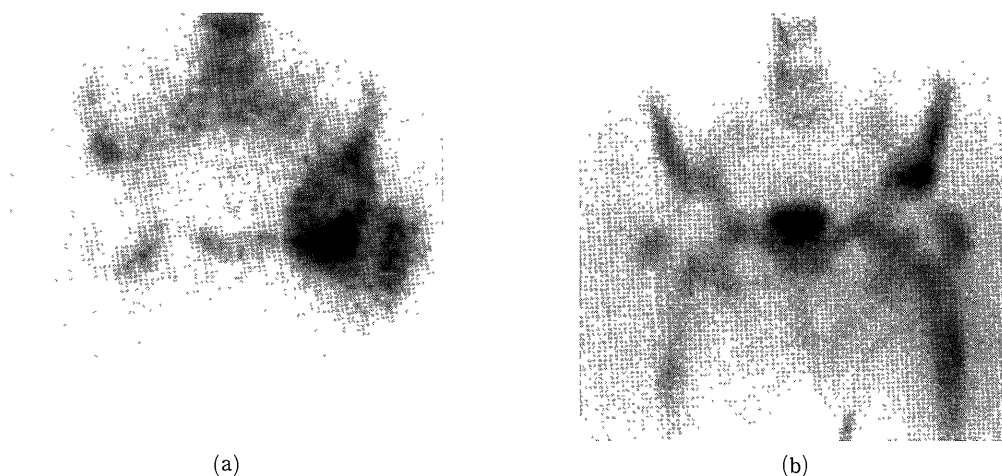


Fig. 2. Positive combined leukocyte/bone scan. The activity in the left hip joint on leukocyte scintigram (a) exceeds that on bone scintigram (b).

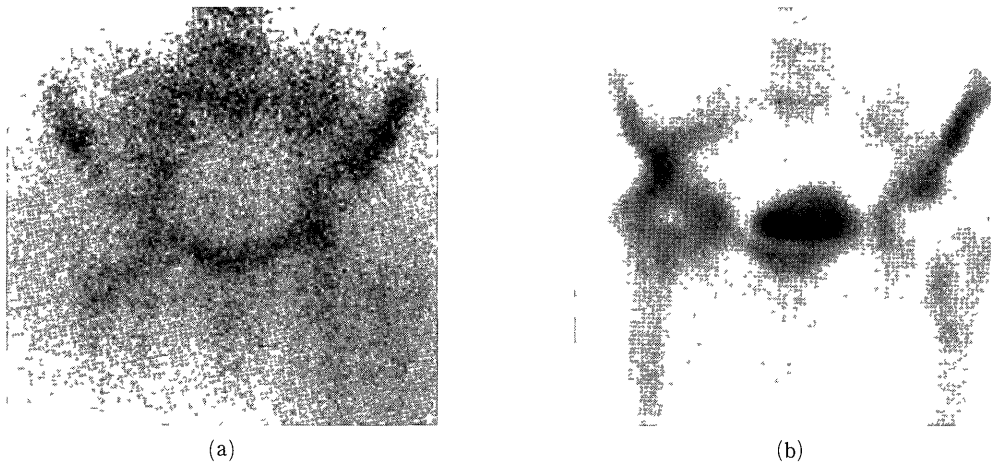


Fig. 3 Negative combined leukocyte/bone scan The activity in the right hip joint on leukocyte scintigram (a) does not exceed that on bone scintigram (b)

Results

Of 41 leukocyte scintigraphies, 13 scintigrams were interpreted as positive, 12 were interpreted as intermediate, and 16 were interpreted as negative. In the

group of positive scans, infection was confirmed by surgery or culture of aspiration fluid in 12 (Fig 4), and conservative treatment was done in 1. In the group of intermediate scans, infection was confirmed by surgery in 3, operation was performed and bacte-

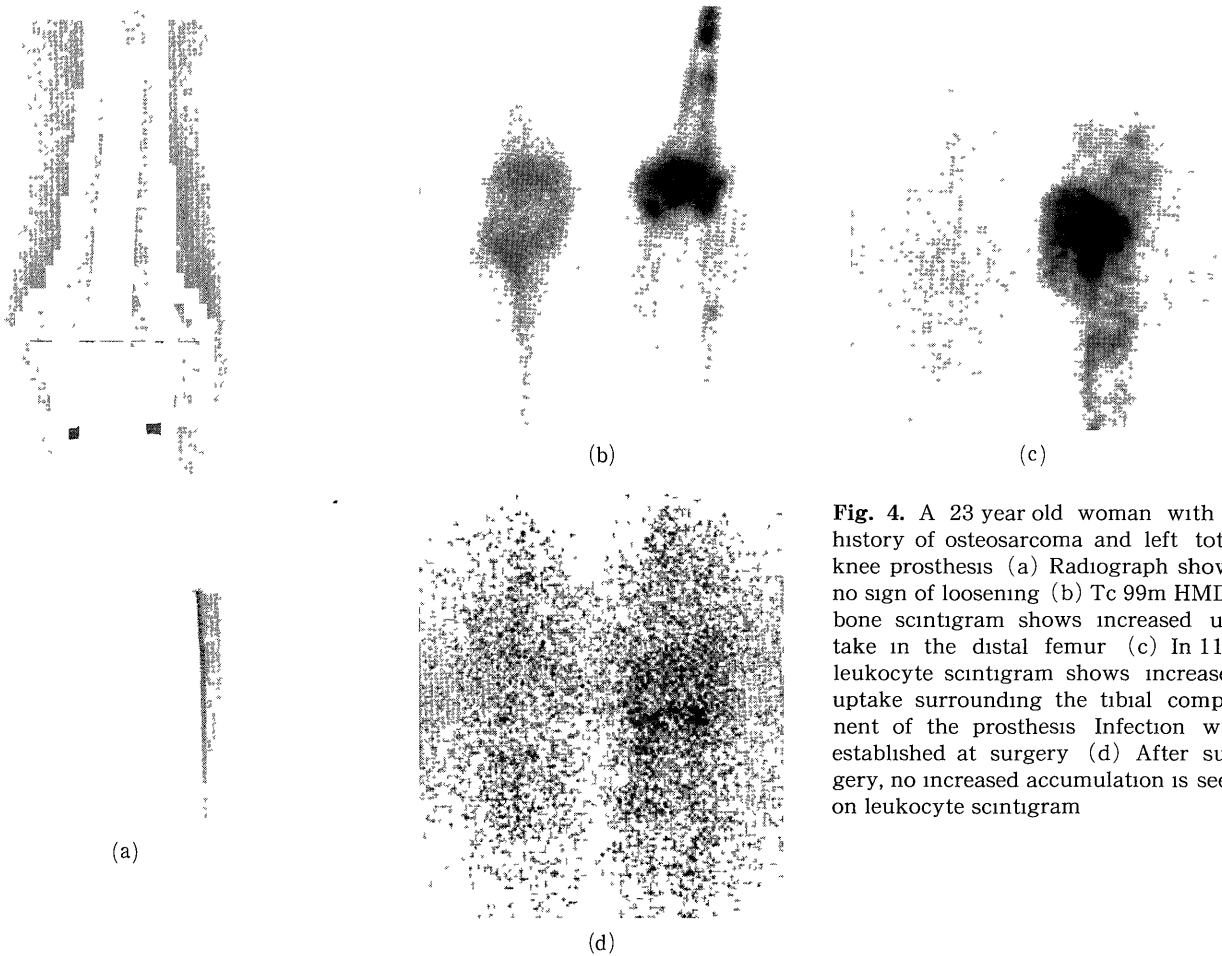


Fig. 4. A 23 year old woman with a history of osteosarcoma and left total knee prosthesis (a) Radiograph shows no sign of loosening (b) Tc 99m HMDP bone scintigram shows increased uptake in the distal femur (c) In ¹¹¹leukocyte scintigram shows increased uptake surrounding the tibial component of the prosthesis. Infection was established at surgery (d) After surgery, no increased accumulation is seen on leukocyte scintigram




Fig. 5. A 54-year-old man with a history of femoral head necrosis and bilateral femoral head prosthesis. (a) Radiograph shows loosening bilaterally and fracture in the left femur. (b) No increased uptake is seen on leukocyte scintigram. On the re-operation after scintigraphy, infection was ruled out.

Table 1. Clinical course after leukocyte scintigraphy (interpretation of leukocyte scan only)

scintigraphic findings	clinical course		
	infection (+)*	infection (-)**	conservative
positive	12	0	1
intermediate	3	2	7
negative		7	9

* confirmed by surgery or culture of aspiration fluid

** confirmed by surgery

Table 2. Clinical course after combined leukocyte / bone scintigraphy

scintigraphic findings	clinical course		
	infection (+)*	infection (-)**	conservative
positive	8	0	0
negative		4	3

* confirmed by surgery or culture of aspiration fluid

** confirmed by surgery

rial culture was negative in 2, and conservative treatment was done in 7. In the group of negative scans, operation was performed and bacterial culture was negative in 7 (Fig. 5), and conservative treatment was done in 9 (Table 1).

On the combined leukocyte scintigraphy and bone scintigraphy, 8 scans were interpreted as positive and 7 as negative. Infection was confirmed by surgery or culture of aspiration fluid in all of the cases of positive scans.

In the cases of negative scans, operation was performed and bacterial culture was negative in 4, and conservative treatment was done in 3 (Table 2).

Discussion

Nuclear medicine plays an important role in the diagnosis of postoperative joint infection. Gallium-67 (Ga-67) citrate localizes in the areas of inflammation, and Ga scanning can be used for diagnosis of infection.³⁾ The drawbacks in Ga scanning are relatively high number of equivocal results,^{4,5)} and low sensitivity.⁶⁾ In-111-labeled leukocytes accumulate at the areas of infection, and localization of the cells is specific for infection. The reported sensitivity and specificity of leukocyte scintigraphy in diagnosing orthopedic prosthesis infection is 88 to 100%, and 50 to 75%, respectively.^{2, 7,8)}

In our series, sensitivity and specificity could not be calculated as the study population included patients who were treated conservatively without microbiological confirmation. In cases of positive leukocyte scans, definite diagnosis of infection was made in all except one. In the cases of negative scans, there was no evidence of infection. Our data demonstrates that leukocyte scintigraphy is an accurate method for diagnosis of postoperative joint infection when the results of the study are either positive or negative.

In our group of intermediate leukocyte scans, there were both infected cases and uninfected cases. Leukocyte scintigraphy is considered to be less useful when interpreted as intermediate. Some authors proposed various dual-tracer modalities to improve the accuracy of

infection. Palestro et al. have reported that the specificity and accuracy of combined leukocyte scintigraphy and sulfur colloid bone marrow scintigraphy (100%, 95%, respectively) was higher than that of leukocyte scintigraphy alone (75%, 78%, respectively).⁷⁾ Johnson et al. have reported that the specificity of leukocyte scan was dramatically improved (50% to 95%) when correlated with bone scintigraphy and read as sequential leukocyte/bone imaging.⁸⁾ In our series, definite diagnosis of infection was made in all the cases of positive combined leukocyte/bone scan, and there was no evidence of infection in the cases of negative combined leukocyte/bone scan. Although the number of patients is not enough in our series, our results agree with the study of Johnson et al.⁸⁾

There are some disadvantages of In-111-labeled leukocyte for infection imaging. Radiation dose for scintigraphy is high, and In-111-oxine is not always be available. To overcome these disadvantages, a new technique for labeling leukocytes with Tc-99m hexamethylpropylene amine oxime (HMPAO) has been developed.⁹⁻¹¹⁾ In Tc-99m HMPAO-labeled leukocyte scintigraphy, higher injectable radioactivity allows better quality of the images. Tc-99m HMPAO is readily available as a kit. However, In-111-labeled and Tc-99m-HMPAO-labeled leukocytes would be expected to have similar results for diagnosis of bone infection.⁹⁾

In conclusion, In-111-labeled leukocyte scintigraphy is a useful method in the diagnosis of postoperative joint infection, and accuracy of the examination improves in combination with bone scintigraphy.

References

- 1) McAfee JG, Thakur ML: Survey of radioactive agents for in vitro labeling of phagocytic leukocytes. I. Soluble agents. *J Nucl Med* 17: 480-487, 1976
- 2) Magnuson JE, Brown ML, Hauser MF, Berquist TH, Fitzgerald RH, Klee GG: In-111-labeled leukocyte scintigraphy in suspected orthopedic prosthesis infection: Comparison with other imaging modalities. *Radiology* 168: 235-239, 1988
- 3) Williams F, McCall IW, Park WM, O'Connor BT, Morris V: Gallium-67 scanning in the painful total hip replacement. *Clin Radiol* 32: 431-439, 1981
- 4) Palestro CJ, Torres MA: Radionuclide imaging in orthopedic infections. *Semin Nucl Med* 27: 334-345, 1997
- 5) Weissman BN: Current topics in the radiology of joint replacement surgery. *Radiol Clin North Am* 28: 1111-1134, 1990
- 6) Aliabadi P, Tumeh SS, Weissman BN, McNeil BJ: Cemented total hip prosthesis: Radiographic and scintigraphic evaluation. *Radiology* 173: 203-206, 1989
- 7) Palestro CJ, Swyer AJ, Kim CK, Goldsmith SJ: Infected knee prosthesis: Diagnosis with In-111 leukocyte, Tc-99m sulphur colloid, Tc-99m MDP imaging. *Radiology* 179: 645-648, 1991
- 8) Johnson JA, Christie MJ, Sandler MP, Parks, Jr.PF, Homra L, Kaye JJ: Detection of occult infection following total arthroplasty using sequential technetium-99m MDP bone scintigraphy and indium-111 WBC imaging. *J Nucl Med* 29: 1347-1353, 1988
- 9) Schauwecker DS: The scintigraphic diagnosis of osteomyelitis. *Am J Roentgenol* 158: 9-18, 1992
- 10) Rosas MH, Leclercq S, Pegoix M, et al: Contribution of laboratory tests, scintigraphy, and histology to the diagnosis of lower limb joint replacement infection. *Rev Rhum [Engl.Ed.]* 65: 477-482, 1998
- 11) Kanegae K, Itoh K, Tsukamoto E, Nagao K, Nakada K, Hurudate M: Diagnosis of infected bone and joint diseases with Tc-99m-HMPAO labeled leukocytes. *Kakuigaku* 29: 269-275, 1992