

Antineutrophil Cytoplasmic Antibody-associated Vasculitis Complicating Graves' Disease: Report of Two Adult Cases

Nobuko SERA, Naokata YOKOYAMA, Yasuyo ABE, Akane IDE, Toshirou USA, Tan TOMINAGA, Eri EJIMA, Atsushi KAWAKAMI, Kiyoto ASHIZAWA, Katsumi EGUCHI

First Department of Internal Medicine, Nagasaki University School of Medicine,

Two adult female patients with established Graves' disease were treated with propylthiouracil (PTU). One patient developed agranulocytosis, high fever of unknown origin and bilateral episcleritis. Another patient reported repeated attacks of common cold-like symptoms, polyarthralgia and skin purpura. There was no hematuria or proteinuria. Administration of PTU was withdrawn following identification of high myeloperoxidase-antineutrophil cytoplasmic antibody (MPO-ANCA) titer in the serum. Without steroids or immunosuppressive therapy, symptoms improved gradually in association with a fall in serum MPO-ANCA titer. We speculated that the symptoms of our two cases were due to MPO-ANCA associated vasculitis. MPO-ANCA positive vasculitis and glomerulonephritis are rare complications of PTU therapy, however, when these occur, the condition may become serious. Patients with Graves' disease treated with PTU should be carefully observed during therapy.

Key words: myeloperoxidase-antineutrophil cytoplasmic antibody (MPO-ANCA), vasculitis, propylthiouracil (PTU), Graves' disease

Introduction

Graves' disease is a common autoimmune disorder and can usually be controlled by antithyroid drugs, such as methimazol (MMI) and propylthiouracil (PTU). However, these drugs have several adverse effects such as skin eruption, liver dysfunction, agranulocytosis. Antineutrophil cytoplasmic antibody (ANCA) is an important serological marker for systemic vasculitic disorders. Recently, few studies reported that patients

with Graves' disease treated by PTU might develop ANCA-positive vasculitis or crescentic glomerulonephritis (1-5). We report two patients with Graves' disease who had high serum titers of ANCA and developed vasculitis-like disorders during PTU therapy.

Case reports

Case 1

Diagnosis of Graves' disease was established in a 46-year-old woman at the age of 22 years following presentation with tremors, weight loss and palpitation. She was treated with MMI but it was withdrawn two years later because of normalization of thyroid function after delivery. At the age of 26, she became pregnant again and developed a relapse of hyperthyroidism during the first trimester. Accordingly, she was treated with 300 mg of PTU. Treatment with PTU was continued for 10 years, followed by a remission for 9 years. At that stage, she noticed general malaise, weight loss, tremor and pretibial edema, which were later confirmed to be due to a relapse of hyperthyroidism. She was treated again with 150 mg PTU, but two weeks later she developed high fever, which continued for 11 days in spite of continued medication with antibiotics and anti-inflammatory drugs. At that stage, severe leukocytopenia (700 cells/ml) was noted, and accordingly she was referred and admitted to our hospital.

On clinical examination, heart rate was 118 beats/min and blood pressure 120/70 mmHg. The thyroid gland was diffusely enlarged on both sides and soft on palpation. Chest auscultation identified a systolic heart murmur. Finger tremor and pretibial edema were noted. Laboratory data on admission showed severe leukocytopenia (800/ml) and moderate anemia (Table 1). Examination of a bone marrow smear showed hypercellular marrow, predominantly containing plasma cells and cells of erythrocyte

Address Correspondence: Katsumi Eguchi, M.D.

First Department of Internal Medicine, Nagasaki University School of Medicine, 1-7-1, Sakamoto, Nagasaki 852-8501, Japan
TEL: +81-95-849-7268 FAX: +81-95-849-7270

Table 1. Laboratory data on admission (Case 1)

WBC (3600-8500)	800/ μ l	IgG (972-2010)	237IU/ml	urine	
RBC (3.9-5.0x10 ⁴)	426x10 ⁴ / μ l	IgA (90-445)	185IU/ml	blood	negative
Hb (11.0-14.5)	10.8g/dl	IgM (67-359)	318IU/ml	protein	negative
Plt (15.0-38.0)	19.8x10 ⁴ / μ l	CH50 (20-60)	37.7 μ g/ml	sugar	negative
T.P (6.2-8.0)	7.0g/dl	ANA (negative)	negative	cast	negative
Alb (3.8-4.9)	3.1g/dl	anti-dsDNAAb (negative)	24x		
BUN (8.0-12.0)	12mg/dl	FT ₃ (2.7-4.5)	3.7pg/ml		
Cr (0.3-1.0)	0.7mg/dl	FT ₄ (1.0-1.8)	1.7ng/ml		
CRP (<0.17)	13.6mg/dl	TSH (0.3-3.2)	<0.01 μ U/ml		
PT (82-127)	49%	TRAb (<10)	0.10%		
APTT (25.2-34.4)	39.2s	MPO-ANCA (<10)	143EU		
Fbg (168-329)	774mg/dl	C-ANCA (<10)	13EU		

TRAb; TSH-receptor antibody, MPO-ANCA; myeloperoxidase C-ANCA; anti-neutrophilic cytoplasmic antibody,

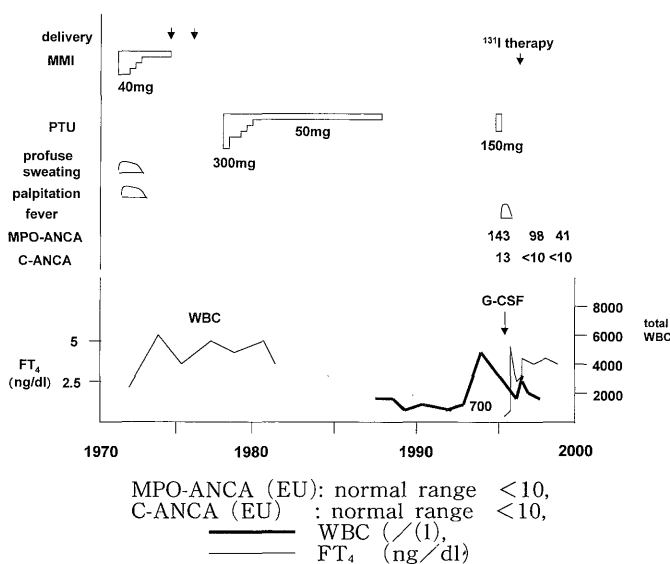
series. Serum thyroid hormone concentrations were normal and both anti-thyroglobulin and microsome antibodies were negative, but CRP was high. Urinalysis showed no protein, cells, or casts. The chest radiograph was negative but marked splenomegaly was noted on abdominal ultrasonography. Serum titer of myeloperoxidase-ANCA (MPO-ANCA) was high (143 EU) by ELISA (cut off value<10), and cytoplasmic-ANCA (C-ANCA) was 13 EU (cut off value<10) (Fig. 1).

weeks after withdrawal of PTU, associated with a fall in MPO-ANCA titer without steroids or immunosuppressive therapy. The patient was also found to have bilateral episcleritis on admission. Episcleritis is an important sign from vasculitis. For this reason, it was assumed that the high fever and bilateral episcleritis were due to MPO-ANCA associated vasculitis. Her symptoms and signs were spontaneously disappeared after withdrawal of PTU therapy. ¹³¹I therapy was administered for Graves' disease and MPO-ANCA fell to 41 EU after 3 years.

Case 2

Graves' disease was diagnosed in a 38-year-old woman after she consulted her family physician for palpitation, excessive sweating and diarrhea. At that time, thymoma was noticed on chest CT examination. The patient was treated with methimazol (MMI) first. As skin eruption appeared soon after therapy, and accordingly MMI was replaced with PTU. The symptoms improved with the return of thyroid function to the normal range. However, the patient complained of frequent attacks of sore throat, cough and hemoptum 8 months later in spite of euthyroid state. Lung fields were clear on chest radiograph and the patient was advised to continue with PTU medication. Fifteen months later, heart murmur and cardiomegaly were noticed, and a diagnosis of moderate aortic valve regurgitation (AR) and mild stenosis (AS) was established based on cardioechography. Operation for AR was offered but the patient refused surgery, and accordingly, ASR was followed up in our outpatient clinic. On the other hand, chest CT showed a mixed density tissue but not mass-like shadow in the anterior mediastinum, which was suspected to be thymic hyperplasia. After 2 years of PTU treatment, the patient developed arthralgia, myalgia and skin purpura. Worsening of clinical condition and remission of symptoms occurred persistently throughout a 6-month period. Thyroid hormone levels were almost within the normal range under PTU (100-200 mg/day) therapy and anti-thyroglobulin and microsome antibodies were positive (\times 1,600 and \times 102,400, respectively). Leukocyte count, CRP and CH₅₀ were normal, and rheumatoid factor and anti-ds-DNA antibody were negative. Urinalysis showed no protein, occult blood, cells, or casts. However, platelet count was slightly decreased ($13.14 \times 10^4/\mu$ l), and MPO-ANCA titer was markedly high (587 EU), C-ANCA was also above the normal range (20 EU) (Fig. 2).

Because of the high titer of MPO-ANCA, we suspected that the multitude of symptoms (common cold, arthralgia, myalgia and purpura) were due to MPO-

**Fig. 1.** Clinical course in Case 1.

PTU was withdrawn on admission because of granulocytopenia, and she was treated with antibiotics and G-CSF. This resulted in a rapid increase in leukocyte count, but the patient continued to have high fever. No infectious focus was detected in spite of several examinations. High fever, however disappeared six

ANCA associated vasculitis. Accordingly, PTU therapy was terminated and ¹³¹I therapy was initiated for Graves' disease. Vasculitis-like symptoms resolved and MPO-ANCA diminished to 254 EU two months after withdrawal of PTU therapy without steroids or immunosuppressive therapy.

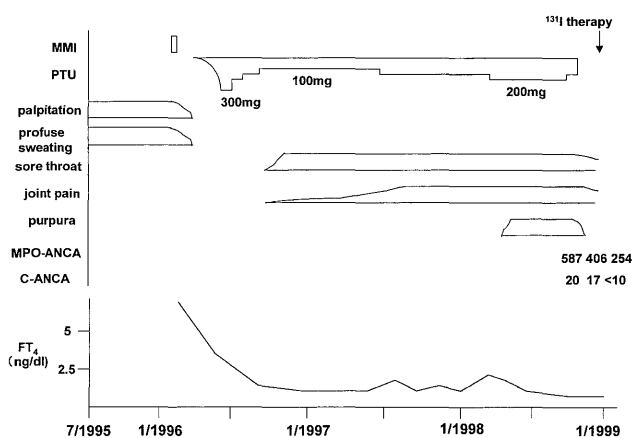


Fig. 2. Clinical course in Case 2.

Table 2. Laboratory data on admission (Case 2)

WBC (3600-8500)	7100/μl	C ₃	(42-107)	60mg/dl	urine
RBC (3.9-5.0x10 ⁶)	439x10 ⁶ /μl	C ₄	(14-40)	14mg/dl	blood negative
Hb (11.0-14.5)	12.2g/dl	RF	(negative)	negative	protein negative
Plt (15.0-38.0)	13.5x10 ³ /μl	ANA	(negative)	negative	sugar negative
T.P (6.2-8.0)	6.3g/dl	anti-dsDNAAb	(negative)	negative	cast negative
Alb (3.8-4.9)	4.0g/dl	FT ₃	(2.7-4.5)	2.8pg/ml	
BUN (8.0-12.0)	17mg/dl	FT ₄	(1.0-1.8)	1.0ng/ml	
Cr (0.3-1.0)	0.7mg/dl	TSH	(0.3-3.2)	0.82 μU/ml	
CRP (<0.17)	0.21mg/dl	TSAb	<<180%	112%	
IgG (972-2010)	2371IU/ml	MPO-ANCA	<<10	143EU	
IgA (90-445)	185IU/ml	C-ANCA	<<10	13EU	
IgM (67-359)	318IU/ml				

Discussion

ANCA was first detected in patients with necrotizing crescentic glomerulonephritis (NCGN). ANCA has also been reported in Wegener granulomatosis and microscopic polyarteritis. The target antigens of the most common ANCA are proteinase 3 (PR3) and MPO. Anti-PR3 is associated with Wegener's granulomatosis, while anti-MPO occurs predominantly in patients with NCGN.

Vasculitis is an uncommon complication of PTU treatment. Dolman *et al.* (1) were the first group to report the concept of ANCA-associated vasculitis induced by PTU. In addition, ANCA related crescentic

glomerulonephritis was reported as a severe complication of treatment with PTU (2, 3). Although common adverse effects usually arise within several weeks of initiation of PTU therapy, vasculitis may develop after several months or even years of therapy (4). Fever, arthralgia, myalgia, common cold-like symptoms, hematuria, proteinuria and skin lesions may be common findings in vasculitis. Episcleritis is also one of important ocular complications from vasculitis (5, 6). Several studies have described the association between PTU and ANCA-associated vasculitis. Vasculitis associated with PTU may affect any organ with skin lesions being the most common. Skin lesions are often of purpuric type but pain and necrotic ulceration may occur. Based on the clinical presentation and course, our two cases are similar to those reported by Dolman *et al.* (1).

MPO-ANCA has been recently suggested to play a role in the pathogenesis of vasculitis and ANCA have been implicated in the development of tissue damage in vasculitis or glomerulonephritis (8, 9). Possible mechanisms include activation of primed neutrophils to degranulate and to produce oxygen radicals, and interference by ANCA of MPO enzyme activity. Moreover, several cytokines (IL-1, 6, 8) are thought to be involved in the pathogenesis of vasculitis. On the other hand, the mechanism of MPO-ANCA synthesis remains unknown. Production of MPO-ANCA is thought to occur through a direct effect of PTU itself or its metabolites. Others have suggested that the onset of this complication may be part of the autoimmune process of Graves' disease or because anti-thyroperoxidase (TPO) antibody cross-reacts with leukocyte myeloperoxidase (MPO) (11). Homology of MPO relative to TPO is reported to be 42% (10). In our two cases, Case 1 was negative and Case 2 was positive for anti-microsome antibody. In MPO-ANCA positive patients, a positive anti-microsome test has been reported in 28% of such patients, although a lack of correlation between the two antibodies has also been reported (12). In this regard, Vogt *et al.* (2) suggested that PTU changes the structure of epitope of MPO to a modified self-antigen, which is related to production of MPO-ANCA. Choi *et al.* (13) recently reported the first case of alternating ANCA types associated with PTU in a patient with preexisting C-ANCA positive Wegener' granulomatosis, which provided compelling evidence for the causal role of PTU. Appearance of ANCA in the serum has also been reported in patients treated with other drugs including hydralazine (14) and penicillamine (15) and minocycline (16). However, the mechanism of production also remains unknown. In general, most patients with MPO-ANCA associated vasculitis improve clinically as MPO-ANCA titers fall after withdrawal of

PTU provided renal involvement is limited. However, in some severe cases with vasculitis or nephritis, steroids or immunosuppressive therapy is necessary (17).

Honda *et al.* (12) reported that the positive rate of MPO-ANCA among patients with Graves' disease treated with PTU was 19.2% and 2.0% in those treated with MMI. However, all MPO-ANCA positive patients showed no symptoms of vasculitis or nephritis in their report. It is likely that interstitial pneumonitis, interstitial nephritis and polyarthritits reported as complications of PTU are related to ANCA-associated vasculitis.

In conclusion, we reported two interesting cases of MPO-ANCA positive vasculitis without renal injury in the long clinical course of Graves' disease. This complication may be facilitated by a simultaneous use of antithyroid drugs, but accumulation of similar cases is necessary to clarify the precise pathogenesis of MPO-ANCA associated vasculitis in the course of Graves' disease. Symptoms and signs related to vasculitis should be carefully followed up in Graves' patients treated with PTU.

References

- 1) Dolman KM, Gans ROB, Vervaat TJ, *et al.*: Vasculitis and antineutrophil cytoplasmic autoantibodies associated with propylthiouracil therapy. *Lancet* 342: 651-652, 1993.
- 2) Vogt B, Kim Y, Jennette J, *et al.*: Antineutrophil cytoplasmic autoantibody-positive crescentic glomerulonephritis as a complication of treatment with propylthiouracil in children. *J Pediatr* 124:986-988, 1994.
- 3) Tanemoto M, Miyakawa H, Hanai J, *et al.*: Myeloperoxidase-antineutrophil cytoplasmic antibody-positive crescentic glomerulonephritis complicating the course of Graves' disease: report of three adult cases. *Am J Kidney Dis* 774-780, 1995.
- 4) Harper L, Cockwell P, Savage COS: Case of propylthiouracil-induced ANCA associated small vessel vasculitis. *Nephrol Dial Transplant* 13: 455-458, 1998.
- 5) Sainz de la Maza M, Foster CS, Jabbur NS: Scleritis associated with systemic vasculitis disease. *Ophthalmology* 102: 687-692, 1995.
- 6) Apek EK, Uy HS, Christen W, *et al.*: Severity of episcleritis and systemic disease association. *Ophthalmology* 106: 729-731, 1999.
- 7) Aoki A, Suzuki H, Ohara T, *et al.*: A case of p-ANCA positive necrotizing vasculitis associated with Graves' disease. *Riumati (Rheumatism)* 35: 683-687 (Abstract) (In Japanese), 1995.
- 8) Arimura Y, Minoshima S, Kamiya Y, *et al.*: Serum myeloperoxidase and serum cytokines in anti-myeloperoxidase antibody-associated glomerulonephritis. *Clin. Nephrol* 40: 256-264, 1993.
- 9) Falk RJ, Jennette JC: Anti-neutrophil cytoplasmic autoantibodies with specificity for myeloperoxidase in patients with systemic vasculitis and idiopathic necrotizing and crescentic glomerulonephritis. *NEJ* 318: 1651-1657, 1988.
- 10) Asakawa H: Thyroid peroxidase (TPO) gene and pathogenic TPO mutation. *Nihonrinshou (Jap.Jour Clin Med)* 52: 864-868, (Abstract) (In Japanese) 1994.
- 11) Haapala AM, Hyoty H, Soppi E, *et al.*: Cross-reactivity between antibodies to thyroid microsomal antigens and myeloperoxidase. *Adv Exp Med Bio* 336: 81-85, 1993.
- 12) Honda H, Shibata T, Sugisaki T, Hara H, Ban Y: MPO-ANCA in patients with Graves' disease: strong association with propylthiouracil (PTU) therapy. *Sarcoidosis* 13: 280, 1996.
- 13) Choi HK, Merkel PA, Tervaert JWC, *et al.*: Alternating antineutrophil cytoplasmic antibody specificity. *Arthritis Rheum* 42: 384-388, 1999.
- 14) Short AK, Lockwood CM: Antigen specificity in hydralazine associated ANCA positive systemic vasculitis. *Quart J Med* 88: 775-783, 1995.
- 15) Gaskin G, Thompson EM, Pusey CD: Goodpasture-like syndrome associated with antimyeloperoxidase antibodies following penicillamine treatment. *Nephrol Dial Transplant* 10: 1925-1928, 1995.
- 16) Eklayam O, Yaron M, Caspi D: Minocycline induced arthritis associated with fever, livedo reticularis, and pANCA. *Ann Rheum Dis* 55: 769-771, 1996.
- 17) Haubitz M, Schellong S, Gobel U, *et al.*: Intravenous pulse administration of cyclophosphamide versus daily oral treatment in patients with antineutrophil cytoplasmic antibody-associated vasculitis and renal involvement. *Arthritis Rheum* 41: 1835-1844, 1998.