

Low-Dose and Long-Term 14-Member Macrolide Therapy for Palmoplantar Pustulosis

Yoshitaka MATSUNAGA¹⁾, Sangjae BAE¹⁾, Tomio AKIYAMA¹⁾, Jun-Ichi KADOTA²⁾, Ichiro KATAYAMA¹⁾

1) Department of Dermatology, Nagasaki University School of Medicine

2) Second Department of Internal Medicine, Nagasaki University School of Medicine

We investigated the clinical efficacy of low-dose and long-term 14-member macrolide therapy for 33 patients with Palmoplantar Pustulosis (PPP) most of whom showed a poor clinical response to topical corticosteroid and/or photo chemotherapy. After 4-12 weeks treatment with oral erythromycin (EM; 600mg/day) or clarithromycin (CAM; 200 mg/day) in combination with previously used corticosteroid ointment, clinical evaluation was made on the basis of clinical score. Results are as follows: marked improvement; 19 patients (57.6%), moderate improvement; 7 patients, no clinical response; 7 patients. There was no serious side effect during the observation period. In vitro studies suggest that CAM, a 14-member macrolide, significantly down-regulated IL-8 production by keratinocytes stimulated with combination of IFN γ and TNF α or staphylococcal-superantigen (SEB) and IFN γ both at protein and mRNA levels.

We would like to propose that low-dose and long-term 14-member macrolide therapy is effective and an alternate therapy for PPP with poor response to ordinal dermatological therapy of which mechanism is presumable inhibition of neutrophil chemotaxis by inhibiting IL-8 production by keratinocytes.

Key words: palmoplantar pustulosis, macrolide, keratinocytes, IL-8

Introduction

"Low-dose and long-term" 14-member macrolide therapy has been reported as effective in diffuse panbronchiolitis (DPB)¹⁾. The prognosis of patients with DPB was very

poor, especially in cases with *Pseudomonas aeruginosa* infection in the past. However in 1987, Kudoh et al. reported that the long-term and low-dose oral administration of EM was effective in DPB²⁾. Although its precise mechanisms are not yet clear, many investigators suggest that EM and other 14-member macrolide might act as an anti-inflammatory agent rather than an anti-bactericidal one. Recently the study of its inhibitory actions on various neutrophilic inflammations has been developed rapidly and become of special interest^{2,8)}. It is reported that EM inhibits IL-8 production by cultured human bronchial epithelial cells⁸⁾.

IL-8 is one of the major chemotactic factor for neutrophils, then it is suggested that EM inhibits neutrophil infiltration by suppressing IL-8 production.

Palmoplantar pustulosis (PPP) is a common chronic skin disease characterized by sterile intraepidermal pustules and erythematous, scaly skin. In addition, PPP frequently recurs and occasionally shows some resistance to usual therapies such as topical corticosteroid or photochemotherapy. In the histopathological feature of PPP, many neutrophils infiltrate to pustules and upper dermis. And immunohistological study, lesional keratinocytes expressed IL-8. Therefore it is considered that neutrophils and IL-8 generated by keratinocytes play important roles in the etiology of PPP⁹⁾.

Focal infection such as chronic tonsillitis or dental caries play some role in the induction of PPP, since PPP occasionally improves following the treatment with them. Although the mechanisms still remain unclear, bacterial superantigen released in the circulation from focal infection site is suggested one possible candidate for induction of PPP. Superantigen binds to MHC class II molecule on antigen presenting cells or keratinocytes and induces inflammatory response by activating T cells or keratinocytes¹⁸⁾.

Therefore, in this study, we investigate the clinical efficacy of 14-member macrolide for patients with PPP

Address Correspondence: Yoshitaka Matsunaga, M.D.

Department of Dermatology, Nagasaki University School of Medicine, 1-7-1 Sakamoto, Nagasaki 852-8501, Japan

TEL: +81-95-849-7333 FAX: +81-95-849-7335

most of whom showed poor clinical response to ordinal topical corticosteroid or PUVA therapy. The action of CAM on IL-8 production by keratinocytes was examined using ELISA and RT-PCR method.

Materials and Methods

Patient population

Thirty three patients with PPP consisting of 7 males and 26 females (year range 23-73) were enrolled in this study after informed consent. The patients' profiles were summarized in table 1. Thirty one out of 33 cases showed a poor clinical response to topical corticosteroid ointment at the start of macrolide therapy. EM (600mg/day) was started on 21 cases and CAM (200mg/day) was started on 12 cases. Basal ointment which had been applied to the lesional skin was unchanged during the macrolide therapy.

After 4-12 weeks, clinical effects were evaluated on the basis of clinical score: 2+; marked improvement with more than 50% reduction of pustules and clearance of erythema, 1+; moderate improvement of erythema with less than 50% reductions of pustule, 0; no clinical response.

Reagents and antibody

CAM was provided by Taishyo Pharmaceutical Co. Ltd, Japan. For in vitro experiment, CAM powder was dissolved in dimethyl sulphoxide (DMSO; SIGMA, St. Louis, USA) and thereafter diluted in culture medium. Recombinant human tumor necrosis factor- α (TNF α) and recombinant human interferon-gamma (IFN γ) were obtained from Genzyme (Cambridge, USA). Staphylococcal enterotoxin B (SEB) was purchased from SIGMA (St. Louis, USA). Rabbit anti-human IL-8 polyclonal purified antibody ENDOGEN (Woburn, USA) was used for immunohistochemistry.

Immunohistochemistry

With the informed consent of the patients, biopsies were taken from the lesion of PPP. Frozen 6- μ m sections fixed in acetone were initially treated with 0.3% H₂O₂/methanol for blocking of internal peroxidase, and then covered with 10% normal goat serum in PBS for 1h at room temperature. After incubation with anti-human IL-8 antibody (1:200 in 5% bovine serum albumin in PBS (BSA/PBS) or normal rabbit serum (1:500 in BSA/PBS) overnight at 4°C, sections were stained with DAKO LSAB[®] 2 Kit according to the

method by manufacturer. For nucleus stain, Mayer's hematoxylin was used.

Cell culture

Primary normal human keratinocytes were purchased from NORMAL HUMAN CELL SYSTEMS (Sanko Junyaku Co. LTD, Japan). These were pooled cells derived from neonatal donors. Cells were grown in culture using a defined KGM (CC-3111, Sanko Junyaku Co. LTD, Japan) in a humidified incubator controlled at 37°C and having an atmosphere of 5% CO₂. After the third passage, the cells seeded at 1 \times 10⁵ cells/cm² in 24 wells culture cluster (Corning, NY). At confluent state, cells were cultured in serum-free medium, KBM (CC-3101, Sanko Junyaku Co. LTD, Japan) for 24h. After pre-incubation with replaced fresh KBM in the presence of CAM (0-1000ng/ml) for 1h, keratinocytes were further cultured with TNF α (250 U/ml) and IFN γ (250U/ml) or SEB (50ng/ml) and IFN γ (250U/ml) for 24h.

IL-8 determination by ELISA

IL-8 concentrations in keratinocyte culture supernatants were measured using enzyme-linked immunosorbent assay (ELISA) kit (Genzyme, Cambridge, USA). A standard curve was produced using known concentration of the recombinant human IL-8 provided in the kit. The concentration of IL-8 in the supernatants was determined from the standard curve.

RT-PCR analysis of IL-8 mRNA expression

Total RNA was extracted from the cultured keratinocytes by RNeasy Mini Kit (QIAGEN GmbH, Germany). cDNA synthesis was performed by Superscript II (Gibco BRL, Rockville, MD) according to the method by manufacturer. In short, the cycle condition is 94°C for 2 min., followed 94°C for 60 sec., 56°C for 60 sec. and 72°C for 90 sec. and 72°C for 90 sec:30 cycles for IL-8, 25 cycles for β -actin by Takara Ex Taq[™] (Takara Shuzo, Shiga, Japan). β -actin (Clontech, Palo Alto, CA) was used in this study. Synthetic oligonucleotides of human IL-8 were used (Amersham Pharmacia Biotech) as 5' IL-8 primer: ATGACTTCCAAGCTGGCCGTGGCT, and as 3' IL-8 primer: TCTCAGCCCTCTTCAAAAACCTTCTC¹⁰.

We analyzed mRNA expression of IL-8 by scanning densitometry and expressed in relation to β -actin scanning density using the NIH image program.

Statistics

The result were analyzed by student's t-test. Each value represents the mean \pm SD (n=3) . *p<0.05

Results

Macrolide therapy for PPP

Open trial of macrolide for PPP was evaluated at 4-12 weeks after the therapy. Results are as follows: marked improvement; 19 patients (57.6%) as shown in Fig. 1 and Fig. 2, moderate improvement; 7 patients, no clinical response; 7 patients (Table 2). On the basis of clinicians' and patients' assessment, more than 75% of the patients responded to macrolide therapy . Among the responded group, no recurrence of PPP was observed in 4 cases for more than three months.

There was no serious side effect except one case with transient abdominal discomfort during the observation period.

Inhibitory effect of CAM on cytokine-induced IL-8 production by keratinocytes.

Several reports have shown that keratinocyte is one of the source of IL-8 in the human skin^{11,12}. Therefore, we investigated immunohistopathological analysis and revealed the over expression of IL-8 on the lesional keratinocytes of PPP (Fig. 3). In addition, we studied whether CAM affects production of IL-8 by cytokine stimulated-keratinocytes. As shown in Fig. 4, CAM significantly down regulated IL-8 production by TNF α and IFN γ -stimulated cultured human keratinocytes in a dose-dependent manner.

CAM also down-regulated IL-8 mRNA expression in keratinocytes (Fig.5 and Fig.6).

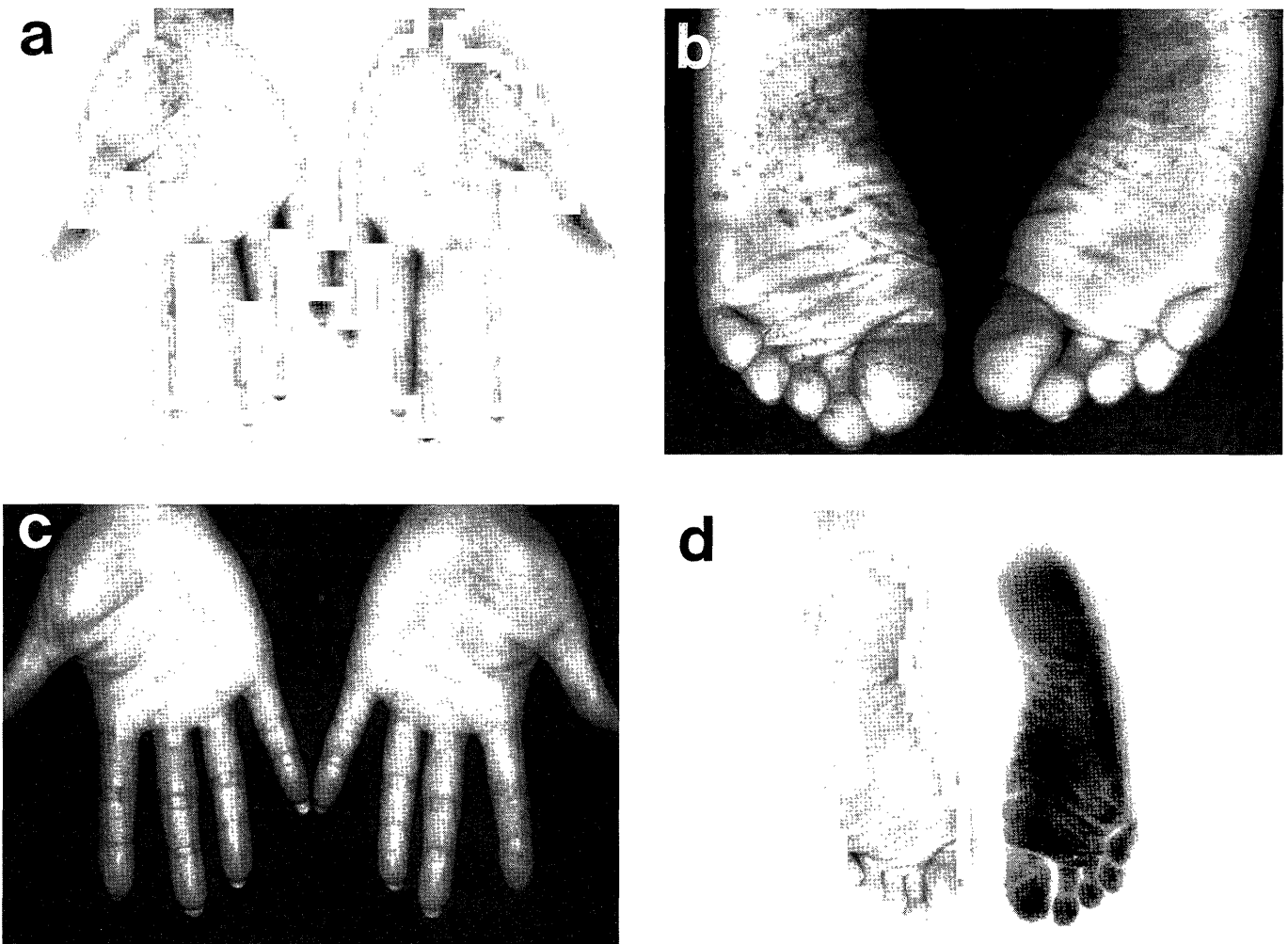


Fig. 1. Case 1 : (a), (b) before treatment and (c), (d) 6 weeks after treatment.

In this case, pustules and erythema were almost disappeared after treatment.

Inhibitory effect of CAM on superantigen-induced IL-8 production by keratinocytes.

It has been reported that focal infections such as chronic tonsillitis or caries frequently exasperate PPP and treatment of these bacterial infection clearly resolves the PPP¹³.

Therefore we analyzed the effect of superantigen-induced IL-8 production by cultured human keratinocytes. As shown in Fig. 7, CAM significantly down-regulated IL-8 production by SEB and IFN γ -stimulated cultured human keratinocytes in a dose-dependent manner. And CAM also down-regulated IL-8 mRNA expression in keratinocytes (Fig. 8 and Fig. 9).

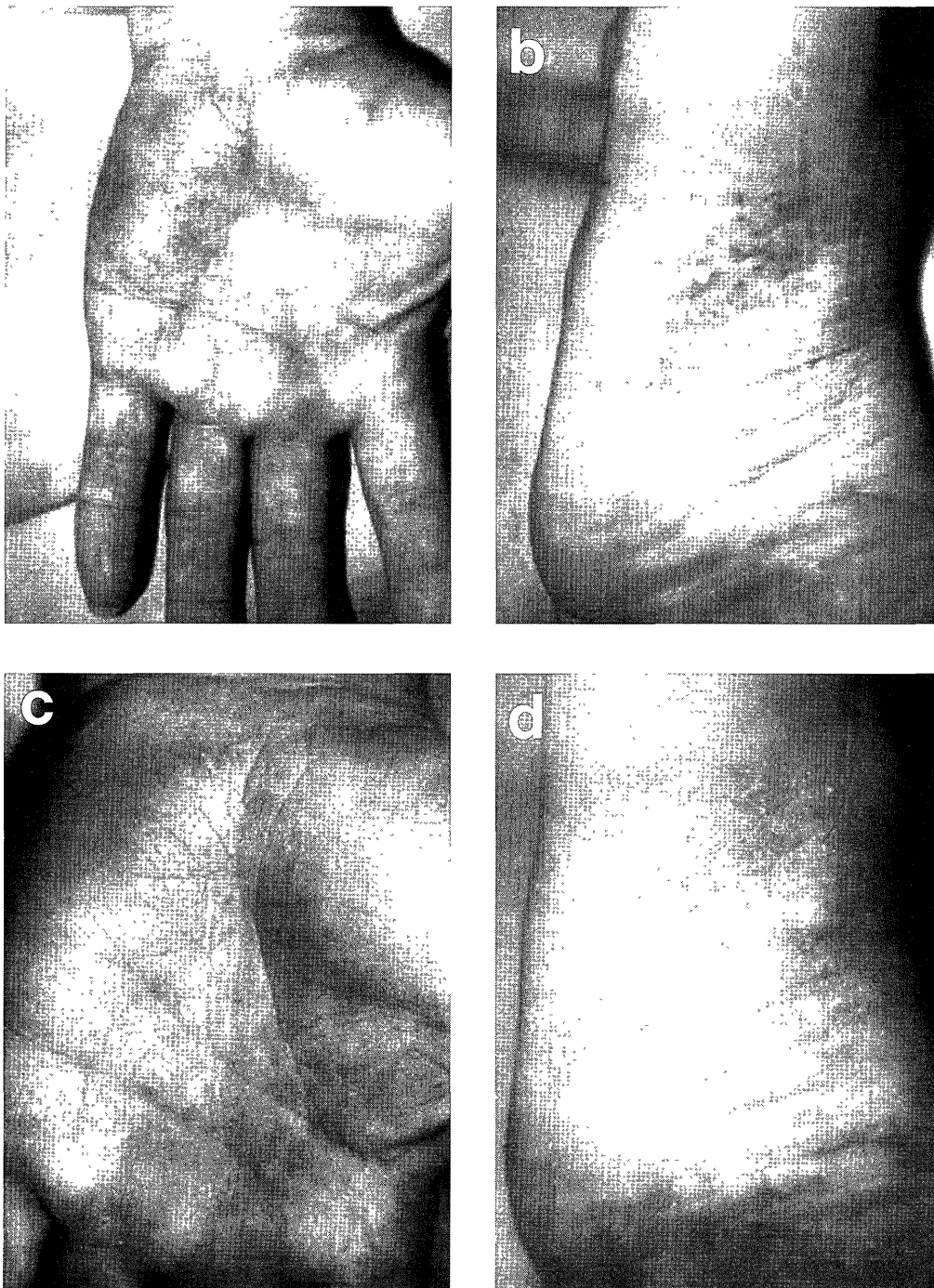


Fig. 2. (a), (b) before treatment and (c), (d) 8 weeks after treatment.

Table 1. Patients profiles enrolled in this study.

Sex	No.	Previous treatment		Focal infection		Treatment	
		Steroid ointment	non	(+)	(-)	EM(600mg/day)	CAM(200mg/day)
M	7	7	0	3	4	6	1
F	26	24	2	4	22	15	11
Total	33	31	2	7	26	21	12

Focal infection; tonsillitis, caries EM; erythromycin CAM; clarithromycin

Table 2. Clinical response of palmoplantar pustulosis to oral macrolide.

Observation period	Result		
	2+	1+	0
1-4W	7	4	4
4-8W	4	1	3
8W<	8	2	0
Total	19 (57.6%)	7 (21.2%)	7 (21.2%)

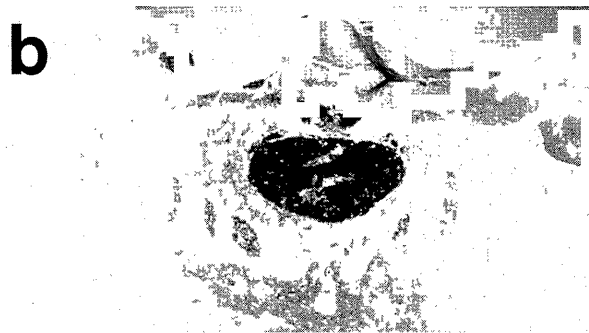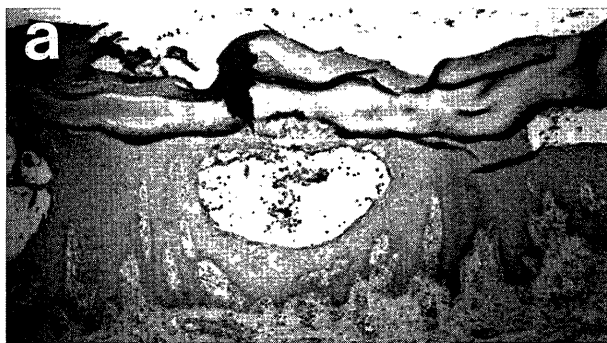


Fig 3. Immunohistopathological analysis of PPP skin lesions . (a) Control serum and (b) anti IL-8 antibody.

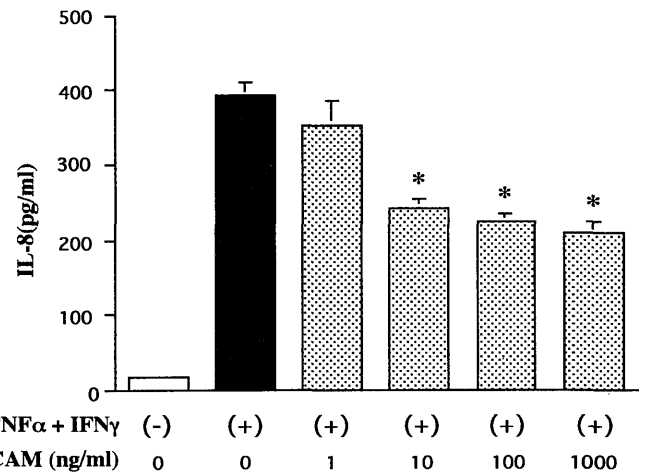


Fig 4. Inhibitory effect of CAM on cytokine-induced IL-8 production by keratinocytes. Each value represents the mean ± SD (n=3) . *p<0.05




Fig 5. Inhibitory effect of CAM on cytokine-induced IL-8 mRNA expression in keratinocytes.

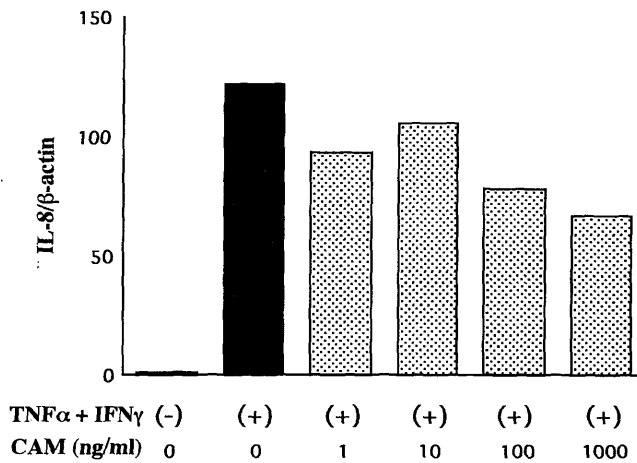


Fig 6. The values were determined by scanning densitometry and expressed cytokine-induced IL-8 mRNA in relation to β-actin scanning density with NIH image.

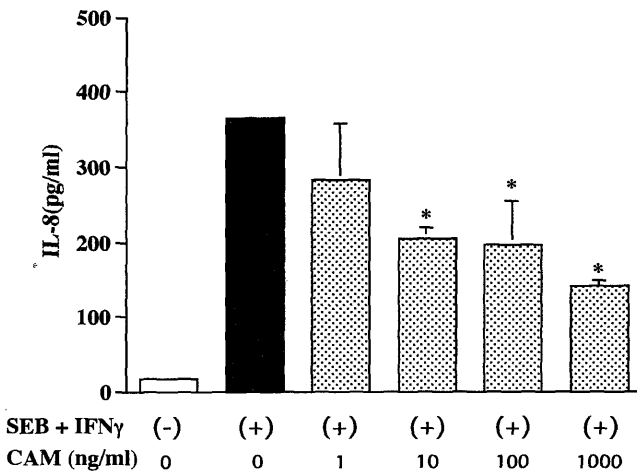


Fig 7. Inhibitory effect of CAM on superantigen-induced IL-8 production by keratinocytes. Each value represents the mean ± SD (n=3). *p<0.05

Discussion

Low-dose and long-term oral macrolide therapy significantly improved the refractory PPP which had been treated with potent topical corticosteroid with unfavorable results. More than 75% of the patients responded to macrolide therapy. Clinical effect was objectively recognized shortly after the start of the therapy (1-2 weeks) and patients' evaluations were favorable after the therapy (4-12 weeks). Four patients did not recur even 3 months after the therapy.

Macrolide therapy applied in this communication was initially studied in the patients with diffuse panbronchiolitis (DPB) with favorable clinical effect². DPB is characterized by chronic inflammation, localized predominantly in the respiratory bronchioles, with infiltration of inflammatory cells¹. The clinical features of




Fig 8. Inhibitory effect of CAM on superantigen-induced IL-8 mRNA expression in keratinocytes.

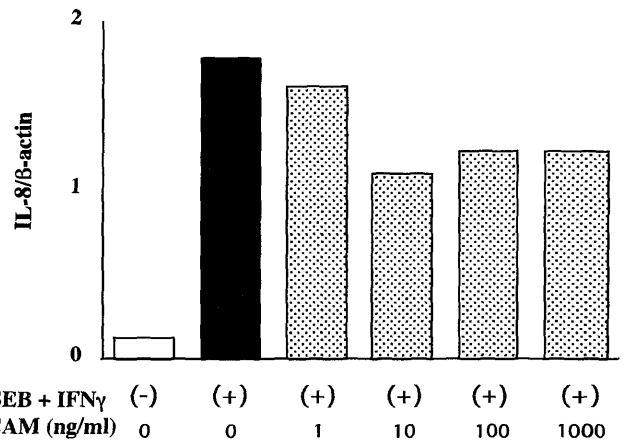


Fig 9. The values determined by NIH image showed that inhibitory effect of CAM on superantigen-induced IL-8 mRNA expression.

DPB are chronic or continuous pulmonary infection and inflammation. The prognosis of patients with DPB was very poor, especially in cases with *P.aeruginosa* infection in the past. In 1987, Kudoh et al. reported that the long-term and low-dose oral administration of EM was effective in chronic lower respiratory tract diseases, including DPB². Its precise mechanisms are not yet clear, but many investigators suggest that EM might act as an anti-inflammatory agent rather than an antibactericidal one^{3,7}. And the study of its inhibitory actions on neutrophilic inflammation has developed rapidly and become of special interest⁸. It is reported that EM inhibits IL-8 production by cultured human bronchial epithelial cells⁸. IL-8 is one of the major chemotactic factor for neutrophils, then it is suggested that EM inhibits neutrophils infiltration by suppressing IL-8 production. Similar efficacy was observed with other 14-member macrolide drug, CAM as reported in this communication.

PPP is a common chronic skin disease, which occasionally shows poor response to usual dermatological therapy such as topical corticosteroid or photochemotherapy¹⁴. Acute exacerbation after focal infection such as tonsillitis or periodontal diseases is occasionally observed in a similar manner to acute generalized pustular bacterid¹⁵. PPP is characterized by sterile intraepidermal pustules with neutrophilic infiltration which is considered to play an important role in the etiology of PPP¹⁶. And it is reported that intercellular epidermal IL-8 immunolabeling was regularly detected in lesional biopsies in PPP, but not in healthy subjects or non-lesional skin in PPP¹². Therefore it is considered that neutrophils and IL-8 generated by keratinocytes play important roles in the pathogenesis of PPP⁹.

These clinical and histopathological findings suggest that bacterial factors might be involved in activation of neutrophils through affecting immune system. Bacterial superantigens such as streptococcal pyrogenic exotoxin A (SPE A), or SEB activate T cells resulting in production of neutrophil activating cytokines¹⁷. In addition, superantigens induce TNF α or IL-1 α by human keratinocytes in the presence¹⁸ or absence of MHC class II molecule expression¹⁹. In this study, we showed that SEB also induces IL-8 production by keratinocytes. Involvement of other neutrophilic chemokines such as MIP1 α , MIP1 β , or NAP2 should be clarified in the future study.

Our results showed that 14-member macrolide significantly down-regulated the IL-8 production by cytokine or SEB stimulated keratinocytes might explain the one aspect of clinical effect of macrolide therapy or refractory PPP. Although colchicine²⁰ or clofazimine²¹ have been known to be effective for PPP through inhibition of chemotactic or bactericidal activity of neutrophils, these drugs are not widely used for their serious side effects.

Taken together, 14-member macrolide therapy would be more safe and effective therapy for PPP especially for the refractory and uncontrolled patients with usual dermatological therapies.

References

- 1) Homma H, Yamanaka A, Tanimoto S, et al. Diffuse panbronchiolitis: a disease of transitional zone of the lung. *Chest* 83:63-9, 1983.
- 2) Kudoh S, Uetake T, Hagiwara K, et al. Clinical effect of low-dose long-term erythromycin chemotherapy on diffuse panbronchiolitis. *Jpn J Thorac Dis* 25:632-42, 1987.
- 3) Ichikawa Y, Ninomiya H, Koga H, et al. Erythromycin reduces neutrophils and neutrophil-derived elastolytic-like activity in the lower respiratory tract of bronchiolitis patients. *Am Rev Respir Dis* 146:196-203, 1992.
- 4) Kadota J, Sakito O, Kohno S, et al. A mechanism of erythromycin treatment in patients with diffuse panbronchiolitis. *Am Rev Respir Dis* 147:153-9, 1993.
- 5) Kawakami K, Kadota J, Iida K, et al. Phenotypic characterization of T cells in bronchoalveolar lavage fluid (BALF) and peripheral blood of patients with diffuse panbronchiolitis; the importance of cytotoxic T cells. *Clini Exp Immunol* 107:410-6, 1997.
- 6) Aoshiba K, Nagai A, Konno K. Erythromycin shortens neutrophil survival by accelerating apoptosis. *Antimicrobial Agents Chemother* 39:872-7, 1995.
- 7) Mitsuyama T, Tanaka T, Hidaka K, et al. Inhibition by erythromycin of superoxide anion production by human polymorphonuclear leukocytes through the action of cyclic AMP-dependent protein kinase. *Respiration* 62:269-73, 1995.
- 8) Khair OA, Devalia JL, Abdelaziz MM, et al. Effect of erythromycin on Haemophilus influenzae endotoxin-induced release of IL-6, IL-8 and sICAM-1 by cultured human bronchial epithelial cells. *European Respiratory Journal*. 8:1451-7, 1995.
- 9) Ternowitz T, Thestrup-Pedersen K. Neutrophil and monocyte chemotaxis in pustulosis palmo-plantaris and pustular psoriasis. *Br J Dermatol* 113:507-13, 1985.
- 10) Lupetti R, Mortarini R, Panceri P, et al. Interaction with fibronectin regulates cytokine gene expression in human melanoma cells. *International Journal of Cancer*. 66:110-6, 1996.
- 11) Takematsu H, Isono N, Kato T, et al. Normal human epidermal keratinocyte-derived neutrophil chemotactic factor. *Tohoku Journal of Experimental Medicine*. 162:1-13, 1990.
- 12) Anttila HS, Reitamo S, Erkkö P, et al. Interleukin-8 immunoreactivity in the skin of healthy subjects and patients with palmoplantar pustulosis and psoriasis. *J Invest Dermatol*. 98:96-101, 1992.
- 13) Kataura A, Tsubota H. Clinical analyses of focus tonsil and related diseases in Japan. *Acta Oto-Laryngol (Stockh) Suppl* 523:161-4, 1996.
- 14) Enfors W, Molin L. Pustulosis palmaris et plantaris. A follow-up study of a ten-year material. *Acta Dermato-Venereologica*. 51:289-94, 1971.
- 15) Andrews G, Machacek G. Pustular bacterids of the hands and feet. *Arch Dermatol Syphil* 32:837-47, 1935.
- 16) Uehara M, Ofuji S. The morphogenesis of pustulosis palmaris et plantaris. *Arch Dermatol* 109:518-20, 1974.
- 17) Yamamoto T, Katayama I, Nishioka K. Clinical analysis of staphylococcal super antigen hyper-reactive patients with psoriasis vulgaris. *European Journal of Dermatol*. 8:325-9, 1998.
- 18) Tokura Y, Yagi J, O'Malley M. Superantigenic staphylococcal exotoxins induce T-cell proliferation in the presence of Langerhans cells or class II-bearing keratinocytes and stimulate keratinocytes to produce T-cell-activating cytokines. *J Invest Dermatology*. 102:31-8, 1994.
- 19) Matsunaga T, Katayama I, Yokozeki H, et al. Superantigen-induced cytokine expression in organ-cultured human skin. *J Dermatol Sci*. 11:104-10, 1996.
- 20) Thestrup-Pedersen K, Reymann F. Treatment of pustulosis palmaris et plantaris with colchicine. A double-blind cross-over trial. *Acta Derm Venereol*. 64:76-8, 1984.
- 21) Molin L. Clofazimine-enhanced phagocytosis in pustulosis palmaris et plantaris. *Acta Derm Venereol*. 55:151-3, 1975.