

—Case Report—

Subserosal Inflammatory Pseudotumor Causing Intussusception

Hiroshi NAGATA¹⁾, Kunihiko MURASE³⁾, Jin NISHIYAMA¹⁾, Takahisa ARAMAKI¹⁾, Shigenori MUKAI²⁾, Takaaki NAGAE²⁾, Takashi FUJIWARA²⁾, Shigeo KANAZAWA²⁾, Masaru ISHIGAKI²⁾, Hajime ISOMOTO³⁾, Fuminao TAKESHIMA³⁾, Yohei MIZUTA³⁾, Yoshikazu HIGAMI⁴⁾, Isao SHIMOKAWA⁴⁾, Ikuo MURATA⁵⁾, Shigeru KOHNO³⁾

1) Department of Internal Medicine, Mitsugi General Hospital

2) Department of Surgery, Mitsugi General Hospital

3) Second Department of Internal Medicine, Nagasaki University School of Medicine

4) First Department of Pathology, Nagasaki University School of Medicine

5) Department of Pharmacotherapeutics, Nagasaki University Postgraduate School of Pharmaceutical Science

We present an adult case of intussusception caused by subserosal inflammatory pseudotumor of the terminal ileum. Enteric intussusception was diagnosed by characteristic X-ray finding, so called “beak-like” filling defect in the terminal ileum. An exploratory laparotomy revealed focal subserosal thickening in the terminal ileum, and partial ileocectomy was performed. Microscopically, we identified a pseudotumor that extended through the muscularis propria into serosa. The pseudotumor was composed of fibrous stroma and chronic inflammatory cells with calcification.

Key words: intussusception, inflammatory pseudotumor, subserosa

Introduction

Intussusception is primarily a disease of infants and children, and is relatively rare in adults, where it is sometimes difficult to diagnose.^{1,2)} The preoperative diagnosis in the majority of patients is bowel obstruction.^{3,4)} In adults, it is usually caused by benign⁵⁻⁹⁾ or malignant neoplasms,¹⁰⁻¹³⁾ and benign lesions in the small intestine constitute half of the cases.¹⁴⁾ Inflammatory bowel lesions rarely cause intussusception.¹⁵⁻¹⁸⁾ We report here a rare adult case of intussusception caused by a subserosal inflammatory pseudotumor in the terminal ileum.

Address Correspondence: Kunihiko Murase, M.D.

Second Department of Internal Medicine, Nagasaki University School of Medicine, 1-7-1 Sakamoto, Nagasaki 852-8501, Japan
TEL: +81-95-849-7273 FAX: +81-95-849-7285

CASE REPORT

A 29-year-old male presented in September 1998 with a sudden-onset lower abdominal pain accompanied by episodes of nausea and vomiting. Past history revealed ileus one year earlier. These symptoms worsened gradually, and he was admitted to our hospital for further evaluation. On physical examination, the abdomen was flat and soft with tenderness in the lower abdomen. Laboratory data demonstrated mild anemia (hemoglobin 11.5g/dl) but other values were within normal limits.

Plain X-ray of the abdomen showed intestinal obstruction with dilated small bowel loops and air-fluid levels suggesting small bowel obstruction (Fig. 1). He

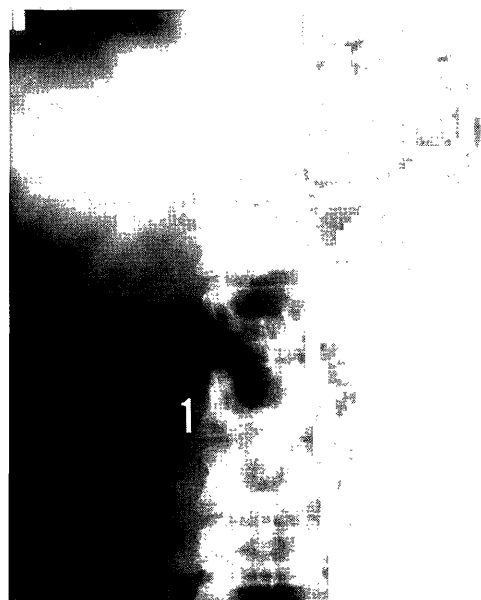


Fig. 1. Plain X-ray of the abdomen showing intestinal obstruction with dilated small bowel loops and air fluid level.

was treated by naso-jejunal tube. X-ray examination of the small intestine with gastrografin showed a "beak-like" filling defect in the terminal ileum (Fig. 2). Ultrasonography failed to show a "target-like" appearance. Abdominal CT showed cecal wall thickening (Fig. 3). Barium enema showed filling defect in the cecum (Fig. 4). Colonoscopy revealed edematous and reddish mucosa but no tumor was found in the cecum (Fig. 5), and biopsy showed no evidence of neoplasia. These findings suggested that the patient had an intussusception.

At laparotomy, the intussusception, was spontaneously

resolved but there was focal thickening of the serosa at the distal 20 cm of the terminal ileum. Therefore, partial ileocelectomy was performed to prevent a causing of recurrent ileus. Grossly, the mucosa appeared intact. Microscopically, the lesion extended through the muscularis propria into the serosa (Fig. 6A). The lesion was composed of fibrous stroma and chronic inflammatory cells including lymphocytes, plasma cells (Fig. 6B) with calcification (Fig. 6C) providing a diagnosis of inflammatory pseudotumor. Postoperative course was satisfactory, and the patient remains in good health two years after the operation.

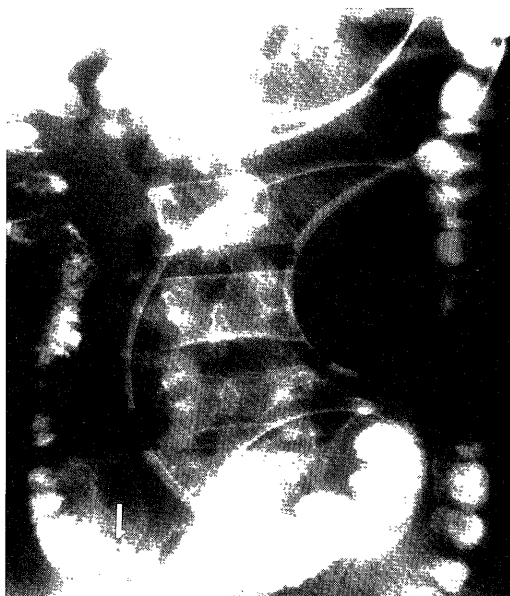

Fig. 2. X-ray examination of the small intestine with gastrografin showing the so called "beak-like" filling defect in the terminal ileum.




Fig. 3. Abdominal CT showing cecal wall thickening.

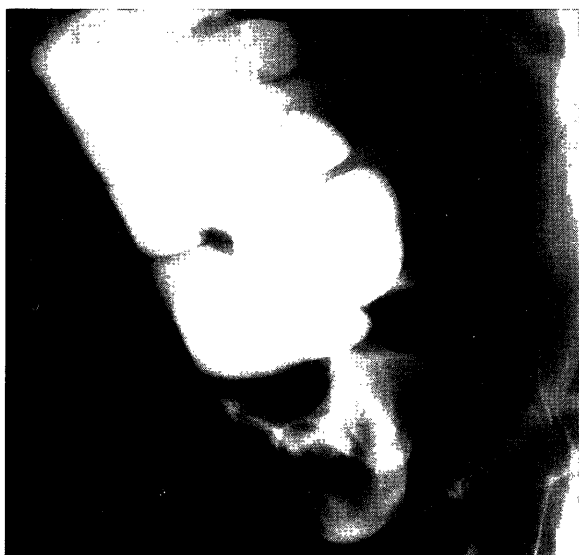


Fig. 4. Barium enema showing a filling defect in the cecum.

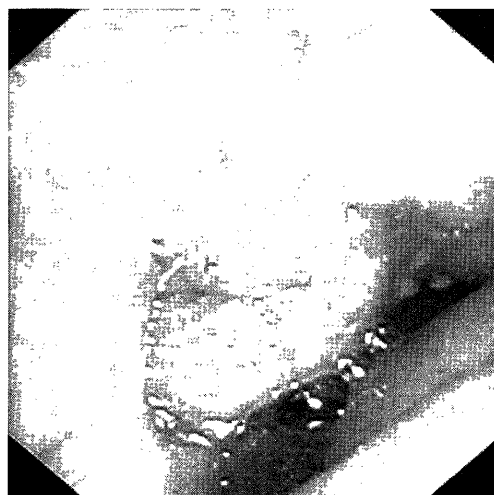


Fig. 5. Colonoscopy showed an edematous and reddish mucosa with no tumor in the cecum.




Fig. 6A



Fig. 6B

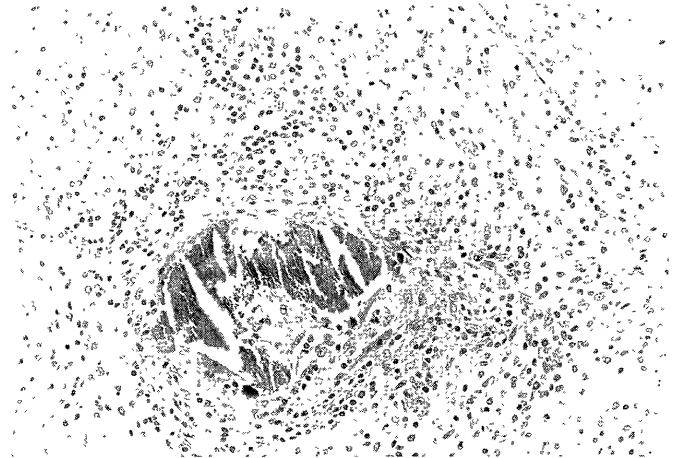


Fig. 6C

Microscopically, the lesion extended through the muscularis propria into the serosa (A) ($\times 10$). The pseudotumor was composed of fibrous stroma and a mixture of chronic inflammatory cells including lymphocytes, plasma cells (B) ($\times 200$), and contained areas of calcification (C) ($\times 200$).

Discussion

Intussusception in adults is almost invariably caused by some preexisting lesions, including benign tumors, such as leiomyoma,^{5,6)} hamartoma,^{7,8)} and neurofibroma,⁹⁾ or malignant neoplasms.¹⁰⁻¹³⁾ Furthermore, trauma,¹⁹⁾ post-operative adhesion,²⁰⁻²¹⁾ Meckel's diverticulum,²⁻²²⁾ and lymphoid hyperplasia²³⁾ are other potential predisposing factors in the production of intussusception.

Inflammatory pseudotumor is not a true neoplasia. It occurs rarely in the small intestine, and a solitary or

polypoid lesion may present clinically as intussusception and bowel obstruction.¹⁵⁻¹⁸⁾ In the small intestine inflammatory pseudotumors are commonly located in the mucosal layer of the ileum.¹⁵⁻¹⁸⁾ In our case, the pseudotumor was located in the muscularis propria and serosa, that are rare sites for this tumor. The true nature of pseudotumor in the present case is obscure. There are several pathoetiologic factors as for inflammatory pseudotumor reported in the literature.¹⁵⁻²¹⁾ Although the microscopic findings were similar to the post-operative change,¹⁹⁻²⁰⁾ he has no history of abdominal operation. Ramsden et al.²⁴⁾ reported a 76-year-old man

with recurrent intussusception associated with vascular proliferation.²⁴⁾ The present case did not have such a vascular change. One of the histologic feature in our case is calcification within the tumor. Entero-colic calcification is probably the most common radiographic manifestation of schistosomal infestation of the gastrointestinal tract.²⁵⁾ Kimura et al.²⁶⁾ reported a patient with a complete invagination of the cecum that contained two large laminated calcified fecaliths. Most of the eggs of the schistosomioma are deposited in the submucosa, whereas serosal calcification is rare.^{25,26)} In the present case, there were no granulomas, fecalis nor pathogens. Subsequently, etiology of the pseudotumor was not determined.

Mesenteric panniculitis is an extremely rare disease in which the adipose tissue is replaced by fibrosis, necrosis, and calcification.²⁷⁾ However, our case did not show any of the features of mesenteric panniculitis.

In conclusion, we have described a rare case of intussusception caused by subserosal inflammatory pseudotumor of the terminal ileum, although the etiology of the lesion remains obscure.

References

- 1) Laws HL, Aldrete JS. Small-bowel obstruction: a review of 465 cases. *South Med J* 69:733-4, 1976
- 2) Gordon RS, O'Dell KB, Namon AJ, Becker LB. Intussusception in the adult; a rare disease. *J Emerg Med* 9:337-42, 1991
- 3) Reijne HA, Joosten HJ, de Boer HH. Diagnosis and treatment of adult intussusception. *Am J Surg* 158:25-8, 1989
- 4) Dharia KM, Marino AW Jr, Mancini HW. Enterocolic intussusception in adults. *Dis Colon Rectum* 15:194-200, 1972
- 5) Mansberg VJ, Mansberg G, Doust BD. Jejunojejunal intussusception secondary to leiomyoma. *Austral Radiol* 40:72-4, 1996
- 6) Gourtsoyiannis NC, Bays D, Malamas M. Radiological appearances of small intestinal leiomyomas. *Clin Radiol* 45:94-103, 1992
- 7) Yamagami T, Tokiwa K, Iwai N. Myoepithelial hamartoma of the ileum causing intussusception in an infant. *Pediatr Surg Intern* 12:206-7, 1997
- 8) Gonzalez J, Marco A, Andujar M et al. Myoepithelial hamartoma of the ileum: a rare cause of intestinal intussusception in children. *Eur J Pediatr Surg* 5:303-4, 1995
- 9) Watanuki F, Ohwada S, Hosomura Y et al. Small ileal neurofibroma causing intussusception in a non-neurofibromatosis patient. *J Gastroenterol* 30:113-6, 1995
- 10) Hurwitz LM, Gerlten SL. Colonoscopic diagnosis of ileocolic intussusception. *Gastroint. Endoscopy* 32:217-8, 1986
- 11) Felix EL, Cohen MH, Bernstein AD, Schwartz JH. Adult intussusception: case report of recurrent intussusception and review of the literature. *Am J Surg* 131:758-61, 1976
- 12) Boyle MJ, Arkell LJ, Williams JT. Ultrasonic diagnosis of adult intussusception. *Am J Gastroenterol* 88:617-8, 1993
- 13) Begos DG, Sandor A, Modlin IM. The diagnosis and management of adult intussusception. *Am J Surg* 173:88-94, 1997
- 14) Azar T, Berger DL. Adult intussusception. *Ann Surg* 226:134-8, 1997
- 15) LiVolsi VA, Perzin KH. Inflammatory pseudotumors (inflammatory fibrous polyps) of the small intestine: A clinicopathologic study. *Am J Dig Dis* 20:325-36, 1975
- 16) Nkanza NK, King M, Hutt MS. Intussusception due to inflammatory fibroid polyps of the ileum: a report of 12 cases from Africa. *Br J Surg* 67:271-4, 1980
- 17) Winkler H, Zelikovski A, Gutman H et al. Inflammatory fibroid polyp of the jejunum causing intussusception. *Am J Gastroenterol* 81:598-601, 1986
- 18) Myint MA, Medeiros LJ, Sulaiman RA et al. Inflammatory pseudotumor of the ileum. A report of a multifocal, transmural lesion with regional lymph node involvement. *Arch Pathol Lab Med* 118:1138-42, 1994
- 19) Komadina R, Smrkolj V. Intussusception after blunt abdominal trauma. *J Trauma* 45:615-6, 1998
- 20) Rozsos I. Ileal intussusception, caused by fibroma, after cholecystectomy performed under microlaparotomy. *Orvosi Hetilap* 135:1645-7, 1994
- 21) Mordkin R, Gibbons MD, Cain MP. Ileal-ileal intussusception: an unusual complication following enterocystoplasty. *Urology* 47:138-9, 1996
- 22) Daneman A, Myers M, Shuckett B, et al. Sonographic appearances of inverted Meckel diverticulum with intussusception. *Pediatr Radiol* 27:295-8, 1997
- 23) Pang LC. Intussusception revisited: clinicopathologic analysis of 261 cases, with emphasis on pathogenesis. *South Med J* 82:215-28, 1989
- 24) Ramsden KL, Newman J, Moran A. Florid vascular proliferation in repeated intussusception mimicking primary angiomatous lesion. *J Clin Pathol* 46:91-2, 1993
- 25) Fataar S, Bassiony H, Hamed MS et al. Radiographic spectrum of rectocolonic calcification from schistosomiasis. *Am J Roentgenol* 142:933-6, 1984
- 26) Kimura H, Satou T, Takahashi N et al. Intussusception of the cecum with calcified fecaliths. *Am J Gastroenterol* 90:318-9, 1995
- 27) Wexner SD, Attiyeh FF. Mesenteric panniculitis of the sigmoid colon. Report of two cases. *Dis Colon Rectum* 30:812-5, 1987