

— Case Report —

## Progressive Retrograde Acute Coronary Occlusion after Gianturco-Roubin Stenting

Noriyuki KOSE<sup>1)</sup>, Hideki FUJIWARA<sup>1)</sup>, Yoshiyuki MIYAHARA<sup>2)</sup>, Shigeru KOHNO<sup>2)</sup>

1) Division of Cardiology, Ebisumachi Hospital

2) Second Department of Internal Medicine, Nagasaki University School of Medicine

We report a case of progressive retrograde acute coronary occlusion after Gianturco-Roubin (GR) stenting in a patient with two vessel diseases. A GR stent was implanted in the proximal part of the left anterior descending artery (LAD) because of suboptimal results of percutaneous transluminal coronary angioplasty (PTCA). More than 90% stenosis occurred in the non-stented region just distal to the edge of the GR stent. Another stenosis ensued mid-stent after PTCA was performed for that lesion. Acute occlusion from the mid-LAD to the main trunk progressed immediately after PTCA for the LAD. The patient died of cardiogenic shock despite repeated bail-out PTCA procedures for both the main trunk and the proximal LAD. Acute retrograde occlusion might be caused by in-stent thrombosis, or acute recoil of GR stent associated with insufficient stent dilatation and acute coronary arterial elastic recoil.

---

**Key words:** GR stent; recoil; acute retrograde occlusion

### Introduction

Recently, intracoronary stenting has become a commonly used treatment for suboptimal result or bail-out of acute or threatened coronary occlusion during angioplasty, for late restenosis after angioplasty and for saphenous vein graft lesions<sup>1,2,3)</sup>. Moreover, primary stenting for acute myocardial infarction has attracted much attention because stenting may suppress elastic recoil better than PTCA alone and may prevent reocclusion after recanalization<sup>4)</sup>. Therefore, stenting has become an extremely effective treatment for suboptimal results or for bail-out after PTCA in patients with acute myocardial

infarction, as well as for acute or threatened occlusion or for any suboptimal angiographic result after elective PTCA. However, the problem of acute or subacute thrombotic occlusion after stenting remains, despite anticoagulation and antiplatelet therapy<sup>5,6)</sup>. We herein present a case of acute retrograde coronary occlusion after urgent Gianturco-Roubin (GR) stenting of the left anterior descending artery (LAD) in a patient with unstable angina.

### Case Report

A 78-year-old man with diabetes mellitus, cerebral infarction and a past history of angina attack noticed chest pain that was alleviated by nitroglycerin a week before. He presented to the emergency room because of frequent chest pain for the preceding two days. On admission, he was hemodynamically stable with no features indicating left or right heart failure. Electrocardiogram (ECG) showed QS in leads V<sub>1</sub>, rS in V<sub>2</sub>, slight ST elevation in V<sub>1</sub> to V<sub>2</sub> and negative T in V<sub>1</sub> to V<sub>5</sub>. Echocardiogram revealed akinesis of the apex with 40% ejection fraction. Laboratory data were as follows: white blood cell count was 8000/uL; Hgb 14.7g/dl; platelet 30.1x 10<sup>4</sup>/μL; GOT 24 IU/L; LDH 418 IU/L and CPK 154 IU/L.

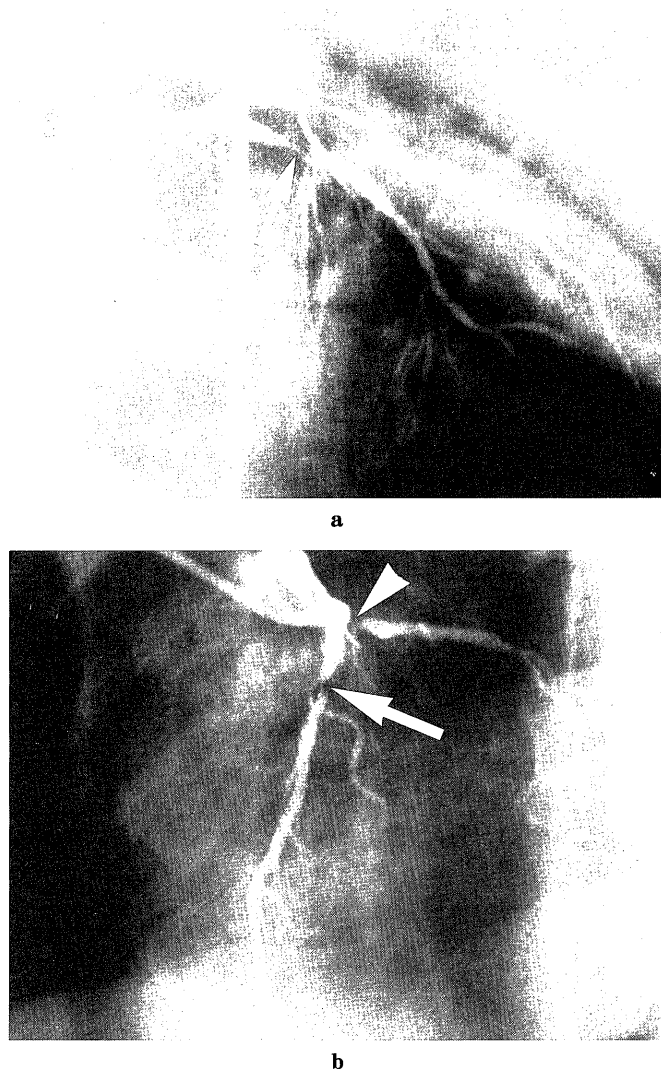
Urgent coronary angiogram revealed 99% stenosis with delayed filling of segment 6 of the left anterior descending artery (LAD) and 90% stenosis of segment 11 of the left circumflex artery (LCX) (Fig. 1-a,b). Right coronary artery (RCA) revealed neither stenosis nor collaterals in either LAD or LCX. We proceeded with PTCA to the LAD with a bolus shot of 5000 units of heparin and intravenous injection of low molecular dextran. A britetip 8F-JL4 guide catheter (J.J. Cordis, USA), 0.014-inch Reflex Super-soft guidewire (J.J. Cordis, USA) and a 3.0 x 20mm Trakstar balloon catheter (J.J. Cordis, USA) were used. The guidewire and balloon

---

### Address Correspondence:

Noriyuki Kose, M.D.

Division of Cardiology, Ebisumachi Hospital  
3-4 Ebisumachi, Nagasaki 850-0056, Japan



**Fig. 1.** Urgent coronary angiogram on admission  
**a:** Segment 6 of LAD shows 99% stenosis with delayed filling (arrow): RAO view  
**b:** Segment 6 of LAD shows 99% stenosis (arrow), and segment 11 of Cx shows 90% stenosis (arrowhead): LAO view  
 RAO: right anterior oblique  
 LAO: left anterior oblique  
 LAD: left anterior descending artery  
 Cx : left circumflex artery

catheter easily crossed the stenotic lesion of the LAD. Although dilatation was carried out at 8 atmospheres for 20 seconds, then at 10 atmospheres for 1 minute (Fig. 2-a), 50% of residual stenosis remained (Fig. 2-b). We placed a GR-stent on segment 6 of LAD at 5 to 8 atmospheres for 1 minute and post-dilatation ensued at 10 atmospheres for 1 minute (Fig. 2-c). Immediately after that, more than 90% stenosis occurred at the non-stented region just distal to the edge of the stent (Fig. 2-d), and the site was subsequently dilated (Fig. 2-e). However, 75 to 90% stenosis occurred immediately mid-GR stent (Fig. 2-f), and PTCA was performed on

that lesion (Fig. 2-g). Furthermore, acute retrograde occlusion extended from the mid-stent to the left main trunk (Fig. 2-h). There was no restoration of flow, despite repeated PTCA procedures for the proximal LAD and the main trunk. Ventricular tachycardia, hypotension and respiratory arrest due to cardiogenic shock occurred, leaving no time for inserting intraaortic balloon pumping or transferring to bypass grafting. The patient died two hours later.

## Discussion

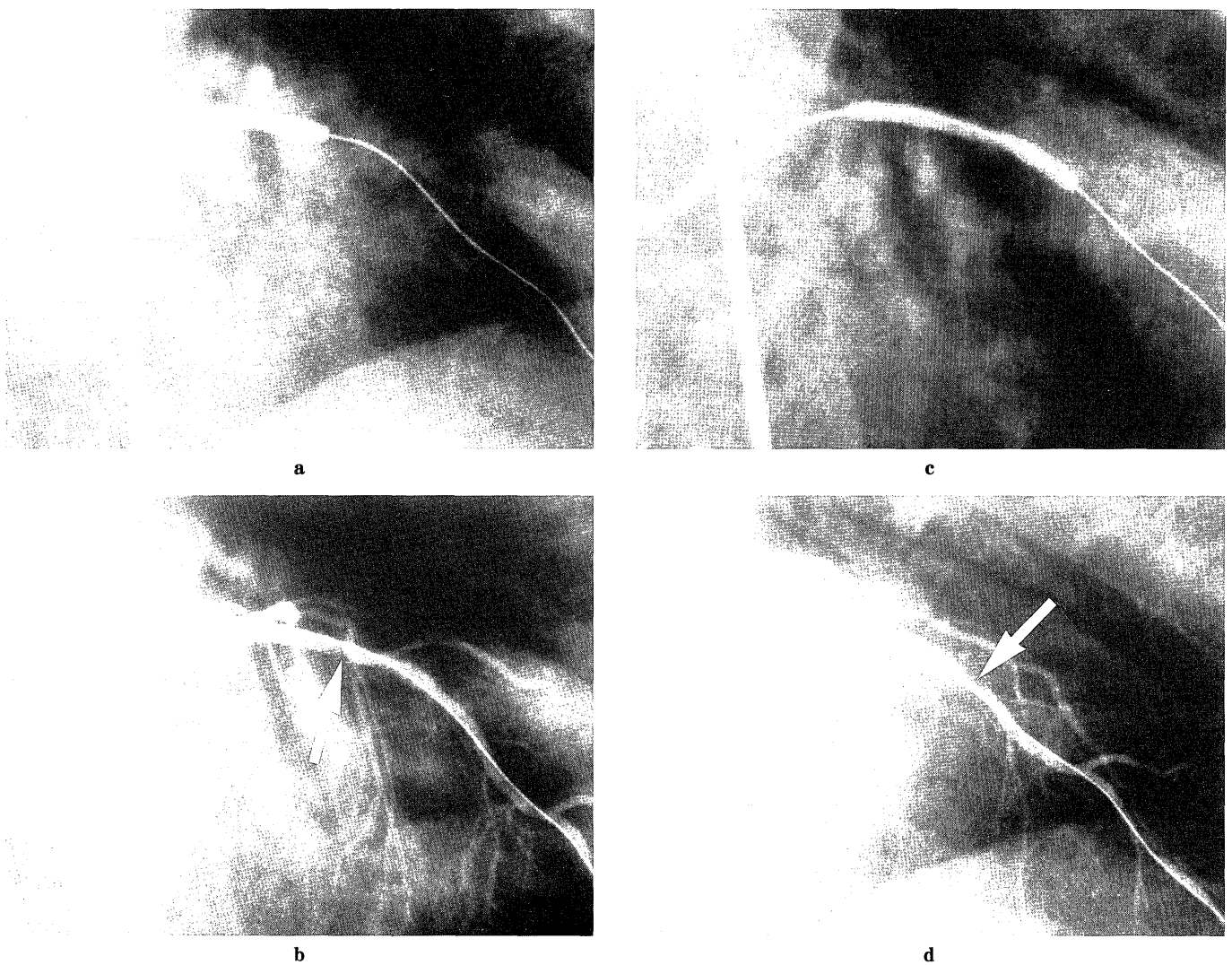
Some controversy exists on the appropriate therapeutic strategy for double- or triple-vessel coronary artery disease in patients with unstable angina. Urgent CABG (U-CABG) or direct PTCA with bail-out stenting is often the treatment of choice in this case. We decided to carry out direct PTCA and stenting for the LAD stenosis because of the patient's advanced age and the family's refusal of CABG. On the data after U-CABG for failed angioplasty, the incidence of QMI ranges from 11% to 61%<sup>7,8</sup>, and of the death ranging 0% to 12% or higher<sup>9,10</sup>. Direct U-CABG without both PTCA and stenting might be preferable in our case. However, we could not insert IABP promptly and did not have surgical standby for PTCA. It is premature, however, to endorse surgical standby for PTCA and the performance of PTCA without on-site access to cardiovascular surgery.

While thrombus, elastic recoil and coronary dissection are enumerative causes of acute occlusion after PTCA, coronary dissection is cardinal among them<sup>11,12</sup>. Severe coronary dissection after PTCA, including death, lethal myocardial infarction, U-CABG and >50% stenosis occurs in 2.7 to 3.6% cases<sup>13,14,15</sup>. Rare cases of aorto-coronary dissection have also been reported<sup>16,17,18</sup>. On the other hand, the incidence of acute occlusion of stented segments caused by thrombus is 3.1% at a mean of 3.9 days<sup>12</sup>. Multivariate analysis showed that three factors increase the likelihood of acute stent thrombosis with this device: a stent < 3mm in diameter, a residual filling defect or a residual dissection after stent deployment<sup>19</sup>. Among 78 GR stented cases, no cases of acute occlusion occurred within 24 hours, but three cases of subacute thrombosis occurred<sup>11</sup>. Subacute thrombosis occurred at rate of 3.8% in GR stent, 7% in Palmaz-Schaz stent and 15% in Strecker stent<sup>20</sup>. Despite successful PTCA, stenting and post-dilatation procedures in our case, immediate stenosis occurred just distal to the edge of the GR stent, and retrograde acute occlusion extended from mid-GR stent to the main trunk. Acute elastic recoil or dissection might have occurred just distal to the edge of the GR stent. Although the exact reason for acute

occlusion is unknown, there is a possibility that acute in-stent thrombosis induced acute retrograde occlusion in association with residual stenosis or residual dissection mid-GR stent. However, we could not detect in-stent thrombus angiographically. Other possible reasons for acute retrograde occlusion are that acute recoil of the GR stent from mid-GR stent to main trunk progressed in association with insufficient stent dilatation and acute coronary arterial elastic recoil. Acute recoil of GR stent may be due to the specific character of GR stent, which recoils more than PS stent does. We could not dilate the LAD and the main trunk sufficiently, despite repeated bail-out PTCA procedures for the lesions. Although an-

other bail-out stent implantation with insertion of IABP would have been the treatment of choice in this setting, we could not perform this procedures, since there was no hope of recovery due to instantaneous cardiogenic shock.

The decision to perform U-CABG or PTCA alone or with bail-out stent should be made carefully when managing complicated lesions. Caution should be exercised in selecting the appropriate patients and referring them to the correct institutions. Furthermore, careful examination using IVUS (intravascular ultrasound) before and after angioplasty will have a great impact on the choice of therapeutic strategy.



**Fig. 2.** PTCA and GR stenting for LAD.

**a:** PTCA for LAD is performed.

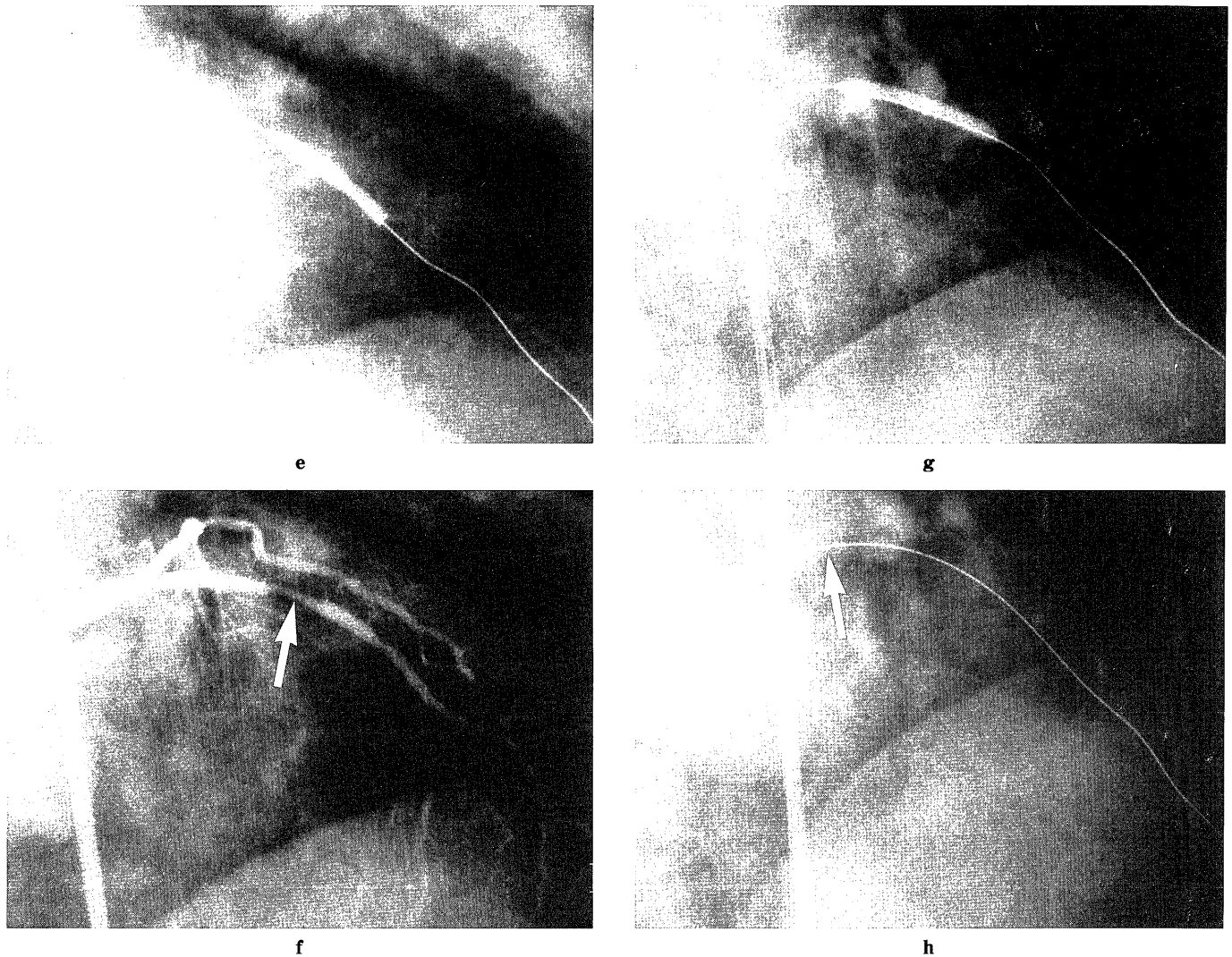
**b:** Mid-LAD shows 50% stenosis after PTCA (arrow).

**c:** GR stent is deployed in LAD.

**d:** Immediately after placing stent, more than 90% stenosis occurs at the non-stented region just distal to the edge of the GR stent (arrow).

PTCA: percutaneous transluminal coronary angioplasty

GR : Gianturco-Roubin



**Fig. 2.** PTCA and GR stenting for LAD.

**e:** The stenotic lesion is dilated promptly.

**f:** The middle part of the GR stent shows 75 to 90% stenosis immediately after PTCA (arrow).

**g:** The stenotic lesion at mid-GR stent is dilated.

**h:** Acute retrograde coronary occlusion extends from LAD to the main trunk (arrow).

PTCA: percutaneous transluminal coronary angioplasty

GR : Gianturco-Roubin

## References

- 1) Alfonso F, Hernandez R, Goicolea J, Segovia J, Perez Vizcayno MJ, Banuelos C, Silva JC, Zarco P, Macaya C. Coronary stenting for acute coronary dissection after coronary angioplasty: Implication of residual dissection. *J Am Coll Cardiol* 24:989-995, 1994. *J Am Coll Cardiol* 27:757-765, 1996.
- 2) Roubin GS, Cannon AD, Agrawal SK, Macander PJ, Dean LS, Baxley WA, Breland J. Intracoronary stenting for acute and threatened closure complicating percutaneous transluminal coronary angioplasty. *Circulation* 85:916-919, 1992.
- 3) Eeckhout E, Kappenberger L, Goy JJ. Stents for intracoronary placement: Current status and future directions. *J Am Coll Cardiol* 27:757-765, 1996.
- 4) Saitoh S, Hosokawa G, Kim K, Tanaka S, Miyake S. Primary stent implantation without coumadin in acute myocardial infarction. *J Am Coll Cardiol* 28:74-81, 1996.
- 5) Takeda H, Usuba F, Satoh C, Nakata A, Kunoh M, Yamamoto N, Aizawa O, Mochizuki S. Recurrent coronary thrombus after implanting a coronary stent for acute myocardial infarction: A case report. *Jpn J Cardiol* 12:549-555, 1997.
- 6) Kagoshima M, Miyashita Y, Abe K, Takei K, Shinohara M, Furusawa T, Owa M. Subacute stent thrombosis precipitated by disseminated intravascular coagulopathy complicating endotoxic shock: A case report. *Jpn J Cardiol* 13:73-79, 1998.
- 7) Reul GJ, Cooley DA, Hallman GL, et al. Coronary artery bypass for unsuccessful percutaneous transluminal coronary angioplasty. *J Thorac Cardiovasc Surg* 88:865-894, 1984.
- 8) Haraphongs, EM, Na-ayudha KR, Burton J, et al. Clinical efficacy of emergency bypass surgery for failed coronary angioplasty. *Can J Cardiol* 6:186-190, 1990.
- 9) Cowley MK, Dorros G, Kelsy SF, Van Raden M, Detre KM. Emergency coronary bypass surgery after coronary angioplasty: the National Heart, Lung, and Blood Institute's Percutaneous Transluminal Coronary Angioplasty Registry experience. *Am J Cardiol* 53:23c-6c, 1984.

- 10) Parsonnet V, Fisch D, Gielchinsky I, et. al. Emergency operation after failed angioplasty. *J Thorac Cardiovasc Surg* 96:198-203, 1988.
- 11) Yokoi H, Shimada K, Kimura T, Nosaka H, Yakoi H, Hamasaki N, Abe M, Nakagawa Y, Tamura T, Kaburagi S, Shinoda E, Sato Y, Sakai H, Sawada Y, Nakano Y, Iwatate M, Kadena M, Kurasaki U, Ito K, Kawaharada T, Nobuyoshi M. Initial and Follow-Up Outcome of Gianturco-Roubin Coronary Stent. *Jpn J Interv Cardiol* 9:641-650, 1994.
- 12) Dean LS, Geroge CJ, Roubin GS, Kennard ED, Holmes DR, King III SB, Vliestra RE, Moses JW, Kereiakes D, Carrozza JP, Ellis SG, Margolis JR, Detre KM. Bailout and Corrective use of Gianturco-Roubin Flex Stents After Percutaneous Transluminal Coronary Angioplasty. Operator Reports and Angiographic Core Laboratory Verification From the National Heart, Lung, and Blood Institute / New Approaches to Coronary Intervention Registry. *J Am Coll Cardiol* 29:934-940, 1997.
- 13) Sharma SK, Israel DH, Kamean JL, Bodian CA, Ambrose JA. Clinical, angiographic, and procedural determinants of major and minor coronary dissection during angioplasty. *Am Heart J* 126:39-47, 1993.
- 14) Dorros G, Cowley MJ, Simpson J, Bentivoglio LG, Block PC, Bourassa M, Detre K, Gosselin AJ, Gruentzig AR, Kelsey SF, Kent KM, Mock MB, Mullin SM, Myler RK, Passamani ER, Stertz SH, Williams DO. Percutaneous transluminal coronary angioplasty: Report of complications from the National Heart, Lung, and Blood Institute PTCA registry. *Circulation* 67: 723-730, 1983.
- 15) Cripps TR, Cowley MJ, Simpson J, Bentivoglio LG, Block PC, Bourassa M, Detre K, Gosselin AJ, Gruentzig AR, Kelsey SF, Kent KM, Mock MB, Mullin SM, Myler RK, Passamani ER, Stertz SH, Williams DO. Outcome of extensive coronary artery dissection during coronary angioplasty. *Br Heart J* 66:3-6, 1991.
- 16) Geraci AR, Krishnaswami V, Selman MW: Aortocoronary dissection complicating coronary arteriography. *J Thorac Cardiovasc Surg* 65: 695-698, 1973.
- 17) Asai K, Takayama M, Someya T, Ochi M, Sakai S, Suzuki I, Sakurai K, Uemura R, Ohba Takayoshi, Takagi Gen, Kunimi T, Hoshino K, Setta K, Tomita Y, Kusama Y, Nejima J, Munakata K, Takano T, Tanaka, S. Coronary artery and ascending aorta dissection induced by PTCA successfully managed by emergency CABG and ascending aorta graft replacement. *Jpn J Interv Cardiol* 10:433-438, 1995.
- 18) Oshima A, Ochiai M, Nishiyama Y, Takeshita S, Isshiki T, Sato T, Miyashita H. A case of presumably retrograde late extension of dissection from the left anterior descending artery into the left main trunk and circumflex arteries following bail-out Palmaz-Schatz stent implantation. *Jpn J Interv Cardiol* 11:79-84, 1996
- 19) Liu MW, Agrawal SK, Cannon AD. Is coronary stenting for acute or threatened closure a temporary bail-out device or definitive therapy. *J Am Coll Cardiol* 21 Suppl: 177A, 1993.
- 20) Iwabuchi M, Kimura T, Nobuyoshi M. In-hospital outcome and long-term follow-up of emergency coronary stenting: Comparison of three different types of stent. *Circulation* 88 (Suppl I); 123, 1993.